



PATIENT

Max Diaco

SPECIES

Canine

BREED

Golden Retriever

SEX

Neutered Male

AGE

11 Years

WEIGHT

102 Pounds

PRESENTING CLINICAL SIGNS

History: Cardiac workup, ECG to antech and frequent VPC's were found.

Abnormal PE/Chem/CBC/UA Results: Chol 342, Trig 406, PSL 142, T4 0.5

ULTRASONOGRAPHIC EXAMINATION OF THE HEART

CANINE CARDIAC PARAMETERS	MR VMAX (m/s)	TR VMAX (m/s)	LA/AO (Boon method)	LA/AO (Heart Base; Swe)	FS (%)	EF (%)	EPSS (cm)
NORMAL PARAMETER	4.5-5.5	<2.7	1.3	<1.6	28-40	40-100	<0.6
PATIENT	--	--	1.15		38	68	0.35
CANINE CARDIAC PARAMETERS	HR (BPM)	AV VMAX (m/s)	PV MAX (m/s)	BODY WEIGHT (kg)	LA 2D short axis Base view (cm)	LVIDd Avg; 2D and m-mode short axis (cm)	LVIDs Avg; 2D and m-mode short axis (cm)
NORMAL PARAMETER	50-100	0.7-1.7	0.7-1.6				
PATIENT	99	--	1.30	--	--	4.71	--

INTERPRETED BY

Eric Lindquist, DMV DABVP, Cert. IVUSS

IMAGING PERFORMED BY

Shari Reffi, CVT

HOSPITAL NAME

Dr. Brenda King Vet

REFERRING VET

Dr. King

INVOICE

13398

DATE

10/1/21

Cardiac Presentation

The cardiac presentation in this patient revealed a 4.3 cm x 3.5 cm right auricular/right ventricular junctional mass with a large amount of pericardial effusion and tamponade effect with collapse of the right auricle. Left atrial and left ventricular volumes were normal. Persistent arrhythmia present.

ULTRASONOGRAPHIC FINDINGS

- Right auricular mass with pericardial effusion consistent with hemangiosarcoma
- Tamponade effect

INTERPRETATION OF THE FINDINGS & FURTHER RECOMMENDATIONS

Palliative pericardial pericardiocentesis could be considered with immediate chemotherapeutic intervention and doxorubicin. Prognosis long term is poor.



PATIENT

Max Diaco

SPECIES

Canine

BREED

Golden Retriever

SEX

Neutered Male

AGE

11 Years

WEIGHT

102 Pounds

INTERPRETED BY

Eric Lindquist, DMV
DABVP, Cert. IVUSS

IMAGING PERFORMED BY

Shari Reffi, CVT

HOSPITAL NAME

Dr. Brenda King Vet

REFERRING VET

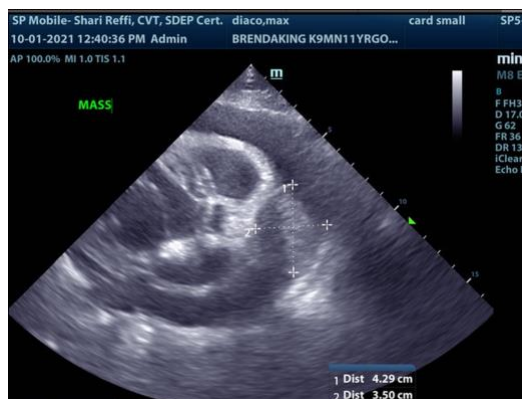
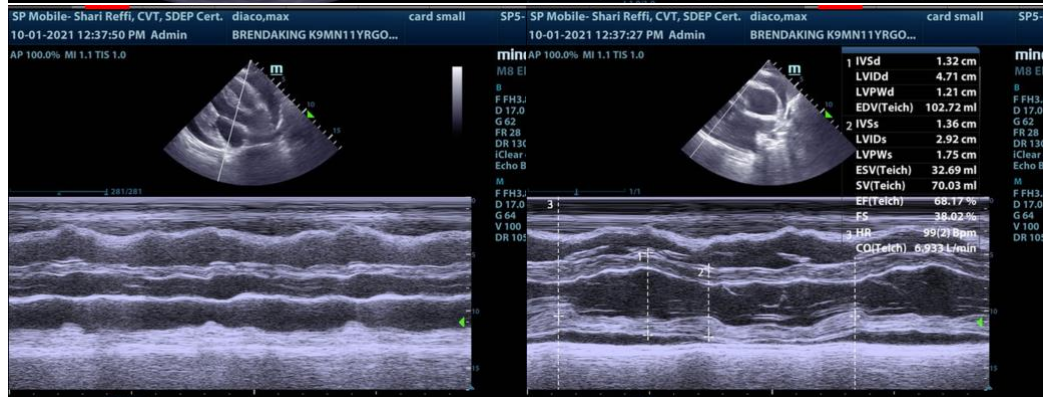
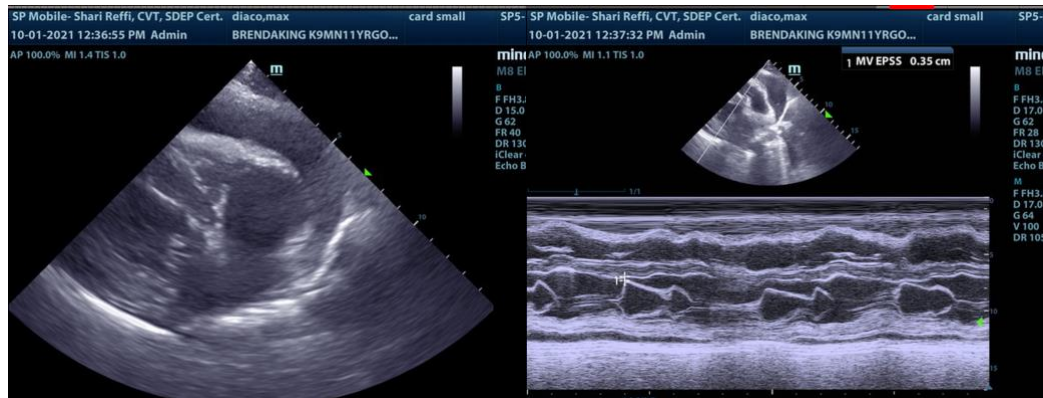
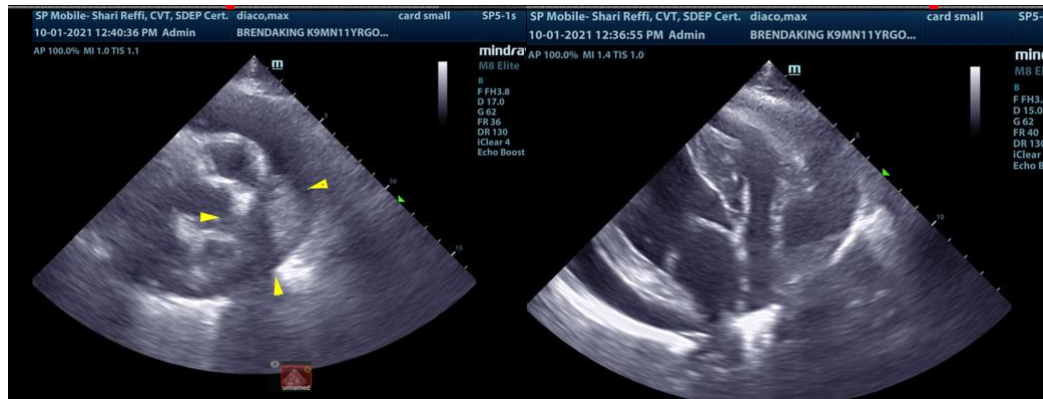
Dr. King

INVOICE

13398

DATE

10/1/21





PATIENT

Max Diaco

The information and recommendations provided are based on the images presented by the referring veterinarian. No evaluation can be communicated regarding pathology that was not visible in the image/video clips provided.

SPECIES

Canine

Thank you for this referral. If the clinical or image interpretation does not parallel your findings or if I can be of any further assistance please contact me.

Eric Lindquist, DMV, DABVP, Cert. IVUSS, CEO of SonoPath.com

info@SonoPath.com

BREED

Golden Retriever

Pericardial Effusion and Cardiac Neoplasia

SEX

Neutered Male

<http://www.sonopath.com/CardiacNeoplasiaEffusion>

AGE

11 Years

Description: The pericardium is a fibrous sac that encloses the heart and the great vessels—aorta, pulmonary artery, proximal pulmonary veins, and vena cava—located at the heart's base. It is attached caudally to the diaphragm and under normal circumstances contains 1-15 mL of fluid. The latter is comprised of phospholipids that lubricate the heart and allow it to expand and contract without generating friction. The pericardium also fixes the heart, prevents excess motion, and links the diastolic distensibility of the ventricles, thus limiting the degree to which either the left or the right ventricle will distend during diastole. When there are acute changes in venous return (i.e., during exercise), the pericardium plays a critical role in limiting ventricular filling. In cases of chronic cardiac enlargement, the pericardium also becomes distended, and its ability to limit ventricular filling, especially when the heart is at rest, becomes compromised. Pericardial tamponade occurs when there is a rapid accumulation of fluid and the pressure inside the pericardium increases significantly. With tamponade, ventricular filling is restricted and cardiac output is decreased. The right atrium and ventricle are the most vulnerable to this condition as these compartments have thinner walls and a lower pressure.

WEIGHT

102 Pounds

INTERPRETED BY

Eric Lindquist, DMV
DABVP, Cert. IVUSS

IMAGING PERFORMED BY

Shari Reffi, CVT

HOSPITAL NAME

Dr. Brenda King Vet

REFERRING VET

Dr. King

Etiology: Causes of pericardial effusion include:

- Neoplasia
 - Right atrial (RA) hemangiosarcoma
 - Heart base (aortic body) tumors
 - Mesothelioma
 - Rhabdomyosarcoma
 - Ectopic thyroid carcinoma
 - Metastatic neoplasia
- Idiopathic
- Congestive heart failure
- Peritoneal-pericardial diaphragmatic hernia
- Pericardial cyst
- Hypoalbuminemia
- Infectious pericarditis (bacterial, *Coccidioides immitus*)

INVOICE

13398

DATE

10/1/21



PATIENT

Max Diaco

- Feline infectious peritonitis
- Left atrial tear secondary to valvular disease
- Coagulopathy

SPECIES

Canine

BREED

Golden Retriever

SEX

Neutered Male

AGE

11 Years

WEIGHT

102 Pounds

The majority of neoplastic masses consist of hemangiosarcoma and heart-based tumors (chemodectomas or ectopic thyroid adenocarcinoma). Idiopathic pericardial effusion is a diagnosis of exclusion; the effusion is typically hemorrhagic. Approximately 50% of dogs will be cured with a single pericardiocentesis, while some dogs will require multiple pericardiocenteses as well as surgery. A peritoneal-pericardial diaphragmatic hernia is a congenital hernia seen in dogs and cats in which the abdominal contents (i.e., liver, small intestine, spleen, stomach) herniate into the pericardial sac. Constrictive pericarditis is an uncommon condition in which a non-distensible, thickened, fibrotic pericardium develops over time.

Clinical Signs: One will observe the following clinical signs, which often present in combination: ascites, lethargy, exercise intolerance, pale mucous membranes, weak pulses, *pulsus paradoxus*, and respiratory distress.

Diagnostics: Survey radiographs will reveal hepatomegaly, cardiomegaly (generalized or sectorial globoid), and small pulmonary vessels. Pulmonary edema is typically not found, although one may discover concurrent pulmonary metastatic disease. An ECG will show electrical alternans or small complexes, but often the changes are very subtle and difficult to detect.

INTERPRETED BY

Eric Lindquist, DMV
DABVP, Cert. IVUSS

Echocardiography is usually considered the gold standard for diagnosing pericardial effusion. Findings include:

IMAGING PERFORMED BY

Shari Reffi, CVT

- Anechoic space between the heart and the pericardium.
- Abnormal side-to-side cardiac motion.
- Decreased chamber size (right ventricle [RV] and left ventricle [LV]).
- Presence of a pericardial or cardiac mass.
- Tamponade with early diastolic RA and RV collapse.

HOSPITAL NAME

Dr. Brenda King Vet

REFERRING VET

Dr. King

Cytology is helpful in the diagnosis of lymphoma, septic pericarditis, and idiopathic effusion, but not in cases of neoplasia.

INVOICE

13398

According to a study that found troponin I levels to be higher in dogs with neoplastic pericardial effusion, the cardiac troponin I assay can be helpful in the diagnosis hemangiosarcoma.

DATE

10/1/21

Prognosis:



PATIENT

Max Diaco

- Cardiac hemangiosarcoma: < 8 months with surgical debulking and chemotherapy.
- Chemodectoma (aortic derived): MST 730 days post pericardectomy.
- Idiopathic: 50% complete resolution post cardiocentesis; curative with pericardectomy, which can be done via thoracotomy, or thoracoscopy, or using a balloon to tear the pericardium.
- Mesothelioma: Poor.
- Restrictive pericarditis: Poor, especially when the pericardium has not been surgical stripped.

SPECIES

Canine

BREED

Golden Retriever

SEX

Neutered Male

AGE

11 Years

WEIGHT

102 Pounds

INTERPRETED BY

Eric Lindquist, DMV
DABVP, Cert. IVUSS

IMAGING PERFORMED BY

Shari Reffi, CVT

HOSPITAL NAME

Dr. Brenda King Vet

REFERRING VET

Dr. King

INVOICE

13398

DATE

10/1/21

References:

Cagle LA, Epstein SE, Owens SD, et al. Diagnostic yield of cytology analysis of pericardial effusion in dogs. *J Vet Int Med* 2014;28:66-71.

Feigenbaum H. Pericardial disease. In: Feigenbaum H, ed. *Echocardiography, 5th ed.* Philadelphia, PA: Lippincott, Williams & Wilkins; 1994:556-588.

Jackson J, Richter KP, Launer DP. Thoroscopic partial pericardectomy in 13 dogs. *J Vet Int Med* 1999;13:529-33.

Johnson MS, Martin M, Binns S. A retrospective study of clinical findings, treatment and outcome in 143 dogs with pericardial effusion. *J Small Anim Prac* 2004;45:546-52.

Kienle RD, Thomas WP. Echocardiography. In: Nyland TG and Mattoon JS, eds. *Small Animal Diagnostic Ultrasound, 2nd ed.* Philadelphia, PA: WB Saunders; 2000:354-423.

Miller MW, Sisson DD. Pericardial disorders. In: Ettinger SJ and Feldman EC, eds. *Textbook of Veterinary Internal Medicine, 5th ed.* Philadelphia, PA: WB Saunders; 2000:923-36.

Rajagopalan V, Jesty SA, Craig LE, et al. Comparison of presumptive echocardiographic and definitive diagnoses of cardiac tumors in dogs. *J Vet Int Med* 2013;27:1092-96.

Shaw SP, Rozanski EA, Ruhs JE. Cardiac troponins I and T in dogs with pericardial effusion. *J Vet Int Med* 2004;18:322-24.

Sidley JA, Atkins CE, Keene BW, et al. Percutaneous balloon pericardiotomy as a treatment for recurrent pericardial effusion in 6 dogs. *J Vet Intern Med* 2002;16:541.



PATIENT

Max Diaco

Sisson D, Thomas WP. Pericardial disease and cardiac tumors. In: Fox PR, Sisson D, Moise NS, eds. *Textbook of Canine and Feline Cardiology*, 2nd ed. Philadelphia, PA: WB Saunders; 1999:679-701.

SPECIES

Canine

Sisson D, Thomas WP, Reed J, et al. Intrapericardial cysts in the dog. *J Vet Int Med* 1993;7:364-69.

BREED

Golden Retriever

SEX

Neutered Male

AGE

11 Years

WEIGHT

102 Pounds

INTERPRETED BY

Eric Lindquist, DMV
DABVP, Cert. IVUSS

**IMAGING
PERFORMED BY**

Shari Reffi, CVT

HOSPITAL NAME

Dr. Brenda King Vet

REFERRING VET

Dr. King

INVOICE

13398

DATE

10/1/21