

**PATIENT PRESENTING CLINICAL SIGNS**

John Westgate Presented for stranguria 8/5/21, producing small amounts of urine. Eating normally. No V/D. No hematuria noted. No medication. Was sent home with Clavamox, Onsiar, Gabapentin on date of exam. Study limited to urinary system.

**SPECIES**

Feline

**LIMITED ULTRASONOGRAPHIC EXAMINATION**

The **urinary bladder**, trigone, and pelvic urethra presented normal thicknesses and normal tone. The ureters were not visible which is normal. No uroliths or sediment were visualized and anechoic urine was present. No evidence of inflammatory or neoplastic changes were noted. Ureteral papillae were normal. The pelvic urethra was imaged 3.0 cm beyond the cystourethral junction.

**BREED**

DSH

**SEX**

Neutered Male

The **kidneys** revealed normal size and structure, corticomedullary definition and ratio for this age. The cortices presented largely uniform texture with normal echogenic relationship to liver and spleen. Medullary structure differed distinctly from the cortex and no evidence of pelvic dilation was present. The capsules were acceptably uniform without significant irregularities. The left kidney measured 3.91 cm. The right kidney measured 3.85 cm.

**AGE**

3 Years

**ULTRASONOGRAPHIC FINDINGS**

- Structurally unremarkable urinary tract

**WEIGHT**

11 Pounds

**INTERPRETATION OF THE FINDINGS & FURTHER RECOMMENDATIONS**

Environmental factors may be playing a role in this patient if no evidence of UTI present on urinalysis.

**INTERPRETED BY**

Eric Lindquist, DMV, DABVP, Cert. IVUSS

**IMAGING BY**

Pamela Harrigan, RDCS

**HOSPITAL NAME**

Anchor AH

**REFERRING VET**

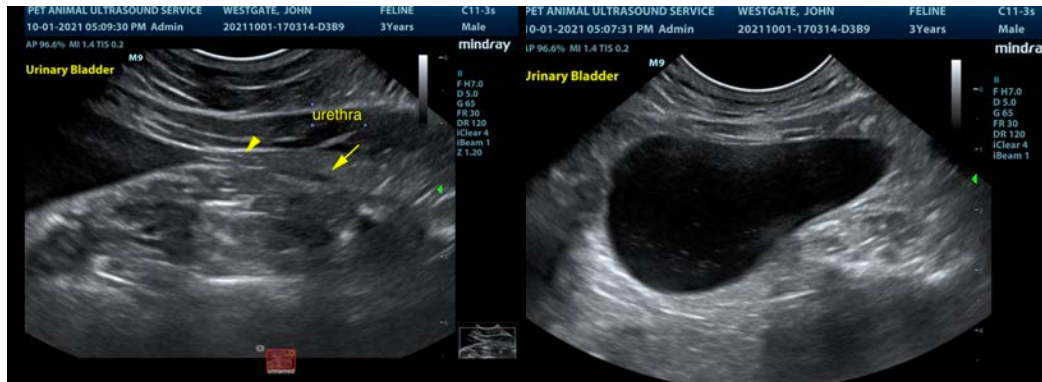
Dr. Els Yeung

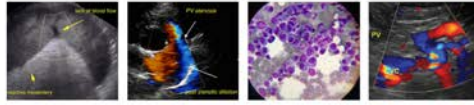
**INVOICE**

26032

**DATE**

10/1/21





**PATIENT**

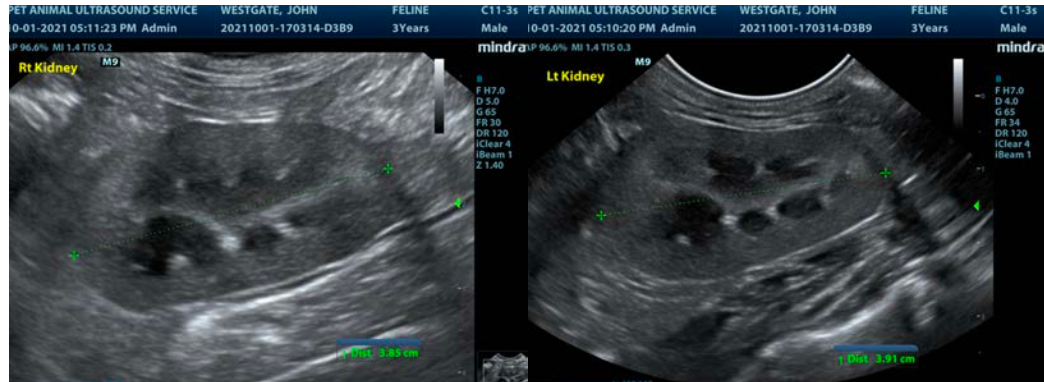
John Westgate

**SPECIES**

Feline

**BREED**

DSH



**SEX**

Neutered Male

The information and recommendations provided are based on the images presented by the referring veterinarian. No evaluation can be communicated regarding pathology that was not visible in the image/video clips provided.

**AGE**

3 Years

Thank you for this referral. If the clinical or image interpretation does not parallel your findings or if I can be of any further assistance please contact me.

**WEIGHT**

11 Pounds

**Eric Lindquist**, DMV, DABVP, Cert. IVUSS, CEO of SonoPath.com  
 info@SonoPath.com

**INTERPRETED BY**

Eric Lindquist, DMV,  
 DABVP, Cert. IVUSS

**IMAGING BY**

Pamela Harrigan, RDCS

**HOSPITAL NAME**

Anchor AH

**REFERRING VET**

Dr. Els Yeung

**INVOICE**

26032

**DATE**

10/1/21