



PATIENT

Ginger Fraile

SPECIES

Canine

BREED

Terrier Mix

SEX

Spayed Female

AGE

10 Years 1 Month

WEIGHT

15.8 Pounds

PRESENTING CLINICAL SIGNS

History: Cardiac Dz. (grade III/VI murmur noted) Current meds: Joint supplements.

Abnormal PE/Chem/CBC/UA Results:

ULTRASONOGRAPHIC EXAMINATION OF THE HEART

CANINE CARDIAC PARAMETERS	MR VMAX (m/s)	TR VMAX (m/s)	LA/AO (Boon method)	LA/AO (Heart Base; Swe)	FS (%)	EF (%)	EPSS (cm)
NORMAL PARAMETER	4.5-5.5	<2.7	1.3	<1.6	28-40	40-100	<0.6
PATIENT	5.24	--	1.3	1.33	39	72	NM
CANINE CARDIAC PARAMETERS	HR (BPM)	AV VMAX (m/s)	PV MAX (m/s)	BODY WEIGHT (kg)	LA 2D short axis Base view (cm)	LVIDd Avg; 2D and m-mode short axis (cm)	LVIDs Avg; 2D and m-mode short axis (cm)
NORMAL PARAMETER	50-100	0.7-1.7	0.7-1.6	BELOW	BELOW	BELOW	BELOW
PATIENT	161	1.40	.90	--	2.8	2.65	--

INTERPRETED BY

Eric Lindquist, DMV DABVP, Cert. IVUSS

IMAGING PERFORMED BY

Shari Reffi, CVT

HOSPITAL NAME

Bergen Passaic

REFERRING VET

Dr. Spitz

INVOICE

13400

DATE

10/1/21

Cardiac Presentation

The echocardiogram in this patient demonstrated normal **left atrial** size based on 3 different LA measurement methods. Chamber volumes and echogenicity were normal. The cranial and caudal **mitral** valve leaflets presented vegetative thickening consistent with endocardiosis. Doppler indicated measurable insufficiency. The **left ventricle** presented thicknesses with linear contour and was not dilated nor restricted. The **myocardium** presented normal echogenicity without subjective evidence of significant fibrotic or ischemic disease. **Contractility** of the ventricular walls was adequate and in normal range for this patient evidenced by the fractional shortening measurement and subjective evaluation of the different regions of the myocardium. The **left ventricular outflow** tract demonstrated normal laminar flow and subjective structural integrity. The **right atrium** and auricle revealed normal size, structure and content. No evidence of masses was noted or chamber overload. Minor **Tricuspid** insufficiency noted. The **right ventricle** was of normal size (1/3 diameter of LV), chordae structure, myocardial echogenicity and thickness. **Pulmonic** tract assessment revealed normal valve structure, laminar flow, and diameter (approx.1:1 pa/ao ratio). No visible **pericardial** or free pleura fluid was noted. No echographically detectable evidence of infiltrative disease was visible. The cranial **mediastinum and pericardial regions** were free of masses in the visible window.

ULTRASONOGRAPHIC FINDINGS

- Stage B1 valvular disease, compensated
- Mitral and tricuspid insufficiency

INTERPRETATION OF THE FINDINGS & FURTHER RECOMMENDATIONS



PATIENT

Ginger Fraile

If anesthesia is necessary, there is no overt contraindication to an anesthetic procedure. Suggested protocol includes Torbutrol premed, Propofol induction, and Isoflurane maintenance. Recheck echocardiogram in 6 months or earlier if murmur grade increases or clinical signs initiate. No treatment recommended.

SPECIES

Canine

BREED

Terrier Mix

SEX

Spayed Female

AGE

10 Years 1 Month

WEIGHT

15.8 Pounds

INTERPRETED BY

Eric Lindquist, DMV
DABVP, Cert. IVUSS

IMAGING PERFORMED BY

Shari Reffi, CVT

HOSPITAL NAME

Bergen Passaic

REFERRING VET

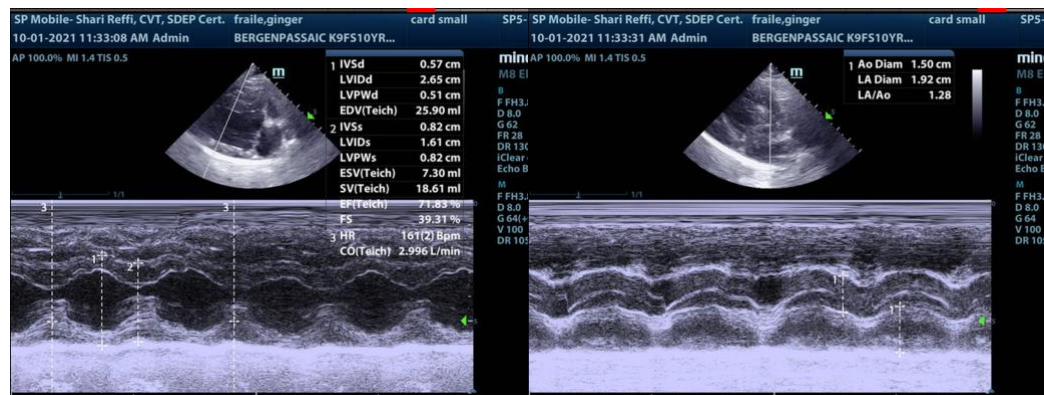
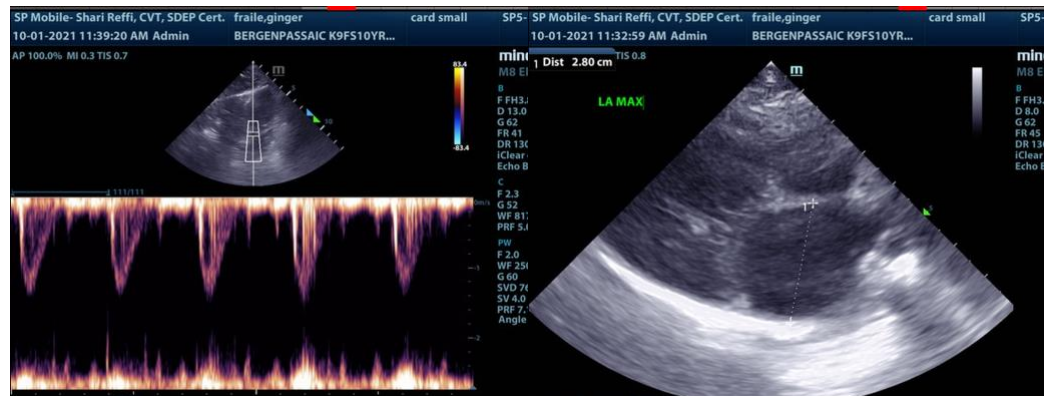
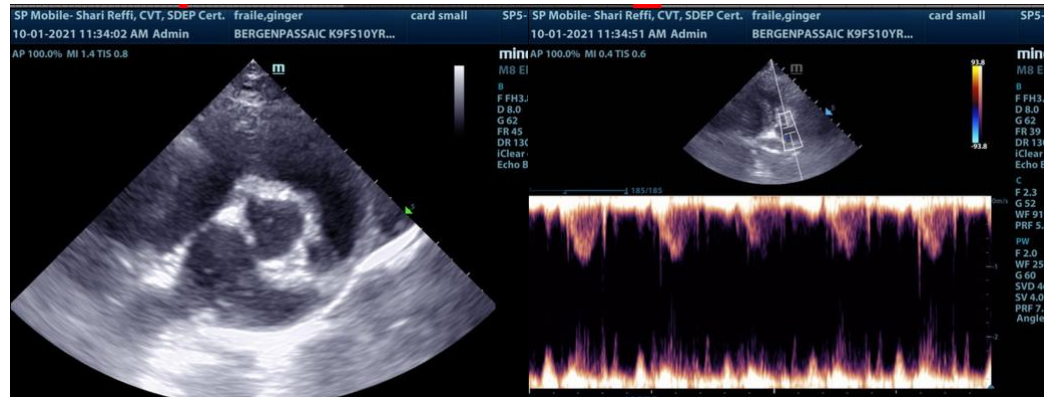Dr. Spitz

INVOICE

13400

DATE

10/1/21





PATIENT

Ginger Fraile

SPECIES

Canine

BREED

Terrier Mix

SEX

Spayed Female

AGE

10 Years 1 Month

WEIGHT

15.8 Pounds

INTERPRETED BY

Eric Lindquist, DMV
DABVP, Cert. IVUSS

IMAGING PERFORMED BY

Shari Reffi, CVT

HOSPITAL NAME

Bergen Passaic

REFERRING VET

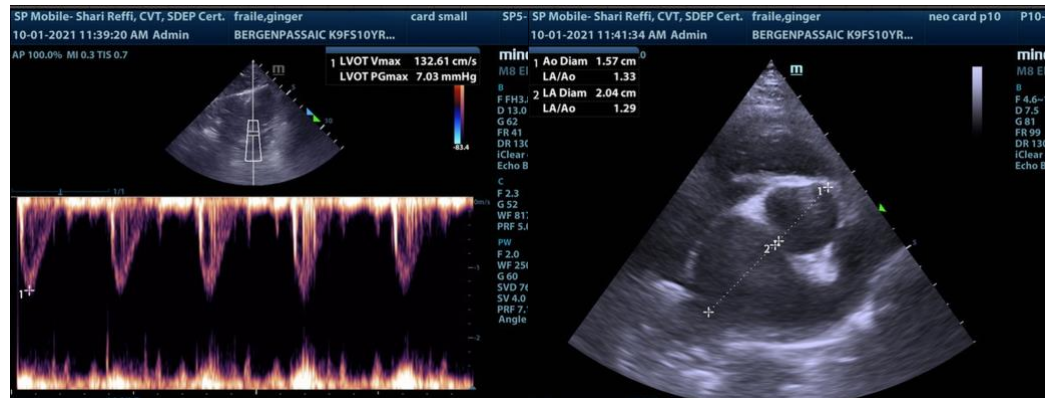
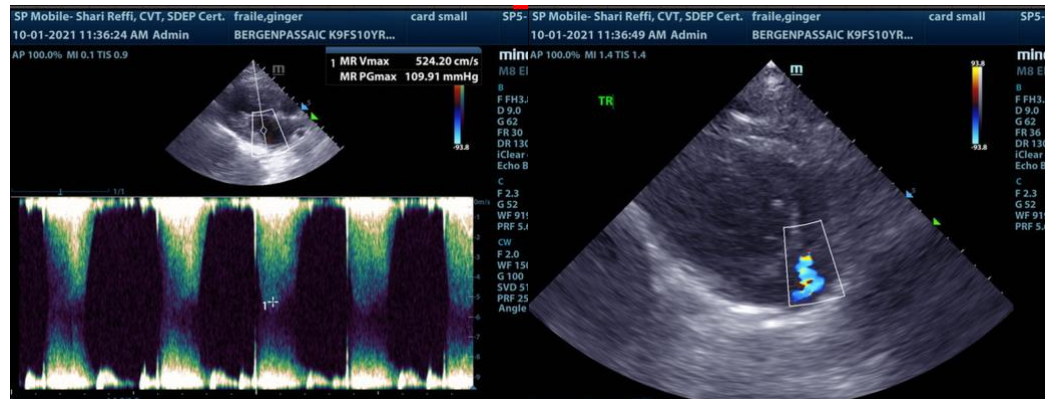
Dr. Spitz

INVOICE

13400

DATE

10/1/21



The information and recommendations provided are based on the images presented by the referring veterinarian. No evaluation can be communicated regarding pathology that was not visible in the image/video clips provided.

Thank you for this referral. If the clinical or image interpretation does not parallel your findings or if I can be of any further assistance please contact me.

Eric Lindquist, DMV, DABVP, Cert. IVUSS, CEO of SonoPath.com
info@SonoPath.com