



PATIENT PRESENTING CLINICAL SIGNS

Echo Smith Patient was bred 5 weeks ago. Owner would like pregnancy check.

SPECIES LIMITED ULTRASONOGRAPHIC EXAMINATION

Canine Positive pregnancy noted in this patient. Fetus length in long axis (top of skull to rump) measured 6.0 cm. Amniotic fluid was anechoic. The uterus and all fetuses appeared normal (approximately 4 fetuses visible with positive heartbeats). Osseous structures and internal organs appeared normal.

BREED ULTRASONOGRAPHIC FINDINGS

German Shorthair Pointer • Positive pregnancy (approximately 4 fetuses at approximately 5-6 weeks gestation)

INTERPRETATION OF THE FINDINGS & FURTHER RECOMMENDATIONS

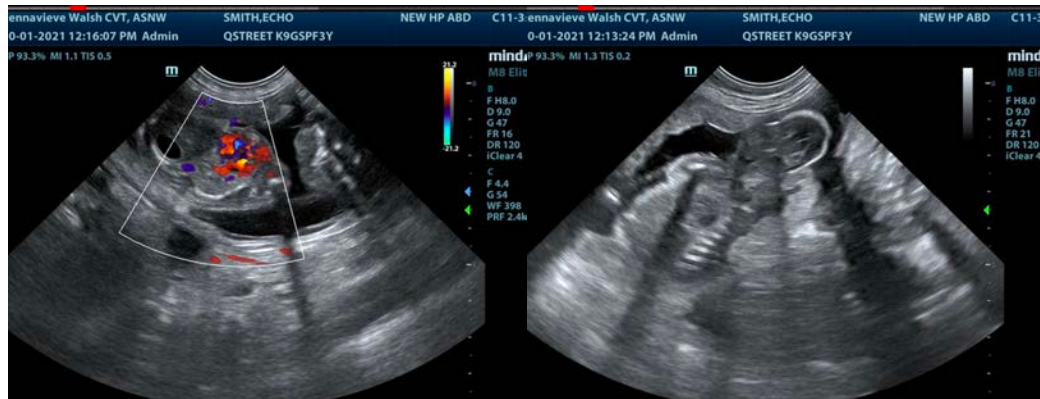Fetal count should be performed based on radiographic findings.

AGE

3 Years

WEIGHT

40 Pounds



INTERPRETED BY

Eric Lindquist, DMV, DABVP, Cert. IVUSS

IMAGING PERFORMED BY

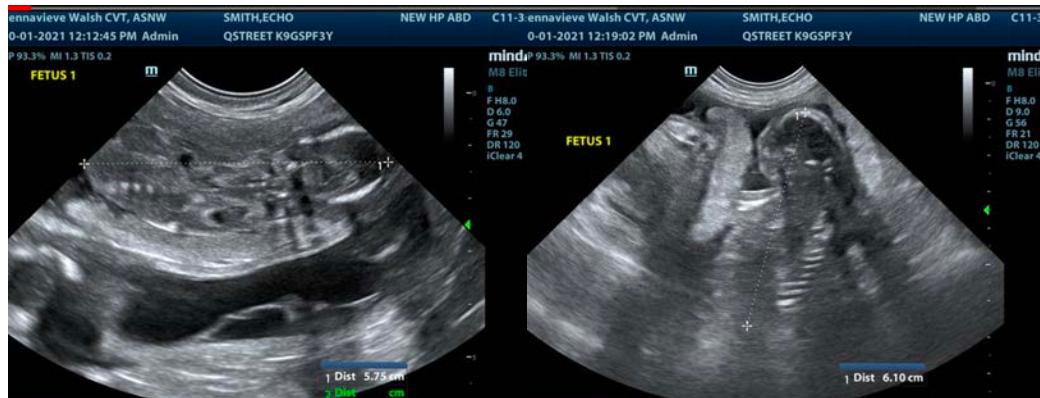
Jenna Walsh, CVT

HOSPITAL NAME

Q Street AH

REFERRING VET

Dr. Hoerauf



DATE

10/1/21

INVOICE

26019



PATIENT

Echo Smith

SPECIES

Canine

BREED

German Shorthair
Pointer

SEX

Female

AGE

3 Years

WEIGHT

40 Pounds

INTERPRETED BY

Eric Lindquist, DMV,
DABVP, Cert. IVUSS

**IMAGING
PERFORMED BY**

Jenna Walsh, CVT

HOSPITAL NAME

Q Street AH

REFERRING VET

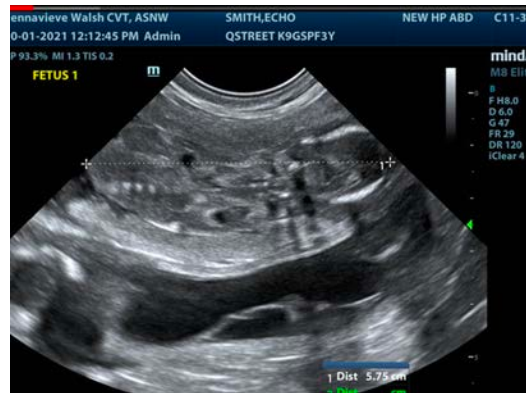Dr. Hoerauf

DATE

10/1/21

INVOICE

26019



The information and recommendations provided are based on the images presented by the referring veterinarian. No evaluation can be communicated regarding pathology that was not visible in the image/video clips provided.

Thank you for this referral. If the clinical or image interpretation does not parallel your findings or if I can be of any further assistance please contact me.

Eric Lindquist, DMV, DABVP, Cert. IVUSS

CEO of Sonopath.com

Eric.Lindquist@SonoPath.com