



## PATIENT PRESENTING CLINICAL SIGNS

**Alley Dunnick** Alley presented on 9/10/21 for ongoing weight loss, intermittent diarrhea and vomiting, and progressive hyporexia. Her diarrhea responded somewhat to an i/d biome diet, but now does not want to eat it. On exam she was thin, with a BCS of 3/9. She had a grade 2/6 left parasternal heart murmur. Her abdomen palpated normally. Current Medications i/d biome diet  
Abnormal PE/Chem/CBC/UA Results: CBC/Chem/T4/UA - WNL except ALT (117)

## SPECIES

Feline

## ULTRASONOGRAPHIC EXAMINATION OF THE ABDOMEN

## BREED

### *Urinary System*

DSH

The **urinary bladder**, trigone, and pelvic urethra presented normal thicknesses and normal tone. The ureters were not visible which is normal. No uroliths or sediment were visualized and anechoic urine was present. No evidence of inflammatory or neoplastic changes were noted. Ureteral papillae were normal.

## SEX

Spayed Female

The **kidneys** revealed largely normal size and structure, corticomedullary definition and ratio (cortex 1/3 of medulla) were essentially maintained with some age-related loss of curvilinear patterns regarding the capsule and C/M junction. The cortices presented largely uniform texture with some increased echogenicity expected for his age patient. Medullary structure differed distinctly from that of the cortex and no evidence of pelvic dilation was present. The right kidney measured 3.0 cm. The left kidney measured 3.0 cm.

## AGE

9 Years

## WEIGHT

7.3 Pounds

### *Adrenal Glands*

Both **adrenal glands** were visualized and recognized as having normal shape, size, position and echogenicity for this breed. The phrenic vasculature, glandular echogenicity and detail were unremarkable. Capsule, cortex, and medullary definition were normal for this age patient. The left adrenal gland measured 0.26 cm.

## INTERPRETED BY

Eric Lindquist, DMV,  
DABVP, Cert. IVUSS

### *Spleen*

The **spleen** presented a smooth homogeneous parenchyma hyperechoic to liver and renal cortical parenchyma. The capsule was smooth without noticeable expansion or deviation from within the spleen or adjacent pathology. The splenic vasculature demonstrated normal volume without signs of congestion or thrombosis. No sonographic evidence of acute or chronic inflammatory, neoplastic, or infarctual changes were noted.

## IMAGING PERFORMED BY

Jenna Walsh, CVT

## HOSPITAL NAME

West Eugene AH

### *Liver*

The **liver** images submitted revealed subjectively normal liver size, contour, and structure. Parenchymal echogenicity was naturally coarse and hypoechoic to the spleen. Vascular and biliary tracts were of normal volume with no evidence of congestion. The gallbladder presented acceptably thin walls with primarily anechoic content. The cystic and common bile ducts were normal. No pathological hepatic lymphadenopathy was evident. No overt structural evidence of inflammatory, infiltrative or regenerative pathology was evident. Portal vein/vena cava ratio was 1:1.

## REFERRING VET

Dr. Sundholm

## DATE

10/1/21

### *Gastrointestinal*

The **gastrointestinal** presentation revealed mild uniform prominence of the gastric mucosa as well as areas of "ropy" small intestinal wall with 1:1 muscularis/mucosal ratio. The stomach was empty. Intestinal wall thickness measured 0.42 cm. The intestinal submucosa was slightly irregular, thickened

## INVOICE

26023



**PATIENT**

Alley Dunnick

**SPECIES**

Feline

**BREED**

DSH

**SEX**

Spayed Female

**AGE**

9 Years

**WEIGHT**

7.3 Pounds

**INTERPRETED BY**

Eric Lindquist, DMV,  
 DABVP, Cert. IVUSS

**IMAGING PERFORMED BY**

Jenna Walsh, CVT

**HOSPITAL NAME**

West Eugene AH

**REFERRING VET**

Dr. Sundholm

**DATE**

10/1/21

**INVOICE**

26023

and hyperechoic suggestive of low grade, chronic disease. No evidence of obstruction was present. Curvilinear patterns were maintained throughout the GI tract. Chronic inflammatory bowel disease is likely with a low possibility of an early neoplastic event such as lymphoma. Full thickness tissue biopsies via open laparotomy, ideally guided by intraoperative ultrasound in order to obtain the most representative mural sample, would be necessary to rule out this possibility. An epigastric lymph node was slight slightly enlarged, measuring 0.69 cm x 0.23 cm.

**Pancreas**

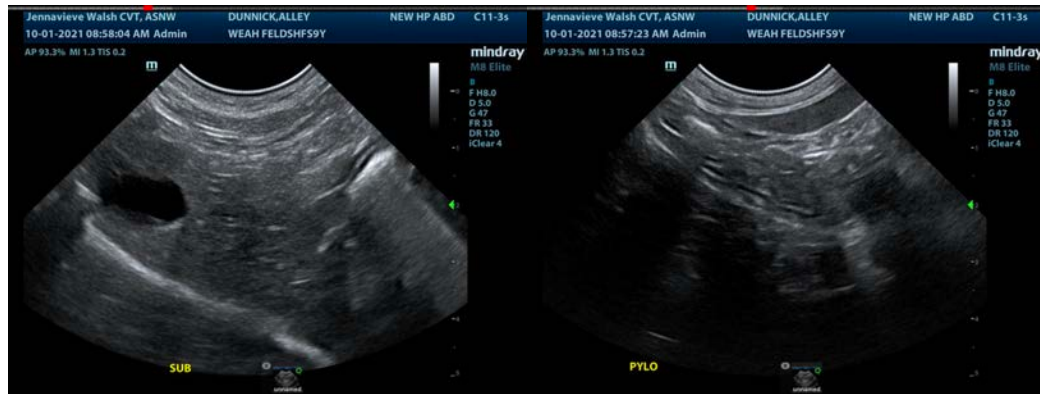
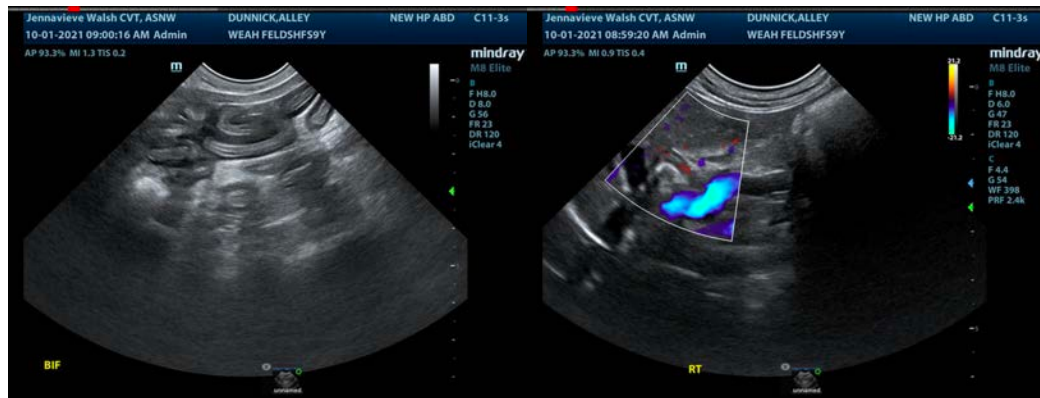
The **pancreas** revealed minor heterogeneous parenchymal changes in both limbs.

**ULTRASONOGRAPHIC FINDINGS**

- Minor heterogeneous pancreas
- Diffuse intestinal thickening without loss of mural detail

**INTERPRETATION OF THE FINDINGS & FURTHER RECOMMENDATIONS**

Neoplastic criteria is not met. However, emerging round cell neoplasia from the intestinal tract could not be completely ruled out without full thickness biopsies. Likely inflammatory bowel, history of pancreatitis, idiopathic muscularis hypertrophy. A clinical trial of the following may prove effective. Maldigestion panel, three view chest radiographs and full CNS examination is recommended to examine for occult disease that could be responsible for the weight loss. Evaluation for competitive eating environments should also be considered.





**PATIENT**

Alley Dunnick

**SPECIES**

Feline

**BREED**

DSH

**SEX**

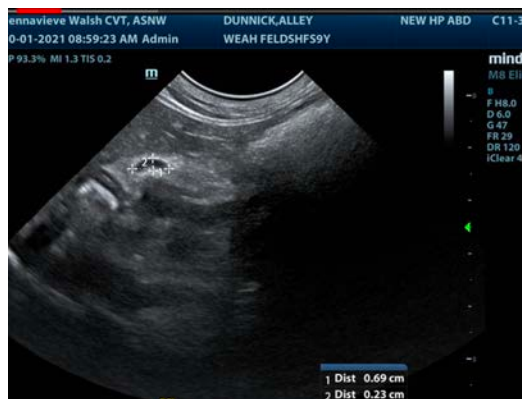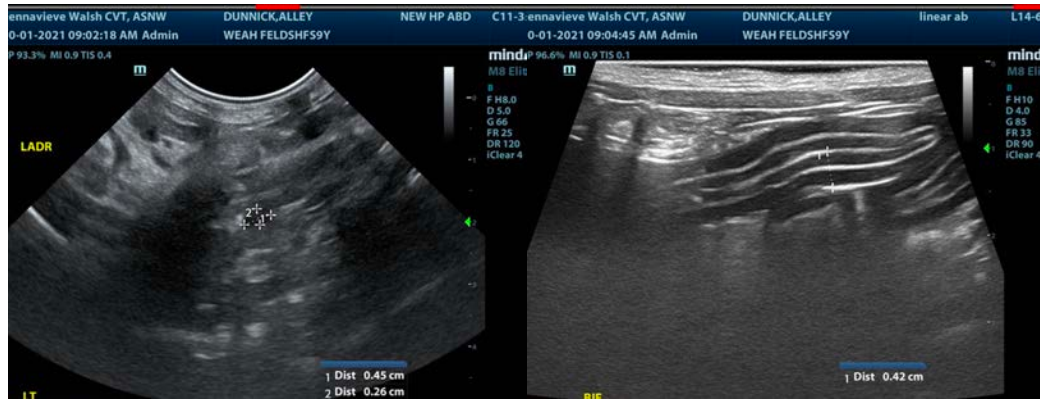
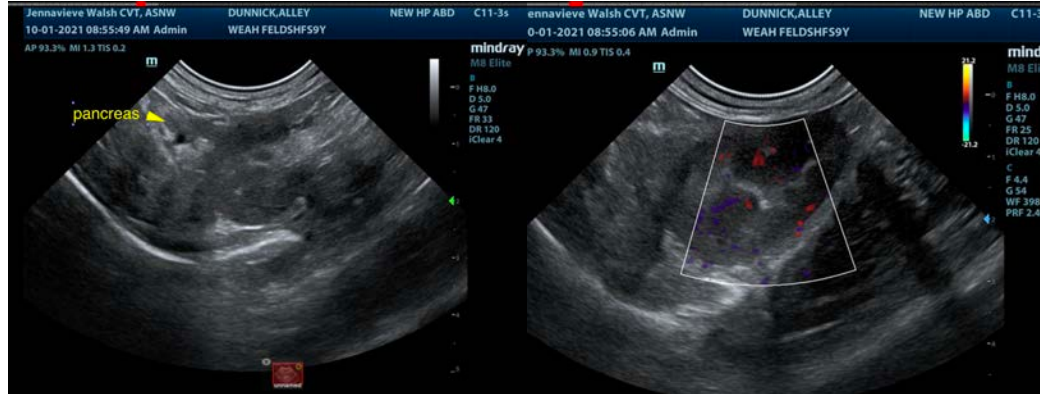
Spayed Female

**AGE**

9 Years

**WEIGHT**

7.3 Pounds



**INTERPRETED BY**

Eric Lindquist, DMV,  
DABVP, Cert. IVUSS

**IMAGING PERFORMED BY**

Jenna Walsh, CVT

**HOSPITAL NAME**

West Eugene AH

**REFERRING VET**

Dr. Sundholm

**DATE**

10/1/21

**INVOICE**

26023

The information and recommendations provided are based on the images presented by the referring veterinarian. No evaluation can be communicated regarding pathology that was not visible in the image/video clips provided.

Thank you for this referral. If the clinical or image interpretation does not parallel your findings or if I can be of any further assistance please contact me.

Eric Lindquist, DMV, DABVP, Cert. IVUSS, CEO of SonoPath.com

Eric.Lindquist@SonoPath.com