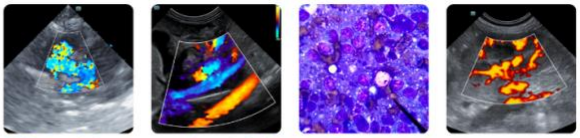



SonoPath FOSTERING THE ART OF VETERINARY MEDICINE™
www.carolinavetmobile.com
info@carolinavetmobile.com
800.808.5948

**PATIENT**

Phoebe Rodwell

**SPECIES**

Feline

**BREED**

DSH

**SEX**

Spayed Female

**AGE**

10 Years 11 Months

**WEIGHT**

9.5 Pounds

**INTERPRETED BY**

Eric Lindquist, DMV, DABVP (Canine & Feline), Cert. IVUSS

**IMAGING PERFORMED BY**

Kathleen Byrnes

**HOSPITAL NAME**

Armstrong AC

**REFERRING VET**

Dr. Gallagher

**INVOICE**

35337

**DATE**

1/9/26

## PRESENTING CLINICAL SIGNS

History of episodic jaundice and weight loss, history of increased liver enzymes 2/6 murmur no clinical signs.

Abnormal PE/Chem/CBC/UA Results:12/2/2025 ALT 690, AST 258, ALP 335, GGT 13, Tbil 9.1, uncon bili 5.4, conj bili 3.7, Chol 451

## ULTRASONOGRAPHIC EXAMINATION OF THE ABDOMEN

### *Urinary System*

The **urinary bladder**, trigone, and pelvic urethra presented normal thicknesses and normal tone. The ureters were not visible which is normal. No uroliths or sediment were visualized and anechoic urine was present. No evidence of inflammatory or neoplastic changes were noted. Ureteral papillae were normal.

The **kidneys** revealed largely normal size and structure, corticomedullary definition and ratio (cortex 1/3 of medulla) were essentially maintained with some mild age-related loss of curvilinear patterns regarding the capsule and C/M junction. The cortices presented largely uniform texture with some increased echogenicity expected for this age patient. Medullary structure differed distinctly from that of the cortex, and no evidence of pelvic dilation was present. The right kidney measured 4.1 cm. The left kidney measured 4.5 cm.

### *Adrenal Glands*

Both **adrenal glands** were visualized and recognized as having normal shape, size, position and echogenicity for this breed. The phrenic vasculature, glandular echogenicity and detail were unremarkable. Capsule, cortex, and medullary definition were normal for this age patient. The right adrenal gland measured 1.0 cm x 0.42 cm. The left adrenal gland measured 0.37 cm.

### *Spleen*

The **spleen** presented a smooth homogeneous parenchyma hyperechoic to liver and renal cortical parenchyma. The capsule was smooth without noticeable expansion or deviation from within the spleen or adjacent pathology. The splenic vasculature demonstrated normal volume without signs of congestion or thrombosis. No sonographic evidence of acute or chronic inflammatory, neoplastic, or infarctual changes were noted.

### *Liver*

The **liver** revealed coarse architecture, mild increased portal markings, and swollen hypoechoic parenchyma. Scant ascites was noted between the liver lobes. The gallbladder revealed a minor amount of debris. A gallbladder polyp (1.4 cm) was noted confirmed by power doppler assessment. The polyp was isoechoic to surrounding tissue. Tissue density was noted in the common bile duct at the junction of the cystic duct. However, the common bile duct was not overtly distended.

### *Gastrointestinal*

A minor amount of fluid filled **gastric** lumen was noted. The small intestine and colon were unremarkable with normal curvilinear patterns and content.

**PATIENT**

Phoebe Rodwell

**SPECIES**

Feline

**BREED**

DSH

**SEX**

Spayed Female

**AGE**

10 Years 11 Months

**WEIGHT**

9.5 Pounds

**INTERPRETED BY**

Eric Lindquist, DMV, DABVP (Canine & Feline), Cert. IVUSS

**IMAGING PERFORMED BY**

Kathleen Byrnes

**HOSPITAL NAME**

Armstrong AC

**REFERRING VET**

Dr. Gallagher

**INVOICE**

35337

**DATE**

1/9/26

## *Pancreas*

The base and limbs of the **pancreas** were observed to be largely isoechoic to surrounding omental fat. Pancreatic duct and capsular contour were acceptably normal and parenchyma respected normal curvilinear patterns. No overt evidence of active inflammatory or neoplastic disease was noted.

## ULTRASONOGRAPHIC FINDINGS

- Diffusely hypoechoic liver with gallbladder polyp and tissue density in the common bile duct- strong concern for biliary carcinoma, however, this may be an incidental finding, as no posthepatic obstruction is present. Suspect diffuse liver disease.
- Geriatric abdomen otherwise

## INTERPRETATION OF THE FINDINGS & FURTHER RECOMMENDATIONS

Ultrasound guided FNA of the liver is indicated, +/- surgical exploratory of the common bile duct and gallbladder. Two separate issues are likely playing a role in this patient. Prognosis is very guarded. Inflammatory polyp versus biliary carcinoma are primary concerns regarding the gallbladder and common bile duct presentation.

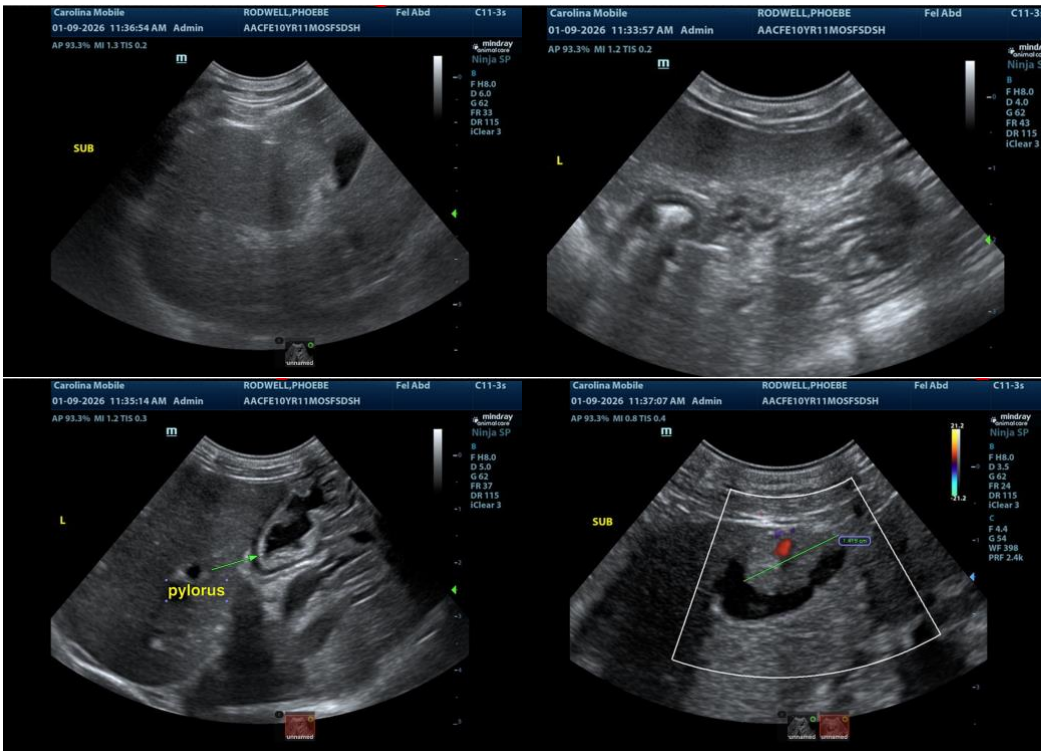

Carolina Veterinary Mobile
FUELED BY SONOPATH VETERINARY ULTRASOUND

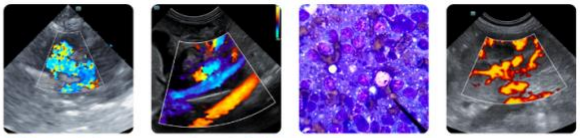

Clinical Sonography & Telecytology
Educational Teleconsultation Services™

SonoPath
FOSTERING THE ART OF VETERINARY MEDICINE™
www.carolinavetmobile.com
info@carolinavetmobile.com
800.808.5948

**PATIENT**

Phoebe Rodwell

**SPECIES**

Feline

**BREED**

DSH

**SEX**

Spayed Female

**AGE**

10 Years 11 Months

**WEIGHT**

9.5 Pounds

**INTERPRETED BY**

Eric Lindquist, DMV, DABVP (Canine & Feline), Cert. IVUSS

**IMAGING PERFORMED BY**

Kathleen Byrnes

**HOSPITAL NAME**

Armstrong AC

**REFERRING VET**

Dr. Gallagher

**INVOICE**

35337

**DATE**

1/9/26

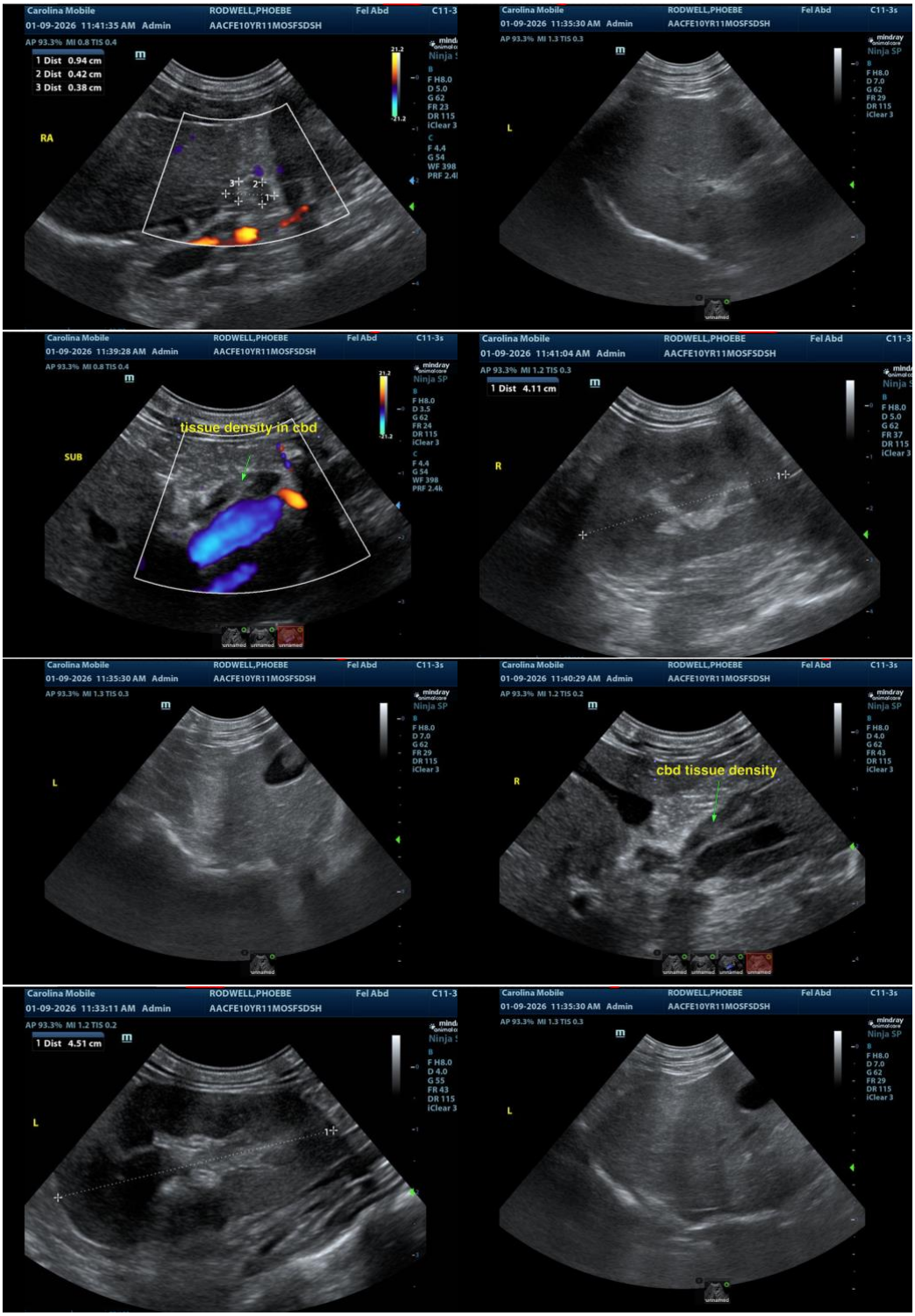

Carolina Veterinary Mobile
FUELED BY SONOPATH VETERINARY ULTRASOUND

SonoPath
FOSTERING THE ART OF VETERINARY MEDICINE™
www.carolinavetmobile.com
info@carolinavetmobile.com
800.808.5948

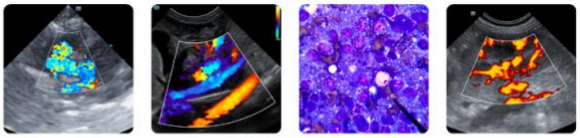

Clinical Sonography & Telecytology
Educational Teleconsultation Services™

**PATIENT**

Phoebe Rodwell

**SPECIES**

Feline

**BREED**

DSH

**SEX**

Spayed Female

**AGE**

10 Years 11 Months

**WEIGHT**

9.5 Pounds

**INTERPRETED BY**

Eric Lindquist, DMV, DABVP (Canine & Feline), Cert. IVUSS

**IMAGING PERFORMED BY**

Kathleen Byrnes

**HOSPITAL NAME**

Armstrong AC

**REFERRING VET**

Dr. Gallagher

**INVOICE**

35337

**DATE**

1/9/26

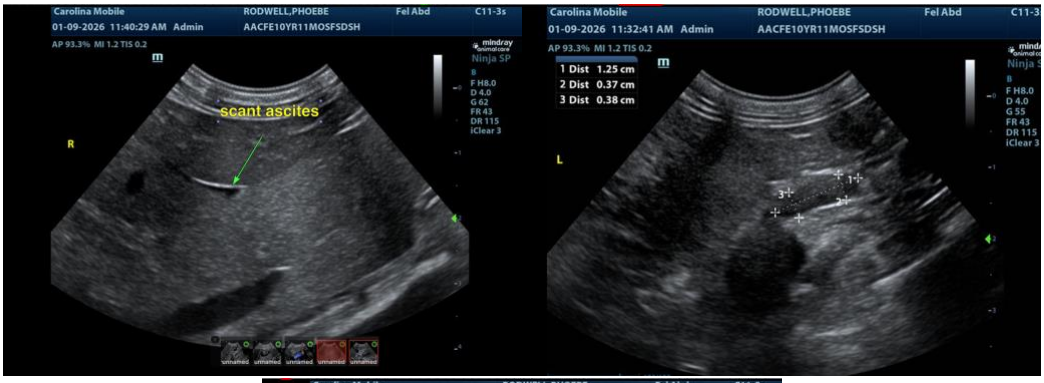

**The information and recommendations provided are based on the images presented by the referring veterinarian/sonographer. No evaluation can be communicated regarding pathology that was not visible in the image/video clips provided.**

Thank you for this referral. If the clinical or image interpretation does not parallel your findings or if I can be of any further assistance please contact me.

**Eric Lindquist**, DMV, DABVP, Cert. IVUSS, CEO of SonoPath.com

info@SonoPath.com