



## PATIENT

Jax Bustamante

## SPECIES

Feline

## BREED

DSH

## SEX

Neutered Male

## AGE

9

## WEIGHT

16

## INTERPRETED BY

Eric Lindquist, DMV,  
DABVP(CFM), Cert.  
IVUSS

## IMAGING PERFORMED BY

Jenn

## HOSPITAL NAME

Rockaway Animal  
Hospital

## REFERRING VET

Dr. Schiess

## INVOICE

13026

## DATE

01/09/2026

## PRESENTING CLINICAL SIGNS

re check prev u/s 9/26 L sided cystadenomatous liver mass Cytology done on 10/7 findings consistent with cystic fluid Owner reports doing well eating/drinking normal stool Current meds Budesonide 2mg/ml 1.2 ml SID

## ULTRASONOGRAPHIC EXAMINATION OF THE ABDOMEN

### Urinary System

The **urinary bladder**, trigone, and pelvic urethra to a depth of 2.0 cm presented normal thicknesses and normal tone. The ureters were not visible which is normal. No uroliths or sediment were visualized, and anechoic urine was present. No evidence of inflammatory or neoplastic changes were noted. Ureteral papillae were normal.

The **kidneys** revealed largely normal size and structure, corticomedullary definition and ratio (cortex 1/3 of medulla) were essentially maintained with some mild age-related loss of curvilinear patterns regarding the capsule and C/M junction. The cortices presented largely uniform texture with some increased echogenicity expected for his age patient. Medullary structure differed distinctly from that of the cortex and no evidence of pelvic dilation was present. The left kidney measured 3.9 cm in length. The right kidney measured 3.85 cm in length.

### Adrenal Glands

Both **adrenal glands** were not definitively visualized.

### Spleen

The **spleen** presented a smooth homogeneous parenchyma hyperechoic to liver and renal cortical parenchyma. The capsule was smooth without noticeable expansion or deviation from within the spleen or adjacent pathology. The splenic vasculature demonstrated normal volume without signs of congestion or thrombosis. No sonographic evidence of acute or chronic inflammatory, neoplastic, or infarctual changes were noted.

### Liver

A cystadenomatous liver mass was present and extensive measuring 5.7 cm x 6.2 cm occupying the left liver and impinges medially (not likely resectable). The liver mass has nearly doubled in size from 3.84 cm on 09/26/2025 to 5.0 to 6.0 cm in size. The right liver and gallbladder were unremarkable.

### Gastrointestinal

Examination of the **gastrointestinal tract** revealed a stomach and intestine free of stasis, of normal wall thickness, acceptable curvilinear mural detail, and peristaltic activity. Small and large intestine demonstrated normal luminal chyme and stool consistency respectively. No obstructive or overt infiltrative disease was noted. No associated abnormal lymphatic activity was noted.

### Pancreas

The base and limbs of the **pancreas** were observed to be largely isoechoic to surrounding omental fat. Pancreatic duct and capsular contour were acceptably normal and parenchyma respected normal curvilinear patterns. No overt evidence of active inflammatory or neoplastic disease was noted.



**PATIENT**

Jax Bustamante

**SPECIES**

Feline

**BREED**

DSH

**SEX**

Neutered Male

**AGE**

9

**WEIGHT**

16

**INTERPRETED BY**

Eric Lindquist, DMV,  
DABVP(CFM), Cert.  
IUUSS

**IMAGING PERFORMED BY**

Jenn

**HOSPITAL NAME**

Rockaway Animal  
Hospital

**REFERRING VET**

Dr. Schiess

**INVOICE**

13026

**DATE**

01/09/2026

**ULTRASONOGRAPHIC FINDINGS**

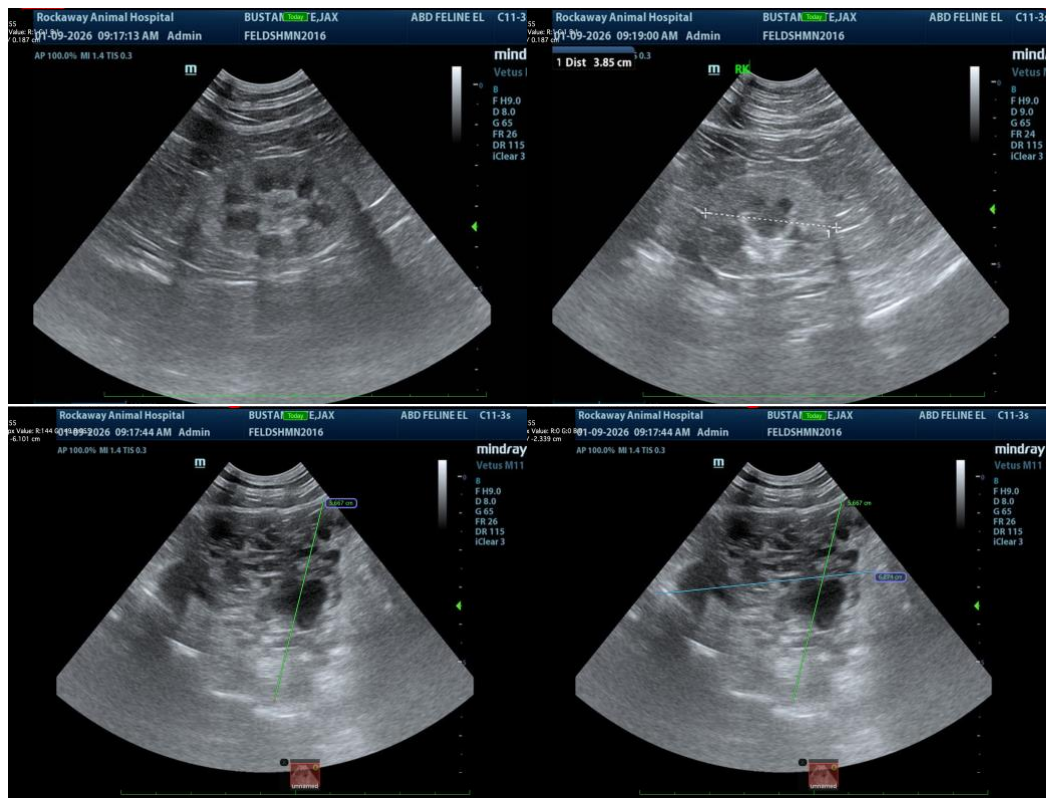
- Cystadenomatous liver mass.
- Age-related renal changes.

**INTERPRETATION OF THE FINDINGS & FURTHER RECOMMENDATIONS**

Strongly recommend CT with potential resection. A cystadenoma is likely, however, given the rapid growth, biliary carcinoma cannot be ruled out. No evidence of metastatic disease.

**ABOUT SONOPATH CT SERVICES:**

SonoPath CT Services are offered at the SonoPath Imaging and Veterinary Education Center, 141 Main St (rt 206), Andover, New Jersey, a 20-minute drive west on route 80/206 North from the route 80/287 interchange/Parsippany, New Jersey. More information can be found at <https://sonopath.com/services/sonopath-ct-services>





## PATIENT

Jax Bustamante

## SPECIES

Feline

## BREED

DSH

## SEX

Neutered Male

## AGE

9

## WEIGHT

16

## INTERPRETED BY

Eric Lindquist, DMV,  
DABVP(CFM), Cert.  
IVUSS

## IMAGING PERFORMED BY

Jenn

## HOSPITAL NAME

Rockaway Animal  
Hospital

## REFERRING VET

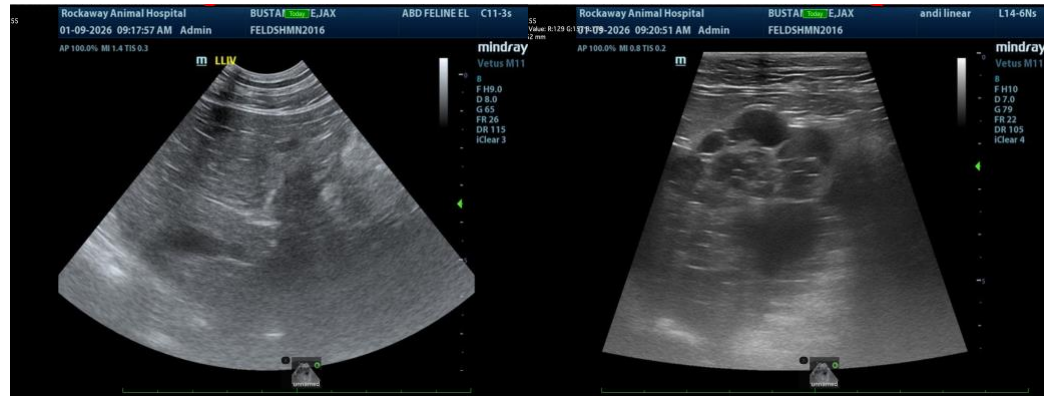
Dr. Schiess

## INVOICE

13026

## DATE

01/09/2026



The information and recommendations provided are based on the images presented by the referring veterinarian/sonographer. No evaluation can be communicated regarding pathology that was not visible in the image/video clips provided.

Thank you for this referral. If the clinical or image interpretation does not parallel your findings or if I can be of any further assistance, please contact me.

Eric Lindquist, DMV, DABVP(CFM), Cert. IVUSS,

CEO, Owner, Founder -- SonoPath.com

[info@SonoPath.com](mailto:info@SonoPath.com)