

DATE PRESENTING CLINICAL SIGNS

01/09/2026 Patient History: On rads for constipation, found lesion cranial to the heart on lateral but not visible on VD
Was not present during rads May 2025

PATIENT

Chia Boegner Current Medications: Prednisolone 5mg 1 in AM 1/2 in PM (previous 1 QD), lactulose prn, Miralax prn, B vit 0.25 cc once per month, LRS SQ 2x/week, Methimazole 5mg 1/2 in AM 1/4 in PM, Marbofloxacin 25mg tab 1 QD for current UTI

SPECIES

Feline

Labwork Results: Labwork attached, reported as: Hypercalcemia - idiopathic, managing with pred and diet + chia seeds

Date of Previous IntraPet Ultrasound: No previous.

Sedation: Not required to complete full diagnostic ultrasound.

Stat Report: Not requested.

BREED

DSH

Imaging Performed by: Rachel Brillhart, RDMS.

LIMITED ULTRASONOGRAPHIC EXAMINATION

SEX

Spayed Female

The cranial mediastinum revealed a 2.66 cm x 1.76 cm anechoic structure that is nonvascular. The structure is suggestive for a branchial cyst. Given that there is a lack of color flow uptake within the lesion, this is likely cystic in origin, however, cranial mediastinal lymph node origin cannot be ruled out especially given the hypercalcemia. No evidence of pleural effusion.

AGE

3/14/2014

ULTRASONOGRAPHIC FINDINGS

WEIGHT

- Suspect benign branchial cyst- dramatically hypo- and anechoic lymph node is possible yet less likely given the lack of blood flow uptake.

9.96 pounds

INTERPRETATION OF THE FINDINGS & FURTHER RECOMMENDATIONS

INTERPRETED BY

Ultrasound guided FNA is indicated for potential drainage or cytology. Given the hypercalcemia, abdominal sonogram is warranted to assess for lesions relation to this evaluation.

Eric Lindquist, DMV, DABVP(CFM), Cert. IVUSS

HOSPITAL NAME

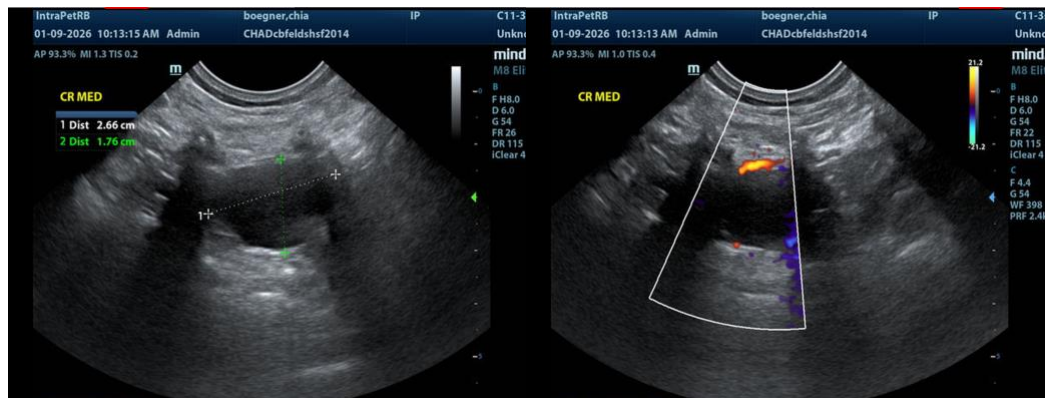
Chadwell Animal Hospital

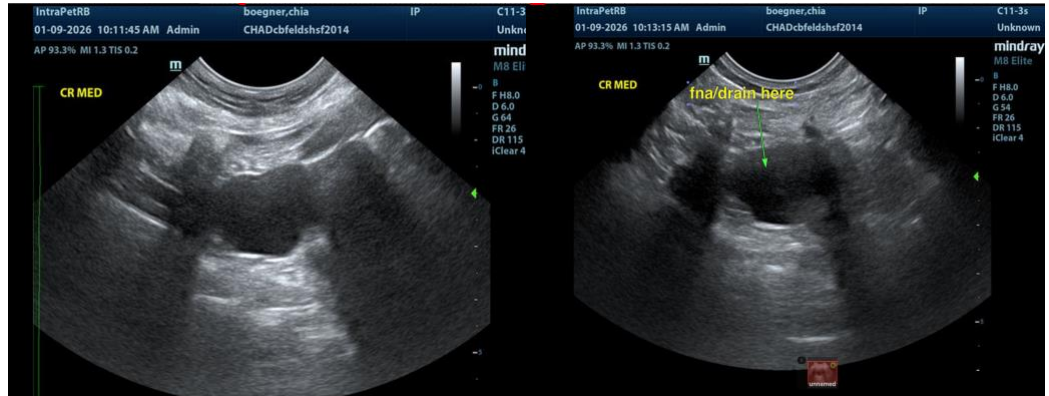
REFERRING VET

Dr. Weeks

INVOICE

13072





The information and recommendations provided are based on the images presented by the referring veterinarian/sonographer. No evaluation can be communicated regarding pathology that was not visible in the image/video clips provided.

Thank you for this referral. If the clinical or image interpretation does not parallel your findings or if I can be of any further assistance, please contact me.

Eric Lindquist, DMV, DABVP(CFM), Cert. IVUSS,

CEO, Owner, Founder -- SonoPath.com

info@SonoPath.com