

PATIENT

Bower Russell

SPECIES

Canine

BREED

Terrier Mix

SEX

Neutered Male

AGE

12

WEIGHT

24.4

INTERPRETED BY

Eric Lindquist, DMV,
DABVP(CFM), Cert.
IVUSS

IMAGING PERFORMED BY

Jenn

HOSPITAL NAME

Rockaway Animal
Hospital

REFERRING VET

Dr. Harrs

INVOICE

13034

DATE

01/09/2026

PRESENTING CLINICAL SIGNS

Shaking, lethargy.

Abnormal PE/Chem/CBC/UA Results: ALB 4.0 ALT 538

ULTRASONOGRAPHIC EXAMINATION OF THE ABDOMEN

Urinary System

The **urinary bladder**, trigone, and pelvic urethra to a depth of 2.0 cm presented normal thicknesses and normal tone. The ureters were not visible which is normal. No uroliths or sediment were visualized, and anechoic urine was present. No evidence of inflammatory or neoplastic changes were noted. Ureteral papillae were normal.

The **kidneys** revealed normal size and structure, corticomedullary definition and ratio for this age. The cortices presented largely uniform texture with normal echogenic relationship to liver and spleen. Medullary structure differed distinctly from the cortex and no evidence of pelvic dilation was present. The capsules were acceptably uniform without significant irregularities. The left kidney measured 4.53 cm in length. The right kidney measured 5.01 cm in length.

Adrenal Glands

Both **adrenal glands** were visualized and recognized as having normal shape, size, position and echogenicity for this breed. The phrenic vasculature, glandular echogenicity and detail were unremarkable. Capsule, cortex, and medullary definition were normal for this age patient. The left adrenal gland measured 1.96 cm x 0.40 cm width at the caudal pole and 0.52 cm width at the cranial pole. The right adrenal gland measured 1.8 cm x 0.61 cm width at the caudal pole and 0.48 cm width at the cranial pole.

Spleen

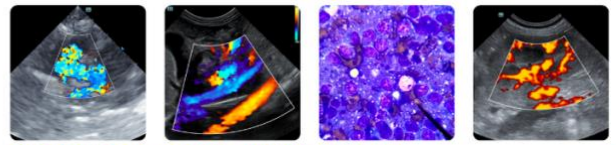
The **spleen** presented a smooth homogeneous parenchyma hyperechoic to liver and renal cortical parenchyma. The capsule was smooth without noticeable expansion or deviation from within the spleen or adjacent pathology. The splenic vasculature demonstrated normal volume without signs of congestion or thrombosis. No sonographic evidence of acute or chronic inflammatory, neoplastic, or infarctual changes were noted.

Liver

The **liver** images from right and left intercostal as well as subcostal views revealed subjectively normal liver size, contour, and structure. Some mild age-related parenchymal remodeling was noted but likely not clinically significant at this time. Vascular and biliary tracts were of normal volume and no evidence of congestion was noted. The gallbladder presented some dependent debris with essentially normal contour. The cystic and common bile ducts were normal. No overt evidence of active inflammatory, infiltrative or regenerative pathology was noted but should be paired with current or past LE elevations regarding any clinical significance to this presentation. The hepatic lymph nodes were unremarkable. Multifocal nodular changes were noted in the liver.

Gastrointestinal

There was some residual chyme and gas was noted in the **stomach**, yet not pathological. This is consistent with end post prandial presentation. Transit of chyme into the small intestine was normal.



PATIENT

Bower Russell

Curvilinear patterns were maintained throughout the GI tract. No evidence of pathology. Small and large intestine demonstrated normal luminal chyme and stool consistency respectively. No obstructive or overt infiltrative disease was noted. No associated abnormal lymphatic activity was noted.

SPECIES

Canine

Pancreas

The base and limbs of the **pancreas** were observed to be largely isoechoic to surrounding omental fat. Pancreatic duct and capsular contour were acceptably normal and parenchyma respected normal curvilinear patterns. No overt evidence of active inflammatory or neoplastic disease was noted.

BREED

Terrier Mix

Free Abdomen

SEX

Neutered Male

A slightly enlarged caudal abdominal lymph node was visualized measuring 4.0 mm. The lymph node was just caudal to the spleen and not likely a primary issue.

AGE

12

ULTRASONOGRAPHIC FINDINGS

- Nodular hyperplasia liver pattern.
- Caudal abdominal lymph nodes- likely benign.

INTERPRETATION OF THE FINDINGS & FURTHER RECOMMENDATIONS

WEIGHT

24.4

FNA of the liver +/- lymph node (if accessible) would be indicated. Orthopedic pain such as spinal pain, thoracic or CNS should be considered in this patient.

INTERPRETED BY

Eric Lindquist, DMV,
DABVP(CFM), Cert.
IVUSS

IMAGING PERFORMED BY

Jenn

HOSPITAL NAME

Rockaway Animal
Hospital

REFERRING VET

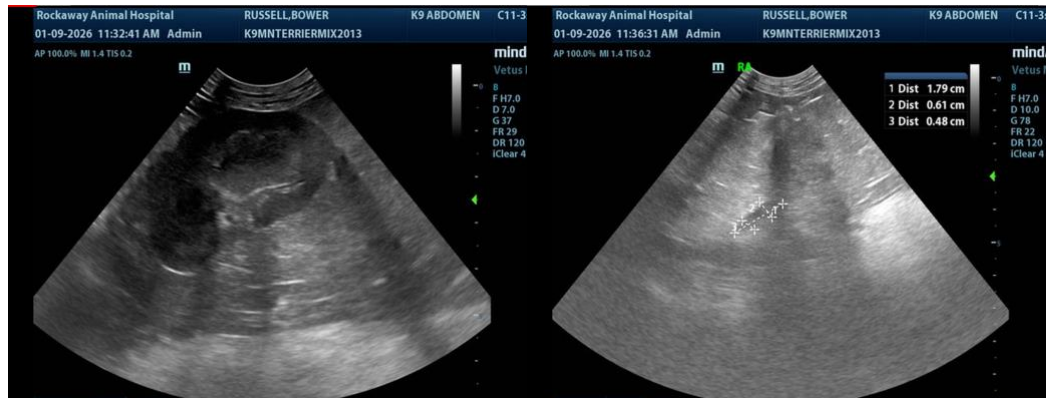
Dr. Harrs

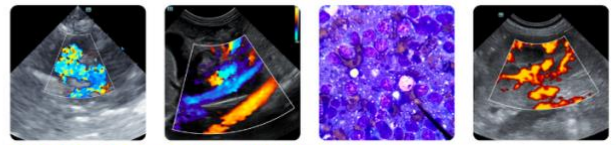
INVOICE

13034

DATE

01/09/2026





PATIENT

Bower Russell

SPECIES

Canine

BREED

Terrier Mix

SEX

Neutered Male

AGE

12

WEIGHT

24.4

INTERPRETED BY

Eric Lindquist, DMV,
DABVP(CFM), Cert.
IVUSS

IMAGING PERFORMED BY

Jenn

HOSPITAL NAME

Rockaway Animal
Hospital

REFERRING VET

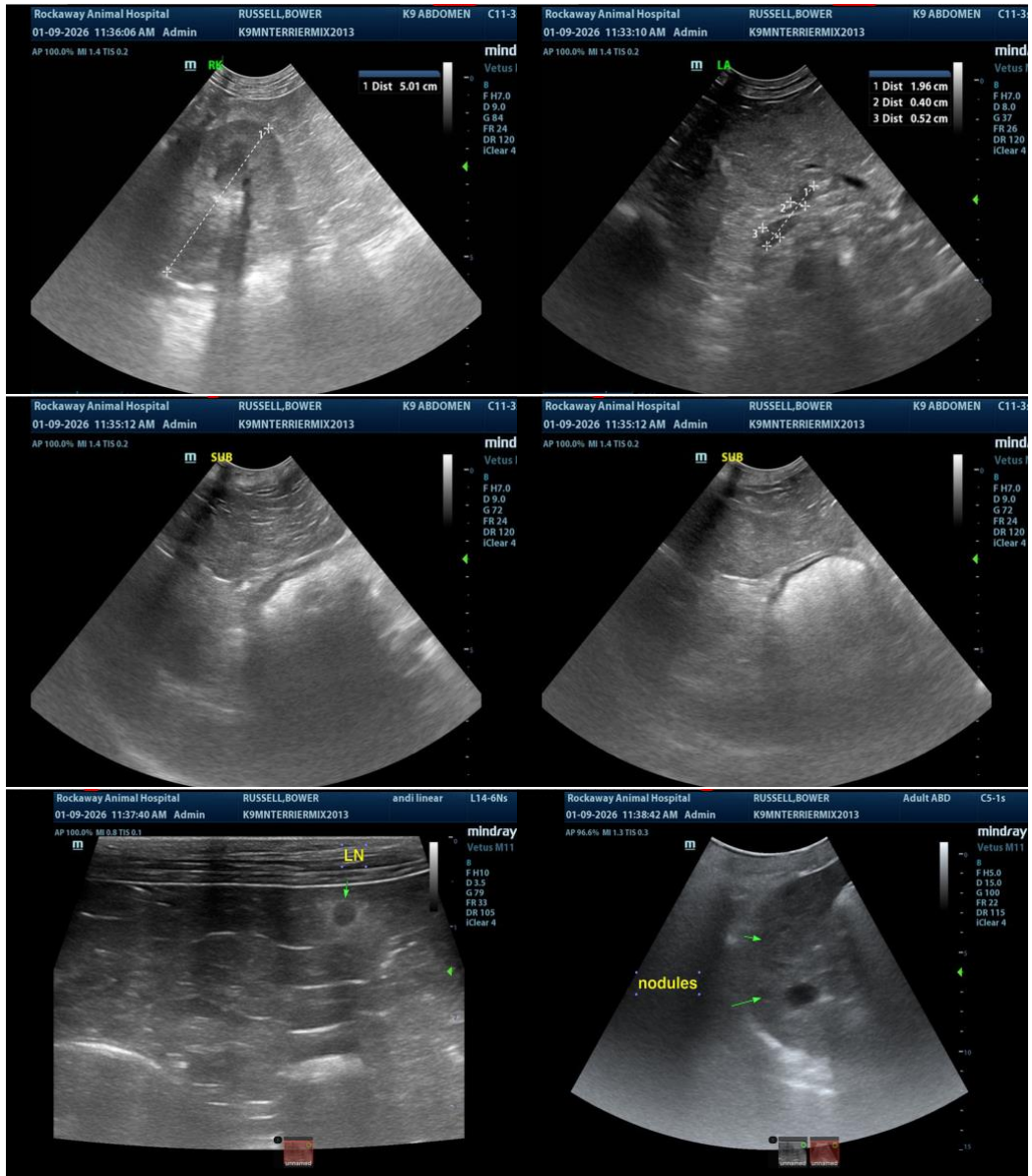
Dr. Harrs

INVOICE

13034

DATE

01/09/2026



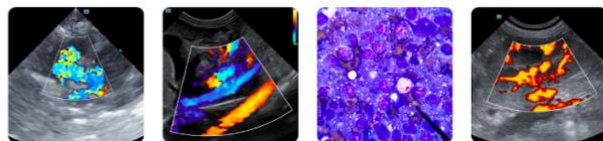
The information and recommendations provided are based on the images presented by the referring veterinarian/sonographer. No evaluation can be communicated regarding pathology that was not visible in the image/video clips provided.

Thank you for this referral. If the clinical or image interpretation does not parallel your findings or if I can be of any further assistance, please contact me.

Eric Lindquist, DMV, DABVP(CFM), Cert. IVUSS,

CEO, Owner, Founder -- SonoPath.com

info@SonoPath.com



PATIENT

Bower Russell

SPECIES

Canine

BREED

Terrier Mix

SEX

Neutered Male

AGE

12

WEIGHT

24.4

INTERPRETED BY

Eric Lindquist, DMV,
DABVP(CFM), Cert.
IVUSS

IMAGING PERFORMED BY

Jenn

HOSPITAL NAME

Rockaway Animal
Hospital

REFERRING VET

Dr. Harrs

INVOICE

13034

DATE

01/09/2026