



**PATIENT**

Billy Alexandre

**SPECIES**

Canine

**BREED**

Havanese

**SEX**

Neutered Male

**AGE**

10 Years

**WEIGHT**

17 Pounds

**INTERPRETED BY**

Eric Lindquist, DMV,  
 DABVP (CFM), Cert.  
 IVUSS

**IMAGING PERFORMED BY**

Vincent Ravancho, CVT

**HOSPITAL NAME**

All Creatures Great &  
 Small Denville

**REFERRING VET**

Dr. Silas

**INVOICE**

35343

**DATE**

1/9/26

**PRESENTING CLINICAL SIGNS**

History: Recheck liver+spleen Ambulatory five

**ULTRASONOGRAPHIC EXAMINATION OF THE ABDOMEN**

**Urinary System**

The **urinary bladder**, trigone, and pelvic urethra presented normal thicknesses and normal tone. The ureters were not visible which is normal. No uroliths or sediment were visualized and anechoic urine was present. No evidence of inflammatory or neoplastic changes was noted. Ureteral papillae were normal. The pelvic urethra was imaged 1.0 cm beyond the cystourethral junction. The residual prostate measured 0.9 cm. Pre- and post-prostatic urethra was unremarkable.

The **kidneys** revealed largely normal size and structure, corticomedullary definition and ratio (cortex 1/3 of medulla) were essentially maintained with some mild age-related loss of curvilinear patterns regarding the capsule and C/M junction. The cortices presented largely uniform texture with some increased echogenicity expected for this age patient. Medullary structure differed distinctly from that of the cortex, and no evidence of pelvic dilation was present. Mineralization was noted in the kidneys. The left kidney measured 4.8 cm. The right kidney measured 5.25 cm.

**Adrenal Glands**

Both **adrenal glands** were visualized and recognized as having normal shape, size, position and echogenicity for this breed. The phrenic vasculature, glandular echogenicity and detail were unremarkable. Capsule, cortex, and medullary definition were normal for this age patient. The right adrenal gland measured 1.74 cm x 0.78 cm at the cranial pole and 0.43 cm at the caudal pole. The left adrenal gland measured 1.78 cm x 0.41 cm at the caudal pole and 0.5 cm at the cranial pole.

**Spleen**

The **spleen** presented a smooth homogeneous parenchyma hyperechoic to liver and renal cortical parenchyma. The capsule was smooth without noticeable expansion or deviation from within the spleen or adjacent pathology. The splenic vasculature demonstrated normal volume without signs of congestion or thrombosis. No sonographic evidence of acute or chronic inflammatory, neoplastic, or infarctual changes were noted.

**Liver**

The **liver** images from right and left intercostal as well as subcostal views revealed subjectively normal liver size, contour, and structure. Some mild age-related parenchymal remodeling was noted but likely not clinically significant at this time. Vascular and biliary tracts were of normal volume, and no evidence of congestion was noted. The gallbladder presented some dependent debris with essentially normal contour. The cystic and common bile ducts were normal. No overt evidence of active inflammatory, infiltrative or regenerative pathology was noted but should be paired with current or past LE elevations regarding any clinical significance to this presentation. The hepatic lymph nodes were unremarkable.

**Gastrointestinal**



**PATIENT**

Billy Alexandre

**SPECIES**

Canine

**BREED**

Havanese

**SEX**

Neutered Male

**AGE**

10 Years

**WEIGHT**

17 Pounds

**INTERPRETED BY**

Eric Lindquist, DMV,  
DABVP (CFM), Cert.  
IUUSS

**IMAGING PERFORMED BY**

Vincent Ravancho, CVT

**HOSPITAL NAME**

All Creatures Great &  
Small Denville

**REFERRING VET**

Dr. Silas

**INVOICE**

35343

**DATE**

1/9/26

Examination of the **gastrointestinal tract** revealed a stomach and intestine free of stasis, of normal wall thickness, acceptable curvilinear mural detail, and peristaltic activity. Small and large intestine demonstrated normal luminal chyme and stool consistency respectively. No obstructive or overt infiltrative disease was noted. No associated abnormal lymphatic activity was noted.

**Pancreas**

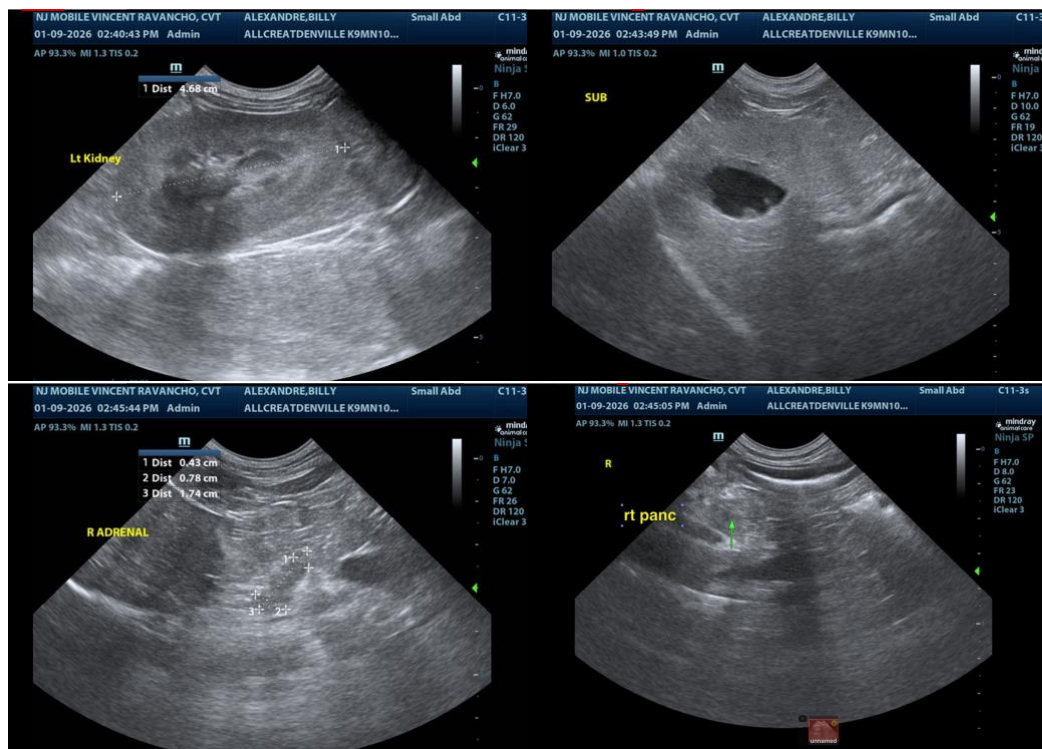
The base and limbs of the **pancreas** were observed to be largely isoechoic to surrounding omental fat. Some mild parenchymal remodeling, however, with mild deviation from curvilinear normalcy was observed. Pancreatic duct and capsular irregularities were present consistent with age related changes. If pain upon imaging (+ Murphy sign) was present or if the patient is focally painful in subxiphoid palpation, then low-grade smoldering chronic pancreatitis should be suspected.

**ULTRASONOGRAPHIC FINDINGS**

- Structurally unremarkable abdomen
- Benign hepatopathy
- Age-related renal changes with mineralization
- Age-related hepatic and pancreatic changes

**INTERPRETATION OF THE FINDINGS & FURTHER RECOMMENDATIONS**

No evidence of significant pathology.





**PATIENT**

Billy Alexandre

**SPECIES**

Canine

**BREED**

Havanese

**SEX**

Neutered Male

**AGE**

10 Years

**WEIGHT**

17 Pounds

**INTERPRETED BY**

Eric Lindquist, DMV,  
 DABVP (CFM), Cert.  
 IVUSS

**IMAGING PERFORMED BY**

Vincent Ravancho, CVT

**HOSPITAL NAME**

All Creatures Great &  
 Small Denville

**REFERRING VET**

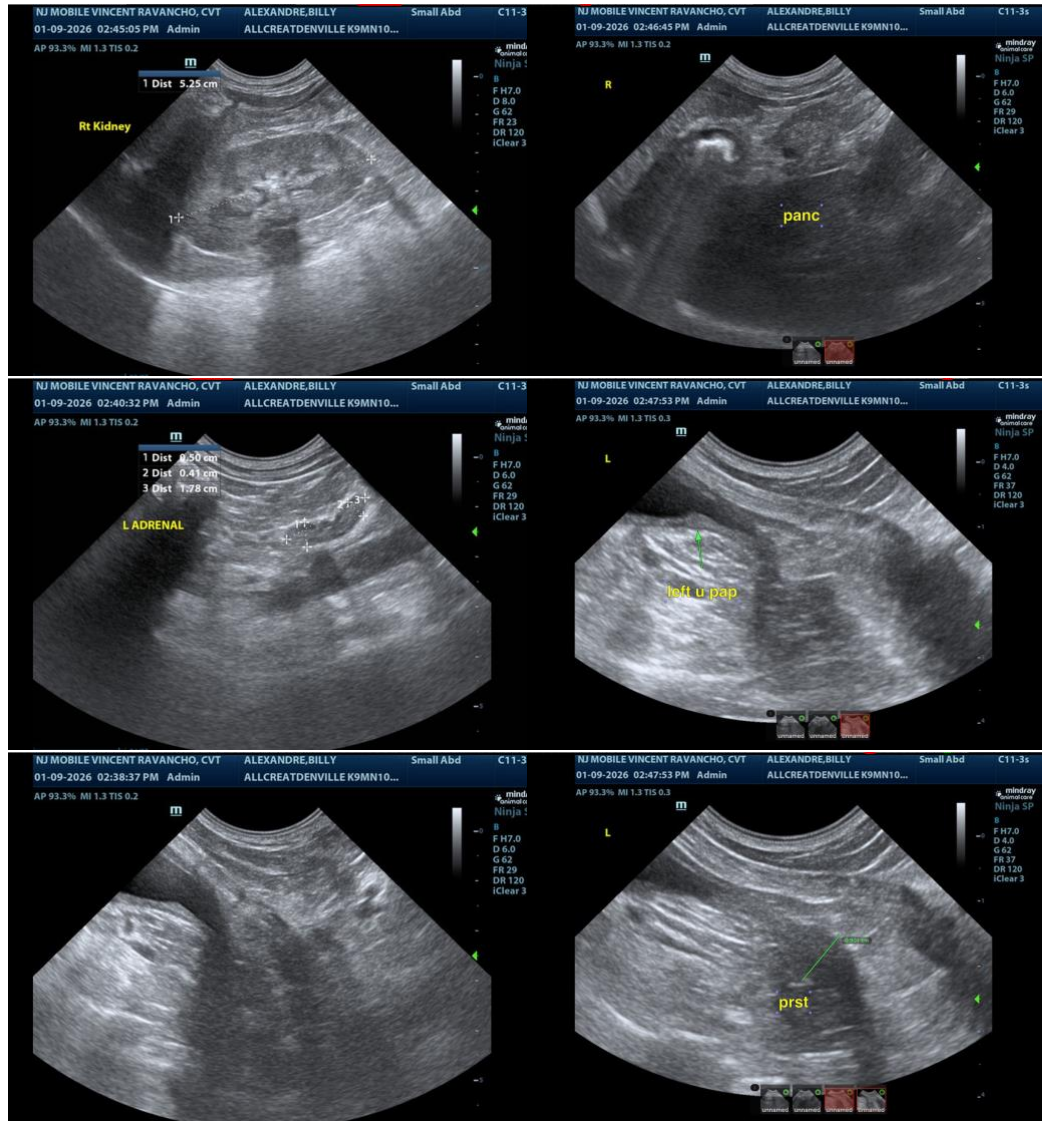
Dr. Silas

**INVOICE**

35343

**DATE**

1/9/26



**The information and recommendations provided are based on the images presented by the referring veterinarian/sonographer. No evaluation can be communicated regarding pathology that was not visible in the image/video clips provided.**

Thank you for this referral. If the clinical or image interpretation does not parallel your findings or if I can be of any further assistance please contact me.

**Eric Lindquist**, DMV, DABVP(CFM), Cert. IVUSS,  
 CEO, Owner, Founder -- SonoPath.com  
[info@SonoPath.com](mailto:info@SonoPath.com)