



## PATIENT

Sydney Gregory

## SPECIES

Canine

## BREED

Japanese Chin

## SEX

Spayed Female

## AGE

10 Years

## WEIGHT

9.76 lbs

## PRESENTING CLINICAL SIGNS

Patient is here for a recheck echo scan-last done May 2025.

## ULTRASONOGRAPHIC EXAMINATION OF THE HEART

CANINE CARDIAC PARAMETERS	MR VMAX (m/s)	TR VMAX (m/s)	LA/AO (M-Mode)	LA/AO (Heart Base; Swe)	FS (%)	EF (%)	EPSS (cm)
NORMAL PARAMETER	4.5-5.5	<2.7	1.3	Up to 1.6	28-40	40-100	<0.6
PATIENT	5.21	--	1.1	1.4	46	80	0.1
CANINE CARDIAC PARAMETERS	HR (BPM)	AV VMAX (m/s)	PV MAX (m/s)	BODY WEIGHT (lbs)	LAD LA MAX 4 Chamber	LVIDd Avg; 2D and m-mode short axis (cm)	LVIDs Avg; 2D and m-mode short axis (cm)
NORMAL PARAMETER	50-100	0.7-1.7	0.7-1.6				
PATIENT	130	0.9	--	9.76	2.46	2.36	--

## INTERPRETED BY

Eric Lindquist, DMV,  
DABVP (CFM), Cert.  
IVUS

## IMAGING PERFORMED BY

Dr. Annette Anleu

## HOSPITAL NAME

Ellwood Animal  
Hospital

## REFERRING VET

Dr. Cynthia Maro

## INVOICE

72067

## DATE

1/8/26

## Cardiac Presentation

The echocardiogram in this patient demonstrated normal **left atrial** size based on 3 different LA measurement methods. Chamber volumes and echogenicity were normal. The cranial and caudal **mitral** valve leaflets presented vegetative thickening consistent with endocardiosis. Doppler indicated eccentric moderate insufficiency. The **left ventricle** presented thicknesses with linear contour and was not dilated nor restricted. The **myocardium** presented normal echogenicity without subjective evidence of significant fibrotic or ischemic disease. **Contractility** of the ventricular walls was adequate and in normal range for this patient evidenced by the fractional shortening measurement and subjective evaluation of the different regions of the myocardium. The **left ventricular outflow** tract demonstrated normal laminar flow and subjective structural integrity. The **right atrium** and auricle revealed normal size, structure and content. No evidence of masses was noted or chamber overload. **Tricuspid** valvular assessment demonstrated adequate linear morphology. The **right ventricle** was of normal size (1/3 diameter of LV), chordae structure, myocardial echogenicity and thickness. **Pulmonic** insufficiency noted. No visible **pericardial** or free pleura fluid was noted. No echographically detectable evidence of infiltrative disease was visible. The cranial **mediastinum** and **pericardial** regions were free of masses in the visible window. Hepatic veins were not dilated.

## ULTRASONOGRAPHIC FINDINGS

- Stable Stage B1 valvular disease, no evidence of volume overload or pressure overload.

## INTERPRETATION OF THE FINDINGS & FURTHER RECOMMENDATIONS

The heart is stable without clinical disease. No overt contraindication for anesthesia of brief to moderate duration. I suggest Torbutrol premed, Propofol induction, Isoflo maintenance or similar protocol if anesthesia is desired. Blood pressure, EKG and chest radiographs are recommended if not



**PATIENT**

Sydney Gregory

**SPECIES**

Canine

**BREED**

Japanese Chin

**SEX**

Spayed Female

**AGE**

10 Years

**WEIGHT**

9.76 lbs

**INTERPRETED BY**

Eric Lindquist, DMV,  
DABVP (CFM), Cert.  
IVUSS

**IMAGING PERFORMED BY**

Dr. Annette Anleu

**HOSPITAL NAME**

Ellwood Animal  
Hospital

**REFERRING VET**

Dr. Cynthia Maro

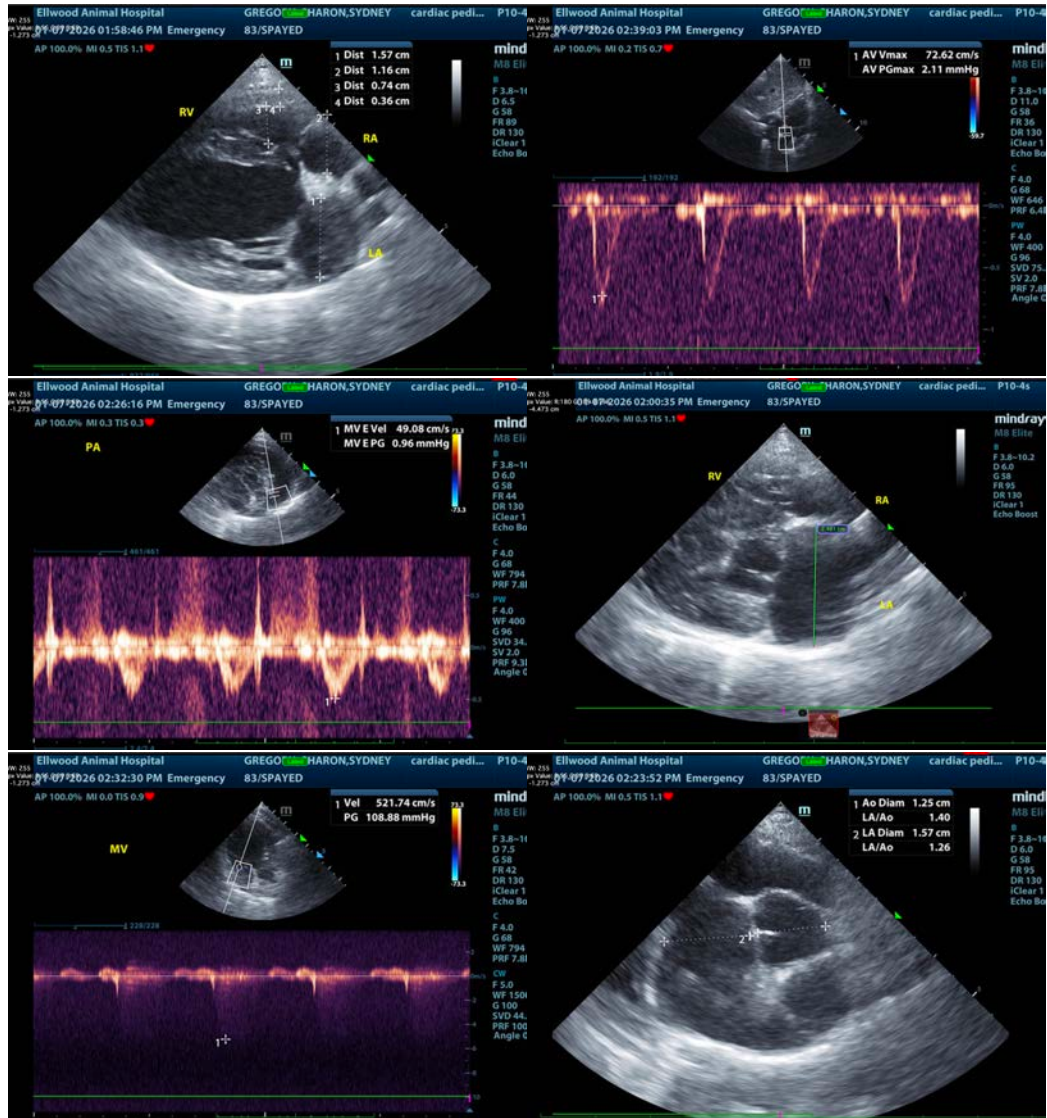
**INVOICE**

72067

**DATE**

1/8/26

already performed. Target white coat negative systolic pressure of < 160 mmHg. If higher than this ACE-inhibitor is suggested to reach this level. Recheck echocardiogram is recommended in 6 months, earlier if murmur grade increases or clinical signs initiate.





**PATIENT**

Sydney Gregory

**SPECIES**

Canine

**BREED**

Japanese Chin

**SEX**

Spayed Female

**AGE**

10 Years

**WEIGHT**

9.76 lbs

**INTERPRETED BY**

Eric Lindquist, DMV,  
DABVP (CFM), Cert. IVUSS

**IMAGING PERFORMED BY**

Dr. Annette Anleu

**HOSPITAL NAME**

Ellwood Animal Hospital

**REFERRING VET**

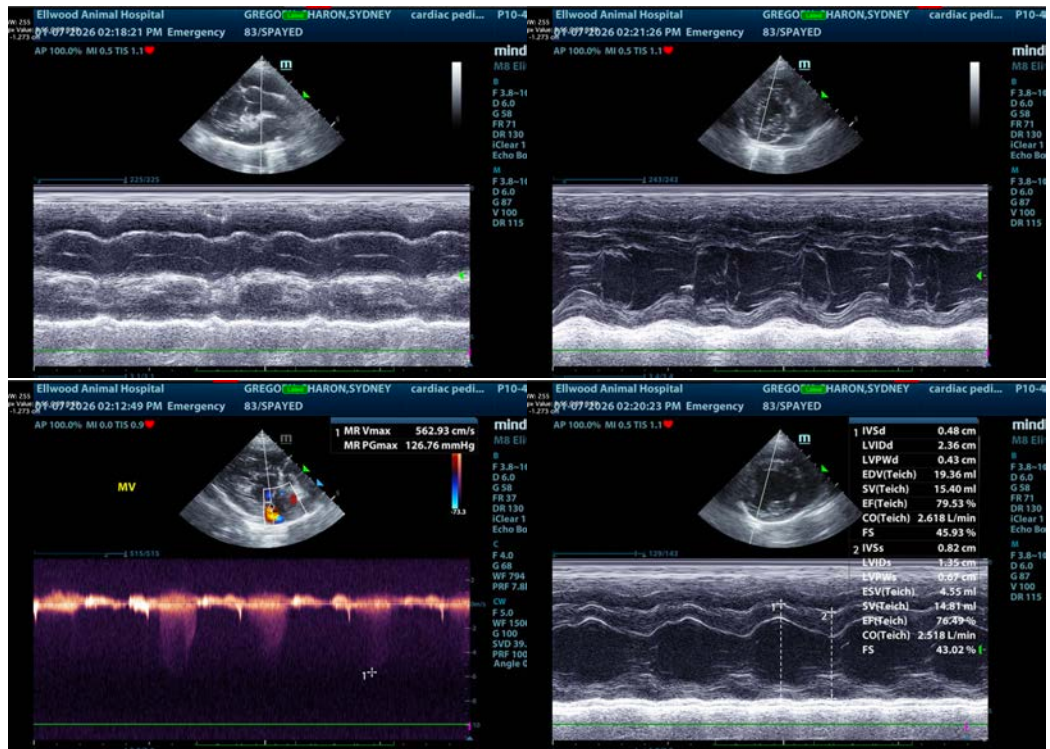
Dr. Cynthia Maro

**INVOICE**

72067

**DATE**

1/8/26



The information and recommendations provided are based on the images presented by the referring veterinarian/sonographer. No evaluation can be communicated regarding pathology that was not visible in the image/video clips provided.

Thank you for this referral. If the clinical or image interpretation does not parallel your findings or if I can be of any further assistance please contact me.

**Eric Lindquist, DMV, DABVP(CFM), Cert. IVUSS,**  
CEO, Owner, Founder -- SonoPath.com  
[info@SonoPath.com](mailto:info@SonoPath.com)