

PATIENT

Pappy 59834213

SPECIES

Canine

BREED

Pitbull

SEX

Neutered Male

AGE

2 Years

WEIGHT

~60 Pounds

INTERPRETED BY

Eric Lindquist, DMV,
DABVP (Canine &
Feline), Cert. IVUSS

**IMAGING
PERFORMED BY**

Greg Shaffer

HOSPITAL NAME

Saint Frances AC

REFERRING VET

Dr. O'Sullivan

INVOICE

35322

DATE

1/8/26

PRESENTING CLINICAL SIGNS

History: Practice scan on. Heartworm Positive. No clinical concerns.
Abnormal PE/Chem/CBC/UA Results: Heartworm Positive.

ULTRASONOGRAPHIC EXAMINATION OF THE ABDOMEN

Urinary System

The **urinary bladder**, trigone, and pelvic urethra presented normal thicknesses and normal tone. The ureters were not visible which is normal. No uroliths or sediment were visualized and anechoic urine was present. No evidence of inflammatory or neoplastic changes was noted. Ureteral papillae were normal.

The **prostate** was uniformly enlarged (4.0 cm) with lobar swelling appeared to impinge upon the urethra and mildly deviate the descending colon. The prostatic tissue was hyperechoic containing focal areas of decreased echogenicity. These changes are moderate and suggestive of either chronic inflammatory episodes, benign cystic pathology or both. Underlying neoplasia cannot be completely ruled-out but is lower on the differential list. This presentation is most consistent with benign prostatic hyperplasia with possible active prostatitis. Neutering or off-label Finasteride (Propecia) (0.1-0.5 mg/kg Sid) treatment is indicated +/- FNA or prostatic wash cytology and culture. Pre- and post-prostatic urethra was imaged, no evident pathology.

The **kidneys** revealed normal size and structure, corticomedullary definition and ratio for this age. The cortices presented largely uniform texture with normal echogenic relationship to liver and spleen. Medullary structure differed distinctly from the cortex, and no evidence of pelvic dilation was present. The capsules were acceptably uniform without significant irregularities. The right kidney measured 6.43 cm. The left kidney measured 6.87 cm.

Adrenal Glands

Both **adrenal glands** were visualized and recognized as having normal shape, size, position and echogenicity for this breed. The phrenic vasculature, glandular echogenicity and detail were unremarkable. Capsule, cortex, and medullary definition were normal for this age patient. The right adrenal gland measured 2.06 cm x 1.0 cm. The left adrenal gland measured 2.3 cm x 0.6 cm.

Spleen

The **spleen** was uniform, folded upon itself cranially and caudally, with subtle micronodular changes.

Liver

The **liver** images submitted revealed subjectively normal liver size, contour, and structure. Parenchymal echogenicity was naturally coarse and hypoechoic to the spleen. Vascular and biliary tracts were of normal volume with no evidence of congestion. The gallbladder presented acceptably thin walls with primarily anechoic content. The cystic and common bile ducts were normal. No pathological hepatic lymphadenopathy was evident. No overt structural evidence of inflammatory, infiltrative or regenerative pathology was evident.

Gastrointestinal



PATIENT

Pappy 59834213

SPECIES

Canine

BREED

Pitbull

SEX

Neutered Male

AGE

2 Years

WEIGHT

~60 Pounds

INTERPRETED BY

Eric Lindquist, DMV,
DABVP (Canine & Feline), Cert. IVUSS

IMAGING PERFORMED BY

Greg Shaffer

HOSPITAL NAME

Saint Frances AC

REFERRING VET

Dr. O'Sullivan

INVOICE

35322

DATE

1/8/26

The **gastrointestinal tract** presented considerable gastric artifact due to the presence of ingesta. This did not permit thorough evaluation of portions of the gastric and upper intestinal structure. No overt abnormality was seen in the visualized tissue, however. This is consistent with a post-prandial presentation within a few hours of mealtime. If the prandial temporal interval does not fit the case history, and the patient presents a history of post-prandial vomiting, this could indicate a delayed upper gastrointestinal outflow due to primary or secondary pyloric hypertrophy, upper GI infiltrative disease, motor deficits, or a non-visualized foreign body. A prudent approach would be to rescan this patient at 24-hour NPO status to further review the non-visible regions if stomach primarily as well as assess any delayed outflow issue.

Pancreas

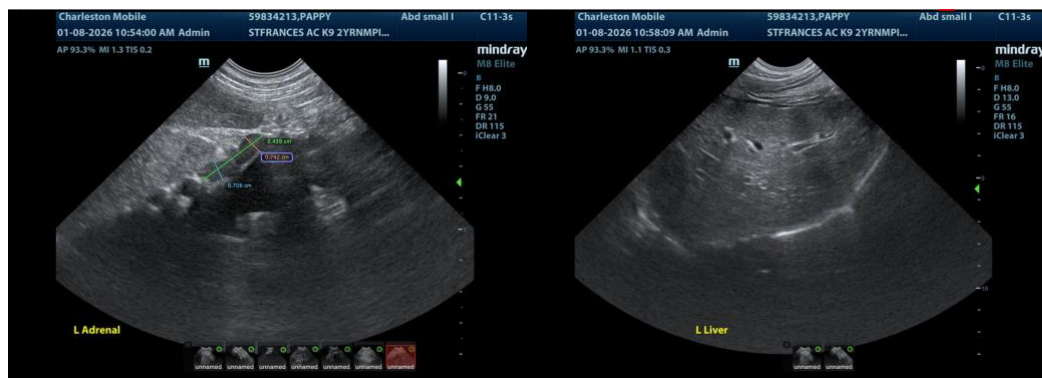The base and limbs of the **pancreas** were observed to be largely isoechoic to surrounding omental fat. Pancreatic duct and capsular contour were acceptably normal and parenchyma respected normal curvilinear patterns. No overt evidence of active inflammatory or neoplastic disease was noted.

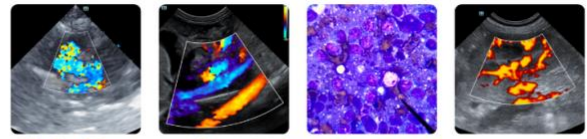
ULTRASONOGRAPHIC FINDINGS

- BPH prostate
- Subtle micronodular changes in the spleen
- Full stomach

INTERPRETATION OF THE FINDINGS & FURTHER RECOMMENDATIONS

Tick borne disease panel is warranted given the splenic presentation. The spleen is likely a reactive state or hyperplasia, assuming the patient was not NPO at the time of the sonogram. No evidence of gross pathology. Given the recent neutering, the prostatic presentation should self-resolve.





PATIENT

Pappy 59834213

SPECIES

Canine

BREED

Pitbull

SEX

Neutered Male

AGE

2 Years

WEIGHT

~60 Pounds

INTERPRETED BY

Eric Lindquist, DMV,
 DABVP (Canine &
 Feline), Cert. IVUSS

IMAGING PERFORMED BY

Greg Shaffer

HOSPITAL NAME

Saint Frances AC

REFERRING VET

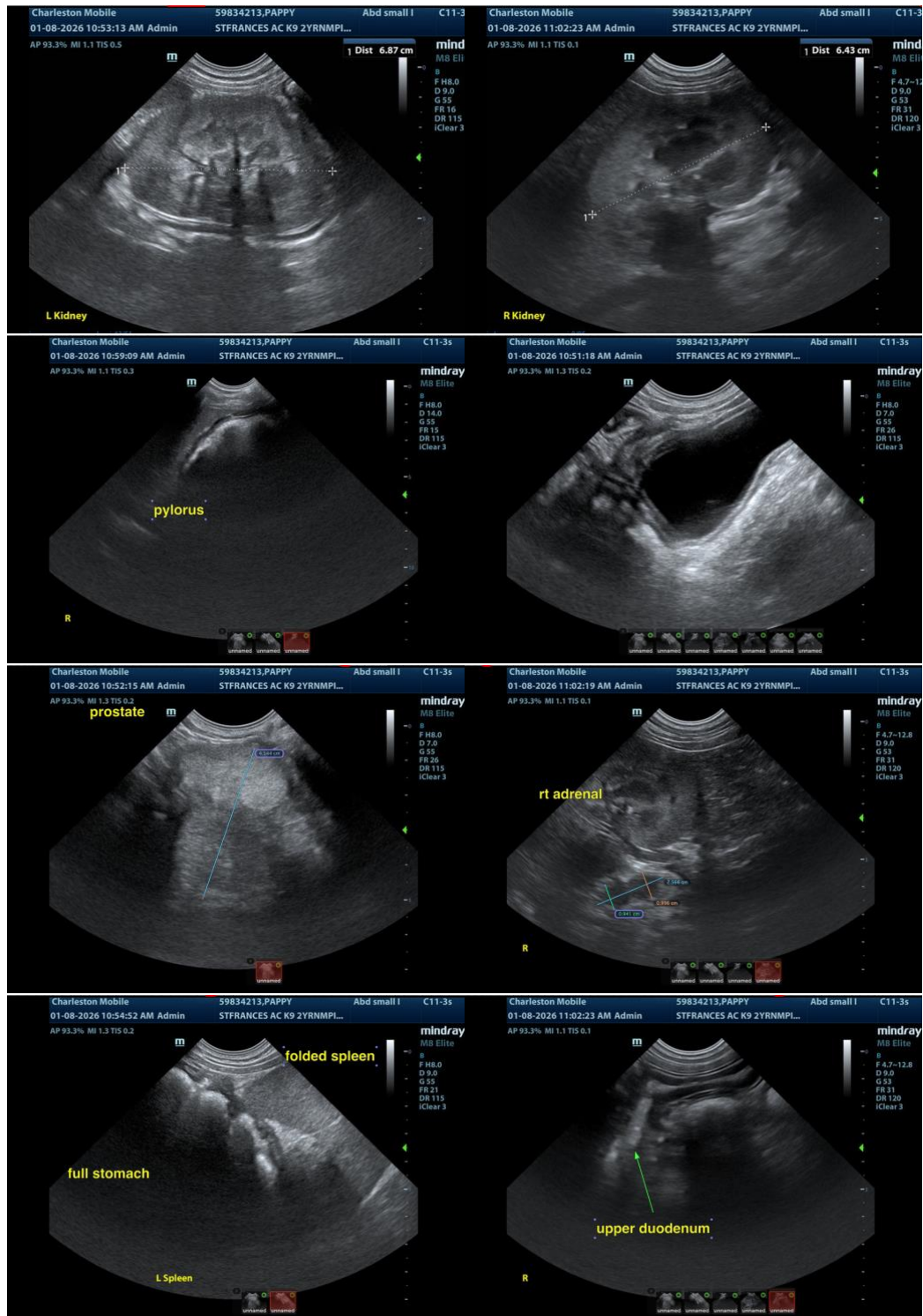
Dr. O'Sullivan

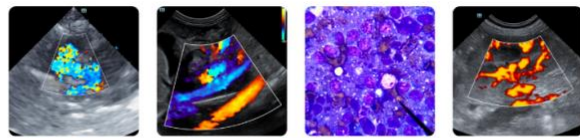
INVOICE

35322

DATE

1/8/26





PATIENT

Pappy 59834213

SPECIES

Canine

BREED

Pitbull

SEX

Neutered Male

AGE

2 Years

WEIGHT

~60 Pounds

INTERPRETED BY

Eric Lindquist, DMV,
 DABVP (Canine & Feline), Cert. IVUSS

IMAGING PERFORMED BY

Greg Shaffer

HOSPITAL NAME

Saint Frances AC

REFERRING VET

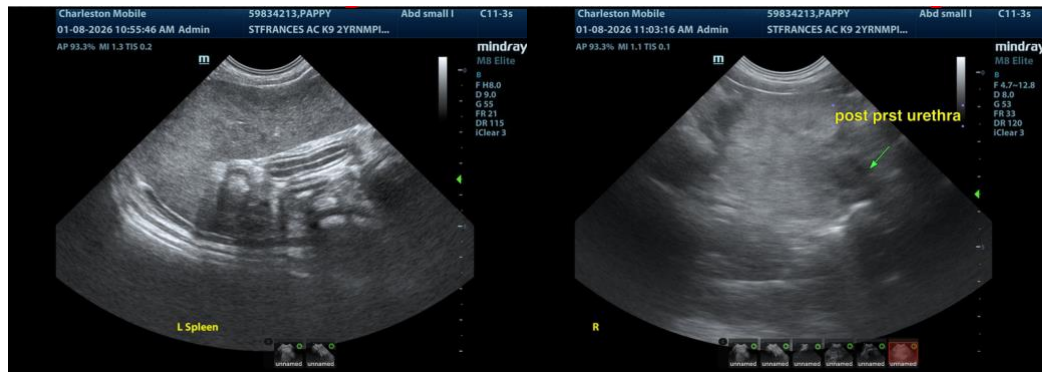
Dr. O'Sullivan

INVOICE

35322

DATE

1/8/26



The information and recommendations provided are based on the images presented by the referring veterinarian. No evaluation can be communicated regarding pathology that was not visible in the image/video clips provided.

Thank you for this referral. If the clinical or image interpretation does not parallel your findings or if I can be of any further assistance please contact me.

Eric Lindquist, DMV, DABVP, Cert. IVUSS, CEO of SonoPath.com

info@SonoPath.com