



**PATIENT**

Missy Thompson

**SPECIES**

Feline

**BREED**

DSH

**SEX**

Spayed Female

**AGE**

12 Years

**WEIGHT**

15 Pounds

**INTERPRETED BY**

Eric Lindquist, DMV,  
 DABVP (Canine & Feline), Cert. IVUSS

**IMAGING PERFORMED BY**

Dr. Ken Leal

**HOSPITAL NAME**

St. Georges VH

**REFERRING VET**

Dr. Patel

**INVOICE**

35304

**DATE**

1/8/26

**PRESENTING CLINICAL SIGNS**

History: Chronic vomiting EOD PU/PD overweight Periodontal disease Seborrheic Dermatitis Rule out IMD, vs other Echo done for pre anesthesia.

Abnormal PE/Chem/CBC/UA Results: PSL: 29 eosinophils = 1484 T4 = 3.0 creatinine = 1.2 BUN = 20 Fecal = negative.

**ULTRASONOGRAPHIC EXAMINATION OF THE HEART & ABDOMEN**

FELINE CARDIAC PARAMETERS	BODY WEIGHT (kg)	HR (BPM)	IVSd (cm)	LVIDd (cm)	LVWd (cm)	FS (%)	EF (%)
<b>NORMAL PARAMETER</b>	-----	150-240	0.3-0.6	1.0-2.1	0.25-0.6	35-67	80-100
<b>PATIENT</b>	--	218	0.63	1.09	0.49	47	82
FELINE CARDIAC PARAMETERS	LA/AO (M-mode)	LA/AO HEART BASE (Sisson)	LAD LA MAX 4 Chamber		LVOT VEL. (m/s)	RVOT VEL. (m/s)	IVRT (m/)
<b>NORMAL PARAMETER</b>	<1.5	1.6	0.7-1.7		<1.6	<1.3	40-60
<b>PATIENT</b>	1.07	1.1	1.2		1.30	1.53	NM
Adapted from June Boon, Veterinary Echocardiography, 1998 Sisson D et al. JVIM 1991; 5: 232, Jacobs et al. Am J Vet Res 1985; 46:1705							

**Cardiac Presentation**

The echocardiogram in this patient demonstrated normal **left atrial** size based on 3 separate LA measurements. The cranial and caudal **mitral** valve leaflets presented normal linear structure and kinetics. The **left ventricle** presented normal thicknesses with linear contour and was not dilated nor restricted. Minor **myocardial** remodeling was noted in this patient. **Contractility** of the ventricular walls was adequate and in normal range for this patient evidenced by the fractional shortening measurement and subjective evaluation of the different regions and angles of the myocardium. The **left ventricular outflow** tract demonstrated normal laminar flow and subjective structural integrity. The **right atrium** and auricle revealed normal size, structure and content. No evidence of masses was noted or chamber overload. **Tricuspid** valvular assessment demonstrated adequate linear morphology and kinetics. The **right ventricle** was of normal size (1/3 diameter of LV), chordae structure, myocardial echogenicity and thickness. **Pulmonic** tract assessment revealed normal valve structure, laminar flow, and diameter (approx. 1:1 pa/ao ratio). No visible **pericardial** or free pleura fluid was noted or extra cardiac pathology in the visible planes. The cranial **mediastinum and pericardial regions** were free of masses in the visible window.



**PATIENT**

**Urinary System**

Missy Thompson

The **urinary bladder**, trigone, and pelvic urethra presented normal thicknesses and normal tone. The ureters were not visible which is normal. No uroliths or sediment were visualized and anechoic urine was present. No evidence of inflammatory or neoplastic changes was noted. Ureteral papillae were normal.

**SPECIES**

Feline

**BREED**

DSH

**SEX**

Spayed Female

The **kidneys** presented a relatively uniform cortical hyperechogenicity when compared to the renal medulla, spleen and liver. No overt masses were noted. Corticomedullary definition was nebulous, and the ratio favored the cortex slightly. The ureters were not visible and assumed to be normal. These changes are most consistent with chronic interstitial nephritis yet infiltrative disease could not be entirely ruled out without biopsy though neoplasia is not suspected. The left kidney measured 4.0 cm. The right kidney measured 3.8 cm.

**AGE**

12 Years

**Adrenal Glands**

The **right adrenal gland** was visualized and recognized as having normal shape, size, position and echogenicity for this breed. The phrenic vasculature, glandular echogenicity and detail were unremarkable. Capsule, cortex, and medullary definition were normal for this age patient. The right adrenal gland measured 0.47 cm.

**WEIGHT**

15 Pounds

The region of the **left adrenal gland** revealed no evident pathology.

**INTERPRETED BY**

**Spleen**

Eric Lindquist, DMV,  
DABVP (Canine &  
Feline), Cert. IVUSS

The **spleen** presented a smooth homogeneous parenchyma hyperechoic to liver and renal cortical parenchyma. The capsule was smooth without noticeable expansion or deviation from within the spleen or adjacent pathology. The splenic vasculature demonstrated normal volume without signs of congestion or thrombosis. No sonographic evidence of acute or chronic inflammatory, neoplastic, or infarctual changes were noted.

**IMAGING PERFORMED BY**

**Liver**

Dr. Ken Leal

The **liver** images submitted revealed subjectively normal liver size, contour, and structure. Parenchymal echogenicity was naturally coarse and hypoechoic to the spleen. Vascular and biliary tracts were of normal volume with no evidence of congestion. The gallbladder presented acceptably thin walls with primarily anechoic content. The cystic and common bile ducts were normal. No pathological hepatic lymphadenopathy was evident. No overt structural evidence of inflammatory, infiltrative or regenerative pathology was evident.

**HOSPITAL NAME**

St. Georges VH

**REFERRING VET**

Dr. Patel

**Gastrointestinal**

**INVOICE**

Examination of the **gastrointestinal tract** revealed a stomach and intestine free of stasis, of normal wall thickness, acceptable curvilinear mural detail, and peristaltic activity. Small and large intestine demonstrated normal luminal chyme and stool consistency respectively. No obstructive or overt infiltrative disease was noted. No associated abnormal lymphatic activity was noted.

35304

**DATE**

**Pancreas**

1/8/26



**PATIENT**

Missy Thompson

**SPECIES**

Feline

**BREED**

DSH

**SEX**

Spayed Female

**AGE**

12 Years

**WEIGHT**

15 Pounds

**INTERPRETED BY**

Eric Lindquist, DMV,  
 DABVP (Canine &  
 Feline), Cert. IVUSS

**IMAGING PERFORMED BY**

Dr. Ken Leal

**HOSPITAL NAME**

St. Georges VH

**REFERRING VET**

Dr. Patel

**INVOICE**

35304

**DATE**

1/8/26

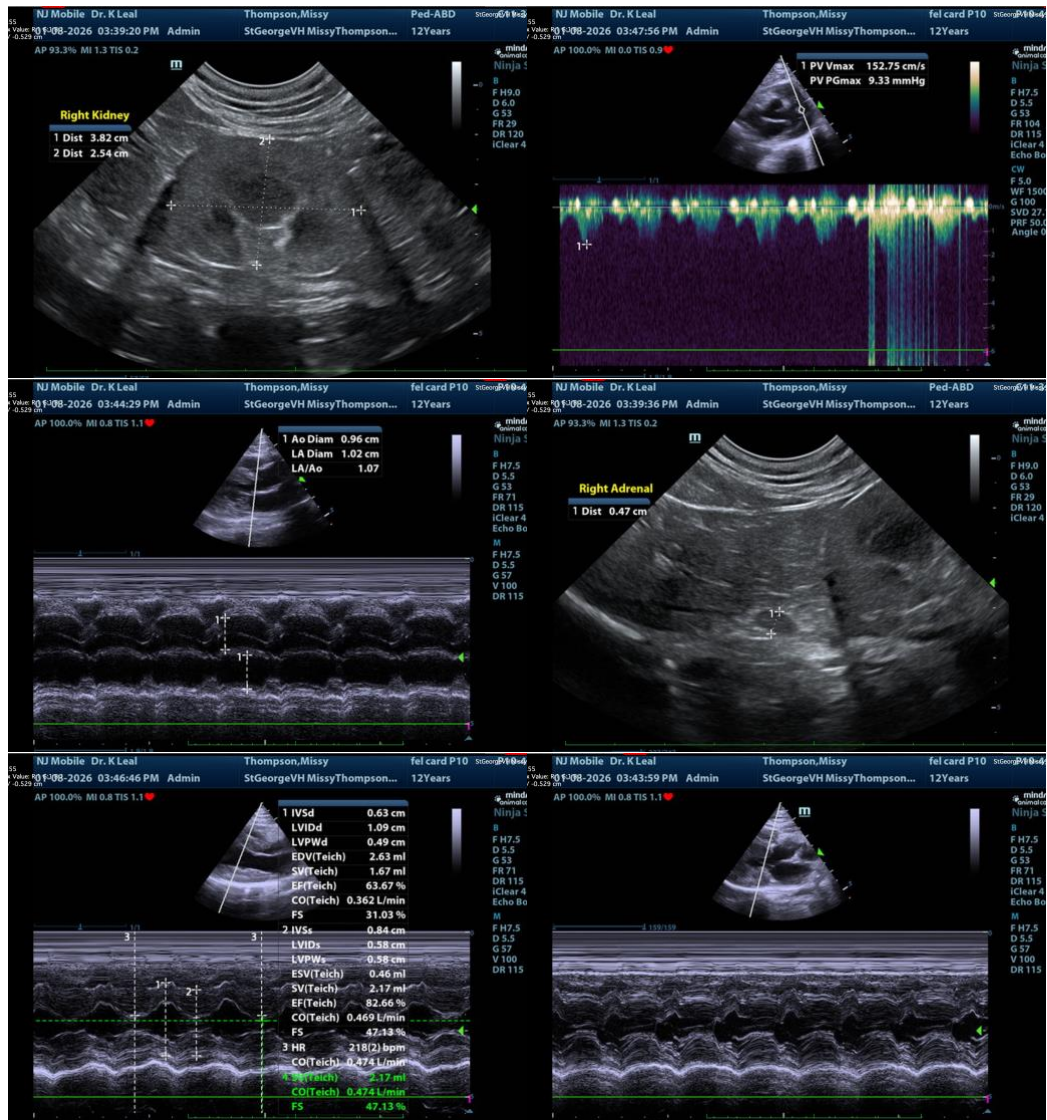
The base and limbs of the **pancreas** were observed to be largely isoechoic to surrounding omental fat. Pancreatic duct and capsular contour were acceptably normal and parenchyma respected normal curvilinear patterns. No overt evidence of active inflammatory or neoplastic disease was noted.

**ULTRASONOGRAPHIC FINDINGS**

- Normal echocardiogram with minor myocardial remodeling- no evidence of clinical disease.
- Moderate degenerative renal changes/nonspecific interstitial nephrosis pattern

**INTERPRETATION OF THE FINDINGS & FURTHER RECOMMENDATIONS**

No evidence of visceral disease. No contraindication to anesthetic procedures for a duration.





**PATIENT**

Missy Thompson

**SPECIES**

Feline

**BREED**

DSH

**SEX**

Spayed Female

**AGE**

12 Years

**WEIGHT**

15 Pounds

**INTERPRETED BY**

Eric Lindquist, DMV,  
 DABVP (Canine & Feline), Cert. IVUSS

**IMAGING PERFORMED BY**

Dr. Ken Leal

**HOSPITAL NAME**

St. Georges VH

**REFERRING VET**

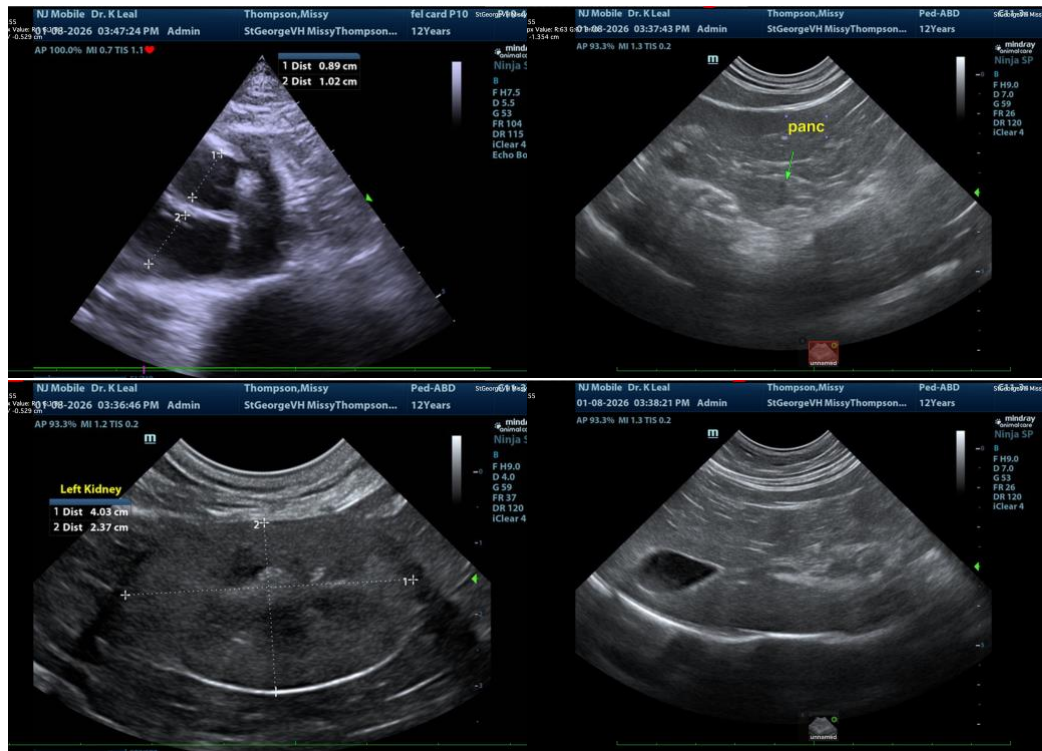
Dr. Patel

**INVOICE**

35304

**DATE**

1/8/26



The information and recommendations provided are based on the images presented by the referring veterinarian/sonographer. No evaluation can be communicated regarding pathology that was not visible in the image/video clips provided.

Thank you for this referral. If the clinical or image interpretation does not parallel your findings or if I can be of any further assistance please contact me.

**Eric Lindquist**, DMV, DABVP(CFM), Cert. IVUSS,  
 CEO, Owner, Founder -- SonoPath.com  
[info@SonoPath.com](mailto:info@SonoPath.com)