



PATIENT

Midgley Pfeifer

SPECIES

Canine

BREED

Boxer x

SEX

Spayed Female

AGE

8 Years

WEIGHT

63 lbs

INTERPRETED BY

Eric Lindquist, DMV,
DABVP (CFM), Cert.
IVUSS

IMAGING PERFORMED BY

Rebecca Hamilton

HOSPITAL NAME

Edgewood Animal
Clinic

REFERRING VET

Dr. Callahan

INVOICE

72093

DATE

1/8/26

PRESENTING CLINICAL SIGNS

ECG- Ventricular arrhythmia. Meds: Galliprant, Pre anes work up
Abnormal PE/Chem/CBC/UA Results: CBC- WNL, Chem: Creat 1.7, BUN 28, SDMA 18, T4 WNL, UA,
WNL, HR 160, RR 40, BP 117,- after sed w/ torb.

ULTRASONOGRAPHIC EXAMINATION OF THE HEART & ABDOMEN

CANINE CARDIAC PARAMETERS	MR VMAX (m/s)	TR VMAX (m/s)	LA/AO (M-Mode)	LA/AO (Heart Base; Swe)	FS (%)	EF (%)	EPSS (cm)
NORMAL PARAMETER	4.5-5.5	<2.7	1.3	Up to 1.6	28-40	40-100	<0.6
PATIENT	5.52	--	1.17	1.4	32	61	0.1
CANINE CARDIAC PARAMETERS	HR (BPM)	AV VMAX (m/s)	PV MAX (m/s)	BODY WEIGHT (lbs)	LAD LA MAX 4 Chamber	LVIDd Avg; 2D and m-mode short axis (cm)	LVIDs Avg; 2D and m-mode short axis (cm)
NORMAL PARAMETER	50-100	0.7-1.7	0.7-1.6				
PATIENT	123	5.0	1.39	63	3.6	3.18	--

Cardiac Presentation

The echocardiogram in this patient demonstrated normal **left atrial** size based on 3 separate methods of LA evaluation. Mitral insufficiency noted. The **left ventricle** presented thicknesses with linear contour and was not dilated nor restricted. The **myocardium** presented normal echogenicity without subjective evidence of significant fibrotic or ischemic disease. **Contractility** of the ventricular walls was adequate and in normal range for this patient evidenced by the fractional shortening measurement and subjective evaluation of the different regions of the myocardium. The **left ventricular outflow** tract demonstrated mild increased velocity at 3.17, not clinically significant. This could represent a minor form of subaortic stenosis, yet this is typical for the breed though slightly more elevated than a normal benign increased outflow velocity. The **right atrium** and auricle revealed normal size, structure and content. No evidence of masses was noted. **Tricuspid** valvular assessment demonstrated adequate linear morphology and kinesis. The **right ventricle** was of normal size (1/3 diameter of LV), chordae structure, myocardial echogenicity and thickness. **Pulmonary outflow** tract assessment revealed normal valve structure, laminar flow, and diameter (approx. 1:1 pa/ao ratio). No visible **pericardial** or free pleura fluid was noted. The cranial **mediastinum** and **pericardial** and **extra-cardiac** regions were free of masses in the visible window. Periodic arrhythmia noted in this patient.

Urinary System

The **urinary bladder**, trigone, and pelvic urethra presented normal thicknesses and normal tone. The ureters were not visible which is normal. No uroliths or sediment were visualized and anechoic urine was present. No evidence of inflammatory or neoplastic changes were noted. Ureteral papillae were normal. The pelvic urethra was imaged 2.0 cm beyond the cystourethral junction.



PATIENT

Midgley Pfeifer

The **left kidney** was significantly dystrophic. Minor pyelectasia, mineralization and infarcts noted.

The **right kidney** presented thickened, irregular cortices with pyelectasia. The right kidney measured 6.62 cm.

SPECIES

Canine

Adrenal Glands

Both **adrenal glands** were visualized and recognized as having normal shape, size, position and echogenicity for this breed. The phrenic vasculature, glandular echogenicity and detail were unremarkable. Capsule, cortex, and medullary definition were normal for this age patient. The left adrenal gland measured 1.98 cm x 0.57 cm at the cranial pole and 0.46 cm at the caudal pole. The right adrenal gland measured 2.22 cm x 0.60 cm at the cranial pole and 0.46 cm at the caudal pole.

BREED

Boxer x

SEX

Spayed Female

Spleen

The **spleen** presented a smooth homogeneous parenchyma hyperechoic to liver and renal cortical parenchyma. The capsule was smooth without noticeable expansion or deviation from within the spleen or adjacent pathology. The splenic vasculature demonstrated normal volume without signs of congestion or thrombosis. No sonographic evidence of acute or chronic inflammatory, neoplastic, or infarctual changes were noted.

AGE

8 Years

WEIGHT

63 lbs

Liver

The **liver** images submitted revealed subjectively normal liver size, contour, and structure. Parenchymal echogenicity was naturally coarse and hypoechoic to the spleen. Vascular and biliary tracts were of normal volume with no evidence of congestion. The gallbladder presented acceptably thin walls with primarily anechoic content. The cystic and common bile ducts were normal. No pathological hepatic lymphadenopathy was evident. No overt structural evidence of inflammatory, infiltrative or regenerative pathology was evident.

INTERPRETED BY

Eric Lindquist, DMV,
DABVP (CFM), Cert.
IVUSS

Gastrointestinal

Examination of the **gastrointestinal tract** revealed a stomach and intestine free of stasis, of normal wall thickness, acceptable curvilinear mural detail, and peristaltic activity. Small and large intestine demonstrated normal luminal chyme and stool consistency respectively. No obstructive or overt infiltrative disease was noted. No associated abnormal lymphatic activity was noted.

IMAGING PERFORMED BY

Rebecca Hamilton

Pancreas

The base and limbs of the **pancreas** were observed to be largely isoechoic to surrounding omental fat. Pancreatic duct and capsular contour were acceptably normal and parenchyma respected normal curvilinear patterns. No overt evidence of active inflammatory or neoplastic disease was noted.

HOSPITAL NAME

Edgewood Animal
Clinic

REFERRING VET

Dr. Callahan

ULTRASONOGRAPHIC FINDINGS

- Stage B1 valvular disease without volume overload.
- Mild increased LVOT velocity and aortic insufficiency.
- Dystrophic left kidney, mild to moderate degenerative right renal changes. I cannot rule out primary renal dysplasia with secondary degenerative changes.

INVOICE

72093

DATE

1/8/26

INTERPRETATION OF THE FINDINGS & FURTHER RECOMMENDATIONS

Full urinary workup recommended. I'm concerned for long-term viability of the kidneys in this patient. No cardiac dysfunction noted in this patient. However, significant arrhythmogenic activity noted. Blood



PATIENT

Midgley Pfeifer

SPECIES

Canine

BREED

Boxer x

SEX

Spayed Female

AGE

8 Years

WEIGHT

63 lbs

INTERPRETED BY

Eric Lindquist, DMV,
 DABVP (CFM), Cert.
 IVUSS

IMAGING PERFORMED BY

Rebecca Hamilton

HOSPITAL NAME

Edgewood Animal
 Clinic

REFERRING VET

Dr. Callahan

INVOICE

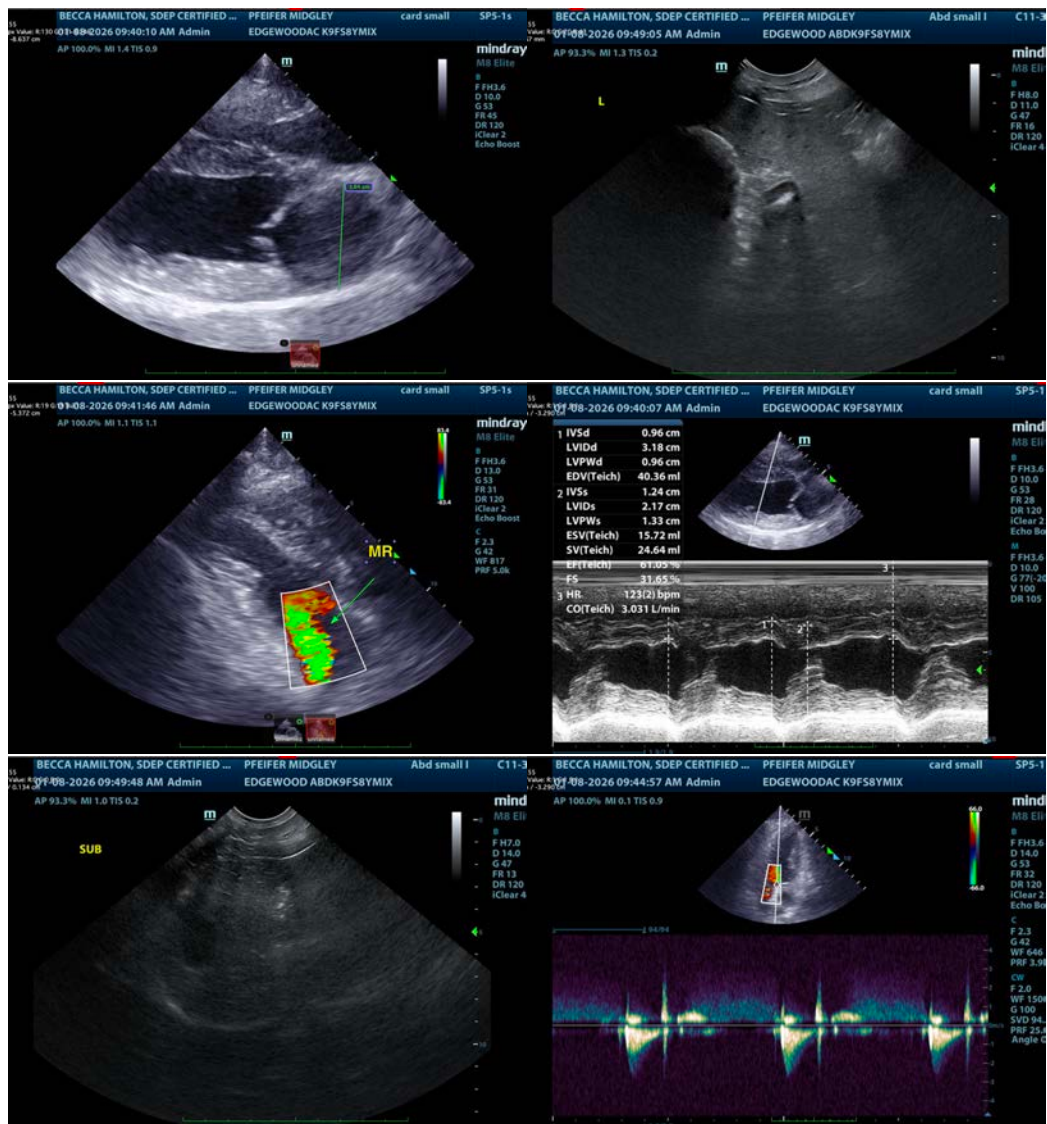
72093

DATE

1/8/26

pressure measurements and holter monitor indicated, which may be obtained from SonoPath's office with cardiologist review. No cardiac medications recommended at this time.

The heart is stable without clinical disease. No overt contraindication for anesthesia of brief to moderate duration. I suggest Torbutrol premed, Propofol induction, Isoflor maintenance or similar protocol if anesthesia is desired. Blood pressure, EKG and chest radiographs are recommended if not already performed. Target white coat negative systolic pressure of < 160 mmHg. If higher than this ACE-inhibitor is suggested to reach this level. Recheck echocardiogram is recommended in 6 months, earlier if murmur grade increases or clinical signs initiate.





PATIENT

Midgley Pfeifer

SPECIES

Canine

BREED

Boxer x

SEX

Spayed Female

AGE

8 Years

WEIGHT

63 lbs

INTERPRETED BY

Eric Lindquist, DMV,
 DABVP (CFM), Cert.
 IVUSS

IMAGING PERFORMED BY

Rebecca Hamilton

HOSPITAL NAME

Edgewood Animal
 Clinic

REFERRING VET

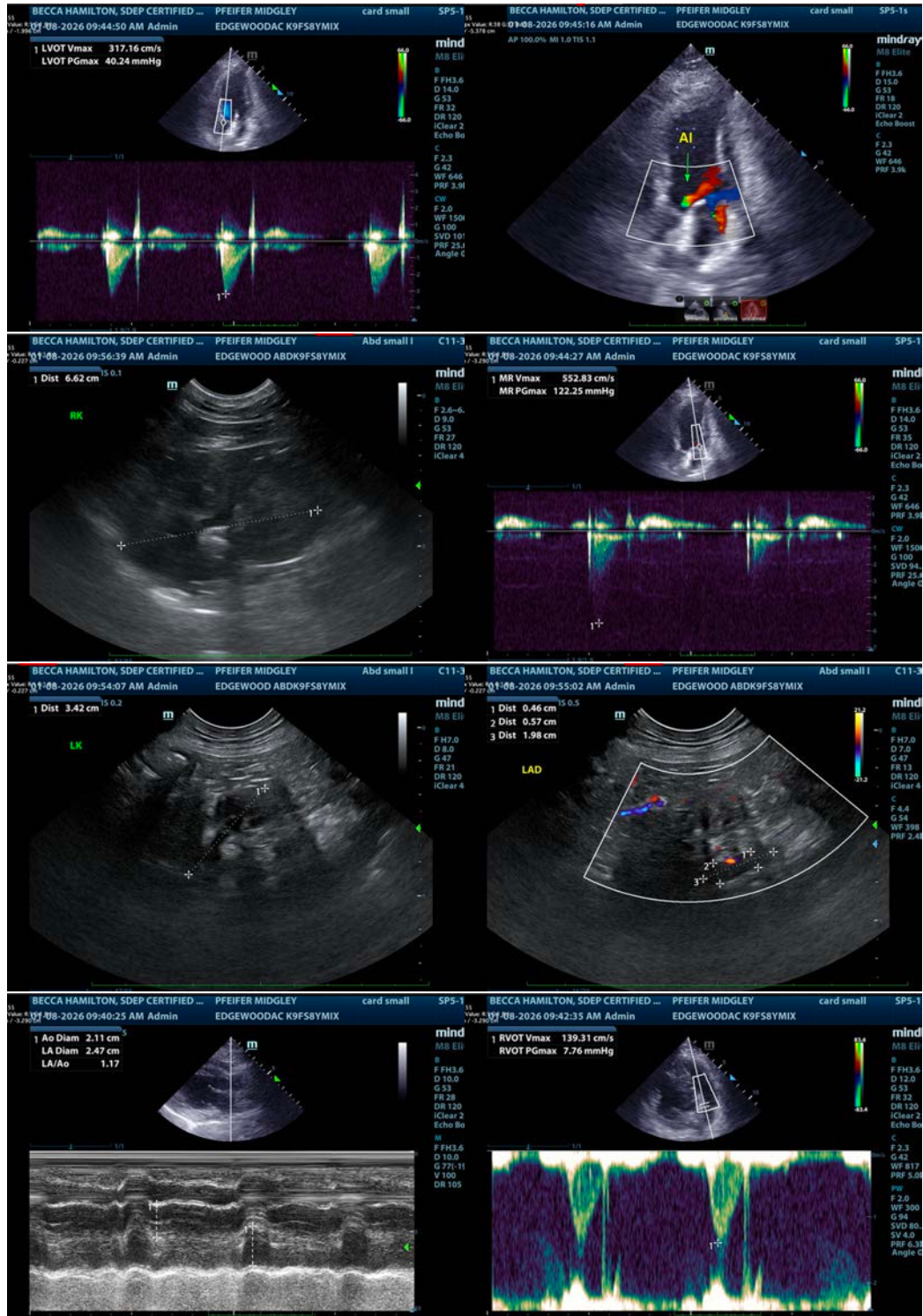
Dr. Callahan

INVOICE

72093

DATE

1/8/26





PATIENT

Midgley Pfeifer

SPECIES

Canine

BREED

Boxer x

SEX

Spayed Female

AGE

8 Years

WEIGHT

63 lbs

INTERPRETED BY

Eric Lindquist, DMV,
DABVP (CFM), Cert.
IVUSS

IMAGING PERFORMED BY

Rebecca Hamilton

HOSPITAL NAME

Edgewood Animal
Clinic

REFERRING VET

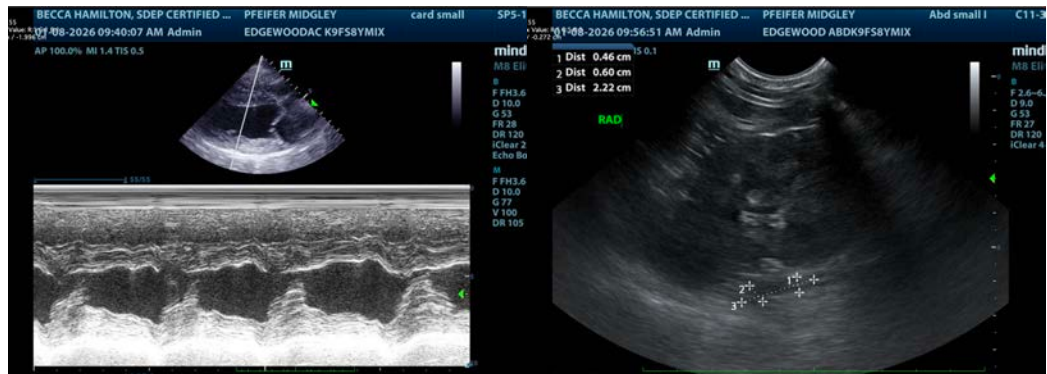
Dr. Callahan

INVOICE

72093

DATE

1/8/26



The information and recommendations provided are based on the images presented by the referring veterinarian/sonographer. No evaluation can be communicated regarding pathology that was not visible in the image/video clips provided.

Thank you for this referral. If the clinical or image interpretation does not parallel your findings or if I can be of any further assistance please contact me.

Eric Lindquist, DMV, DABVP(CFM), Cert. IVUSS,
CEO, Owner, Founder -- SonoPath.com
info@SonoPath.com