



PATIENT

Mac Langan

SPECIES

Canine

BREED

Lab Retriever

SEX

Neutered Male

AGE

10 Years 5 Months

WEIGHT

73.2 lbs

INTERPRETED BY

Eric Lindquist, DMV,
DABVP (CFM), Cert.
IVUSS

IMAGING PERFORMED BY

Vincent Ravancho, CVT

HOSPITAL NAME

Veterinary Wellness
Center (Glen Rock)

REFERRING VET

Dr. Sepulveda

INVOICE

72091

DATE

1/8/26

PRESENTING CLINICAL SIGNS

Mass removal R lateral Chest consistent soft tissue sarcoma

ULTRASONOGRAPHIC EXAMINATION OF THE ABDOMEN

Urinary System

The **urinary bladder**, trigone, and pelvic urethra presented normal thicknesses and normal tone. The ureters were not visible which is normal. No uroliths or sediment were visualized and anechoic urine was present. No evidence of inflammatory or neoplastic changes were noted. Ureteral papillae were normal. The pelvic urethra was imaged 2.0 cm beyond the cystourethral junction.

The residual prostate measured 5.0 mm.

The **kidneys** revealed largely normal size and structure, corticomedullary definition and ratio (cortex 1/3 of medulla) were essentially maintained with some age-related loss of curvilinear patterns regarding the capsule and C/M junction. The cortices presented largely uniform texture with some increased echogenicity expected for his age patient. Medullary structure differed distinctly from that of the cortex and no evidence of pelvic dilation was present. Left kidney measured 6.0 cm. Right kidney measured 6.0 cm.

Adrenal Glands

Both **adrenal glands** were visualized and recognized as having normal shape, size, position and echogenicity for this breed. The phrenic vasculature, glandular echogenicity and detail were unremarkable. Capsule, cortex, and medullary definition were normal for this age patient. Left measured 2.92 cm x 0.52 cm at the cranial pole and 0.53 cm at the caudal pole. Right measured 2.44 cm x 1.34 cm at the cranial pole and 0.39 cm at the caudal pole.

Spleen

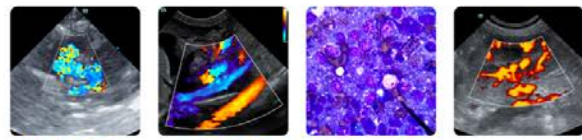
The **spleen** presented a smooth homogeneous parenchyma hyperechoic to liver and renal cortical parenchyma. The capsule was smooth without noticeable expansion or deviation from within the spleen or adjacent pathology. The splenic vasculature demonstrated normal volume without signs of congestion or thrombosis. No sonographic evidence of acute or chronic inflammatory, neoplastic, or infarctual changes were noted.

Liver

The **liver** presented coarse architecture and mild increased portal markings. The gallbladder and common bile duct were unremarkable.

Gastrointestinal

Examination of the **gastrointestinal tract** revealed a stomach and intestine free of stasis, of normal wall thickness, acceptable curvilinear mural detail, and peristaltic activity. Small and large intestine demonstrated normal luminal chyme and stool consistency respectively. No obstructive or overt infiltrative disease was noted. No associated abnormal lymphatic activity was noted.



PATIENT

Mac Langan

SPECIES

Canine

BREED

Lab Retriever

SEX

Neutered Male

AGE

10 Years 5 Months

WEIGHT

73.2 lbs

INTERPRETED BY

Eric Lindquist, DMV,
DABVP (CFM), Cert.
IVUSS

IMAGING PERFORMED BY

Vincent Ravancho, CVT

HOSPITAL NAME

Veterinary Wellness
Center (Glen Rock)

REFERRING VET

Dr. Sepulveda

INVOICE

72091

DATE

1/8/26

Pancreas

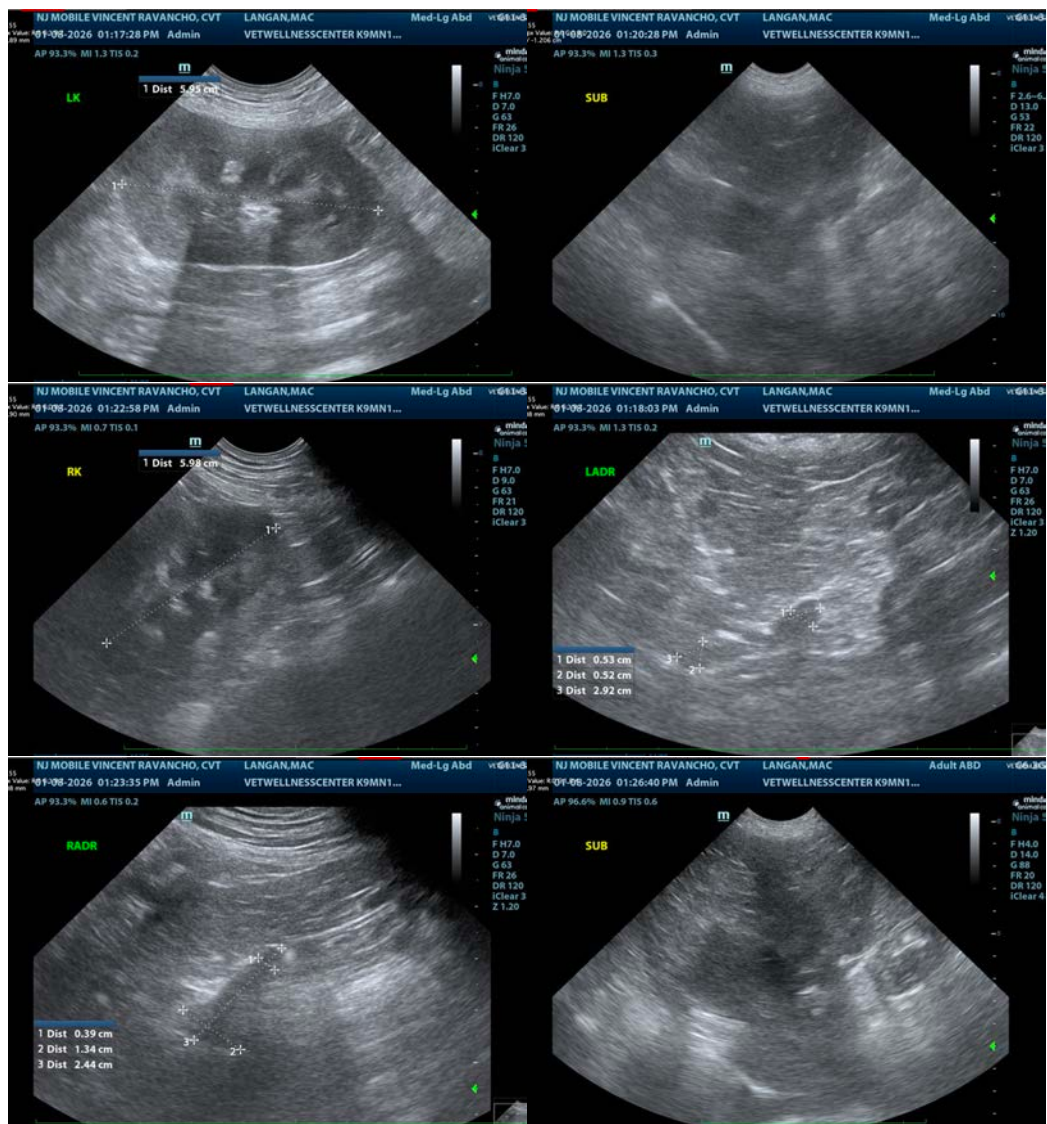
The base and limbs of the **pancreas** were observed to be largely isoechoic to surrounding omental fat. Pancreatic duct and capsular contour were acceptably normal and parenchyma respected normal curvilinear patterns. No overt evidence of active inflammatory or neoplastic disease was noted.

ULTRASONOGRAPHIC FINDINGS

- Largely age related changes.

INTERPRETATION OF THE FINDINGS & FURTHER RECOMMENDATIONS

No overt evidence of metastatic disease. I cannot rule out micrometastasis, yet no structural changes in the abdomen to suggest a neoplastic event.





PATIENT

Mac Langan

SPECIES

Canine

BREED

Lab Retriever

SEX

Neutered Male

AGE

10 Years 5 Months

WEIGHT

73.2 lbs

INTERPRETED BY

Eric Lindquist, DMV,
DABVP (CFM), Cert.
IVUSS

**IMAGING
PERFORMED BY**

Vincent Ravancho, CVT

HOSPITAL NAME

Veterinary Wellness
Center (Glen Rock)

REFERRING VET

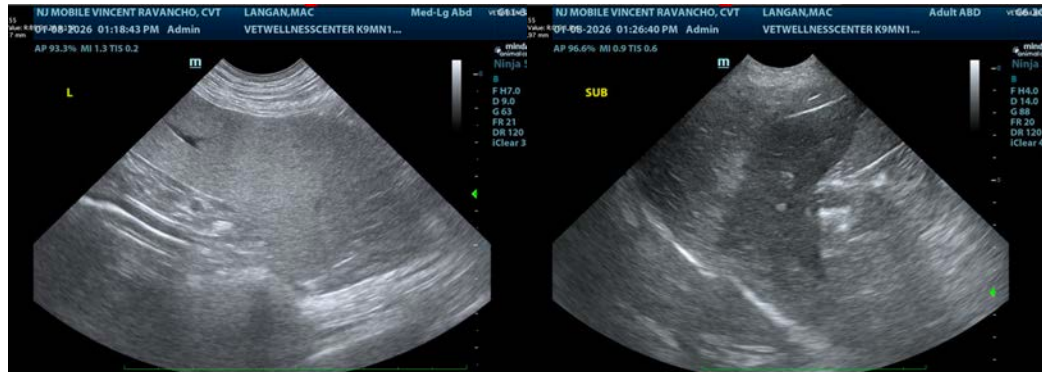
Dr. Sepulveda

INVOICE

72091

DATE

1/8/26



The information and recommendations provided are based on the images presented by the referring veterinarian/sonographer. No evaluation can be communicated regarding pathology that was not visible in the image/video clips provided.

Thank you for this referral. If the clinical or image interpretation does not parallel your findings or if I can be of any further assistance please contact me.

Eric Lindquist, DMV, DABVP(CFM), Cert. IVUSS,
CEO, Owner, Founder -- SonoPath.com
info@SonoPath.com