



PATIENT

Lucky Fryer

SPECIES

Canine

BREED

Mix

SEX

Neutered Male

AGE

10 Years

WEIGHT

63

INTERPRETED BY

Eric Lindquist, DMV,
DABVP (CFM), Cert.
IVUSS

IMAGING PERFORMED BY

Dr. Laura Klaassen

HOSPITAL NAME

Animal Care Group of
Lake Oswego

REFERRING VET

Dr. Laura Klaassen

INVOICE

72079

DATE

1/8/26

PRESENTING CLINICAL SIGNS

Acute onset blindness - mild hypertension started benazepril
Abnormal PE/Chem/CBC/UA Results: All normal

ULTRASONOGRAPHIC EXAMINATION OF THE ABDOMEN

Urinary System

The **urinary bladder**, trigone, and pelvic urethra presented normal thicknesses and normal tone. The ureters were not visible which is normal. No uroliths or sediment were visualized and anechoic urine was present. No evidence of inflammatory or neoplastic changes were noted. Ureteral papillae were normal. The pelvic urethra was imaged 2.0 cm beyond the cystourethral junction.

The **kidneys** revealed largely normal size and structure, corticomedullary definition and ratio (cortex 1/3 of medulla) were essentially maintained with some age-related loss of curvilinear patterns regarding the capsule and C/M junction. The cortices presented largely uniform texture with some increased echogenicity expected for his age patient. Medullary structure differed distinctly from that of the cortex and no evidence of pelvic dilation was present. Mineralization noted in both kidneys. The left kidney measures 6.3 cm. The right kidney measured 5.7 cm.

Adrenal Glands

The **right adrenal gland** was visualized and recognized as having normal shape, size, position and echogenicity for this breed. The phrenic vasculature, glandular echogenicity and detail were unremarkable. Capsule, cortex, and medullary definition were normal for this age patient. Right measures 0.50 cm at the caudal pole and 0.80 cm at the cranial pole.

The **left adrenal gland** was mildly swollen at 0.82 cm at the caudal pole and 0.70 cm at the cranial pole.

Spleen

The **spleen** presented discrete and diffuse hypoechoic micronodular parenchyma. The capsule was generally smooth without noticeable impingement from within the spleen or from pathology in the adjacent abdomen. The splenic vasculature demonstrated normal volume without signs of congestion or significant contraction. These changes are consistent with age related benign nodular hyperplasia. However, early hemangiosarcoma, lymphoma or mast cell neoplasia could not be entirely ruled out. Fine needle aspirate or biopsy following coagulation panel would be ideal especially if any weight loss is an issue. Otherwise, follow up ultrasound in 3-4 weeks to track these changes would be a more conservative approach.

Liver

The **liver** images submitted revealed subjectively normal liver size, contour, and structure. Parenchymal echogenicity was naturally coarse and hypoechoic to the spleen. Vascular and biliary tracts were of normal volume with no evidence of congestion. The gallbladder presented acceptably thin walls with primarily anechoic content. The cystic and common bile ducts were normal. No pathological hepatic lymphadenopathy was evident. No overt structural evidence of inflammatory, infiltrative or regenerative pathology was evident.



PATIENT

Lucky Fryer

SPECIES

Canine

BREED

Mix

SEX

Neutered Male

AGE

10 Years

WEIGHT

63

INTERPRETED BY

Eric Lindquist, DMV,
DABVP (CFM), Cert.
IVUS

IMAGING PERFORMED BY

Dr. Laura Klaassen

HOSPITAL NAME

Animal Care Group of
Lake Oswego

REFERRING VET

Dr. Laura Klaassen

INVOICE

72079

DATE

1/8/26

Gastrointestinal

There was some residual chyme and gas was noted in the **stomach**, yet not pathological. This is consistent with end post prandial presentation. Transit of chyme into the small intestine was normal. Curvilinear patterns were maintained throughout the GI tract. No evidence of pathology. Small and large intestine demonstrated normal luminal chyme and stool consistency respectively. No obstructive or overt infiltrative disease was noted. No associated abnormal lymphatic activity was noted.

Pancreas

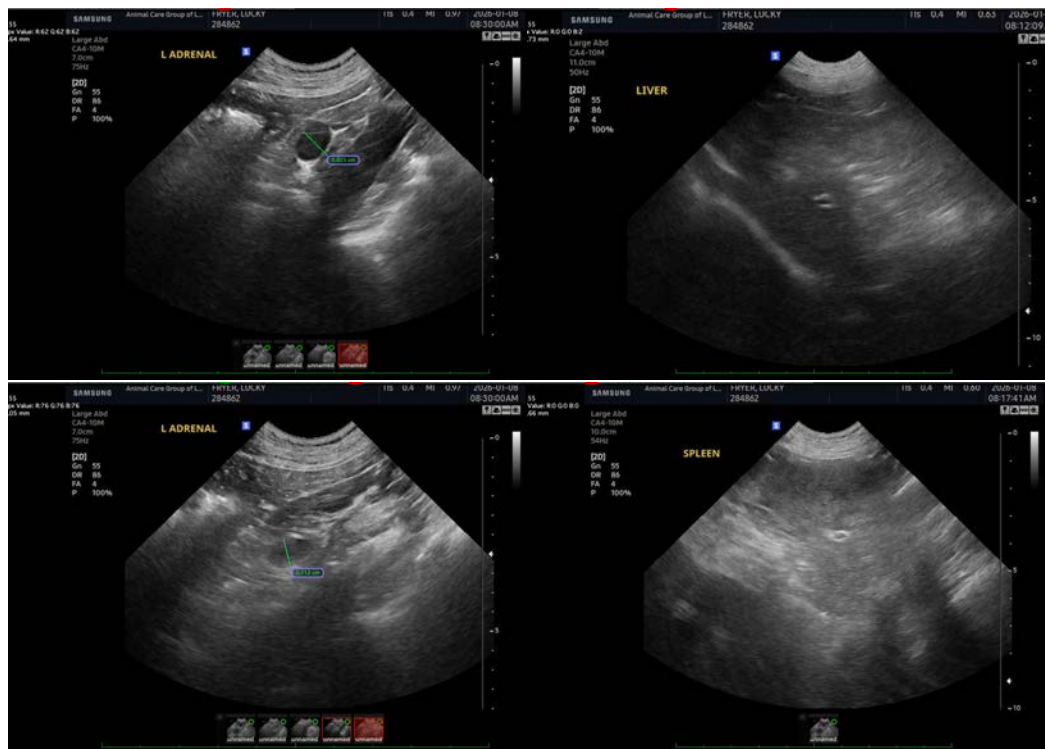
The base and limbs of the **pancreas** were observed to be largely isoechoic to surrounding omental fat. Pancreatic duct and capsular contour were acceptably normal and parenchyma respected normal curvilinear patterns. No overt evidence of active inflammatory or neoplastic disease was noted.

ULTRASONOGRAPHIC FINDINGS

- Mildly swollen left adrenal gland.
- Hypoechoic, micronodular spleen.
- Age related renal changes.
- Partially full stomach.

INTERPRETATION OF THE FINDINGS & FURTHER RECOMMENDATIONS

Structurally unremarkable abdomen other than the mildly swollen left adrenal gland. The cause of hypertension is unclear. There could be an argument for potential emerging PDH/Cushing's if clinical parameters are present such as isosthenuria and elevated UCCR.





PATIENT

Lucky Fryer

SPECIES

Canine

BREED

Mix

SEX

Neutered Male

AGE

10 Years

WEIGHT

63

INTERPRETED BY

Eric Lindquist, DMV,
DABVP (CFM), Cert.
IVUSS

IMAGING PERFORMED BY

Dr. Laura Klaassen

HOSPITAL NAME

Animal Care Group of
Lake Oswego

REFERRING VET

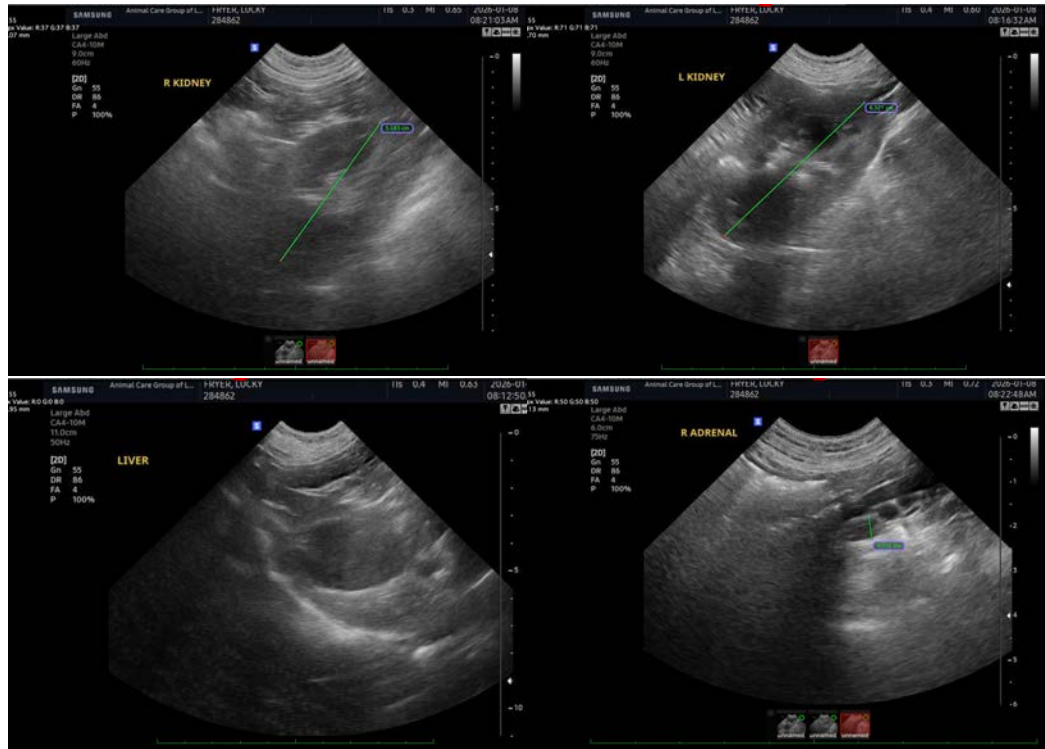
Dr. Laura Klaassen

INVOICE

72079

DATE

1/8/26



The information and recommendations provided are based on the images presented by the referring veterinarian/sonographer. No evaluation can be communicated regarding pathology that was not visible in the image/video clips provided.

Thank you for this referral. If the clinical or image interpretation does not parallel your findings or if I can be of any further assistance please contact me.

Eric Lindquist, DMV, DABVP(CFM), Cert. IVUSS,
CEO, Owner, Founder -- SonoPath.com
info@SonoPath.com