



PATIENT

Hunter Haber

SPECIES

Canine

BREED

Mix

SEX

Neutered Male

AGE

10 Years

WEIGHT

18.1 Pounds

INTERPRETED BY

Eric Lindquist, DMV,
DABVP (CFM), Cert.
IVUSS

IMAGING PERFORMED BY

Dr. Barnea

HOSPITAL NAME

Tenaflly VC

REFERRING VET

Dr. Barnea

INVOICE

35309

DATE

1/8/26

PRESENTING CLINICAL SIGNS

History: gb dz,gb was removed last year persistent elevation of liver enzyme a/lT around 500 hx of chronic low grade pancreatitis,under control now pet will only eat i/d refused ha or elementary or z/d been for 30 days on enrofloxacin and doxy but enzyme stayed the same repeat us and liver cytology done to day.

**6 still imaged and 5 videos submitted.

LIMITED ULTRASONOGRAPHIC EXAMINATION

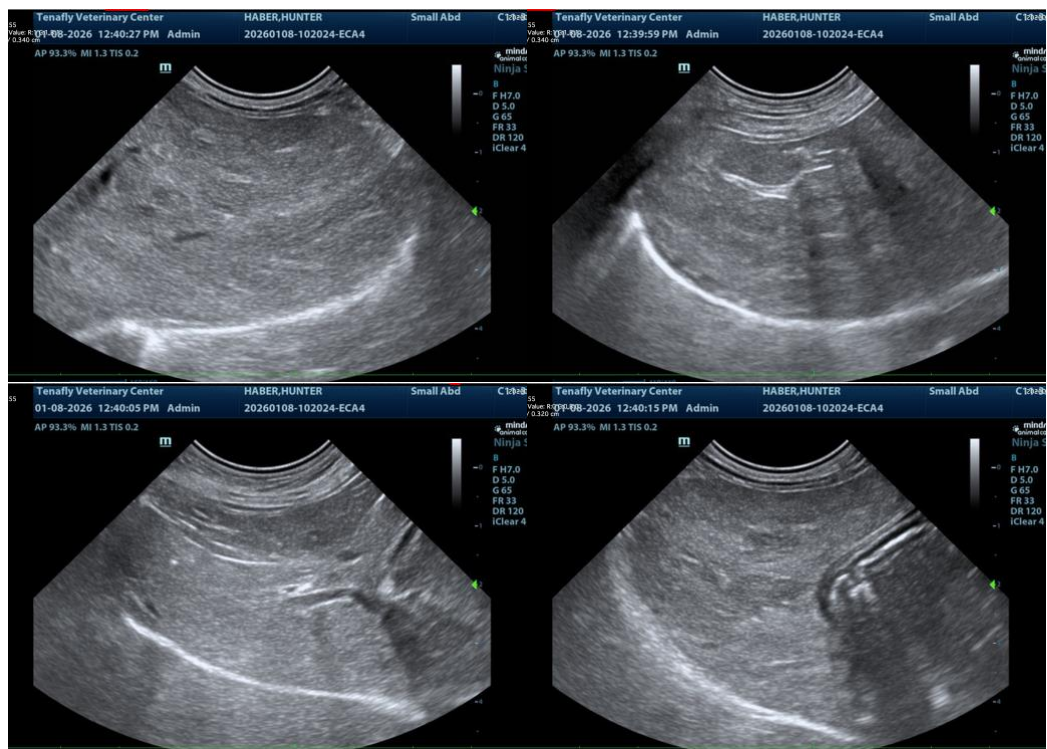
The **liver** revealed mild uniform enlargement, increased portal markings, and multifocal hypoechoic nodular changes. No residual pathology from the prior gallbladder removal surgery. No evidence of masses.

ULTRASONOGRAPHIC FINDINGS

- Nodular hyperplasia liver pattern with some remodeling.

INTERPRETATION OF THE FINDINGS & FURTHER RECOMMENDATIONS

Bile acid profile is warranted. No suspicion of neoplasia was noted. FNA of the liver is warranted for further definition of inflammatory cell type.



The information and recommendations provided are based on the images presented by the referring veterinarian/sonographer. No evaluation can be communicated regarding pathology that was not



PATIENT

Hunter Haber

SPECIES

Canine

BREED

Mix

SEX

Neutered Male

AGE

10 Years

WEIGHT

18.1 Pounds

INTERPRETED BY

Eric Lindquist, DMV,
DABVP (CFM), Cert.
IVUSS

IMAGING PERFORMED BY

Dr. Barnea

HOSPITAL NAME

Tenaflly VC

REFERRING VET

Dr. Barnea

INVOICE

35309

DATE

1/8/26

visible in the image/video clips provided.

Thank you for this referral. If the clinical or image interpretation does not parallel your findings or if I can be of any further assistance please contact me.

Eric Lindquist, DMV, DABVP(CFM), Cert. IVUSS,
CEO, Owner, Founder -- SonoPath.com
info@SonoPath.com