



PATIENT

Elf Kibuye

SPECIES

Feline

BREED

DSH

SEX

Neutered Male

AGE

16

WEIGHT

11.9

INTERPRETED BY

Eric Lindquist, DMV,
DABVP(CFM), Cert.
IVUSS

IMAGING PERFORMED BY

Susan Lincoski VMD

HOSPITAL NAME

University Drive
Veterinary Hospital

REFERRING VET

Dr. Lincoski

INVOICE

13011

DATE

01/08/2026

PRESENTING CLINICAL SIGNS

Senior patient with noted grade II/V murmur at annual 11/25. BNP was mildly elevated at 148. Radiographs showed mild enlargement of cardiac silhouette.

Abnormal PE/Chem/CBC/UA Results: Severe dental disease BNP=148 SDMA=15 BUN=43 CREA=1.8 T4=2.2 URINE SG=1.021 with inactive sediment and pH=5.5

ULTRASONOGRAPHIC EXAMINATION OF THE HEART

| FELINE CARDIAC PARAMETERS | BODY WEIGHT | HR (BPM) | IVSd (cm) | LVIDd (cm) | LVWd (cm) | FS (%) | EF (%) |
|---|----------------|---------------------------|----------------------|------------|-----------------|-----------------|-----------|
| NORMAL PARAMETER | ----- | 150-240 | 0.3-0.6 | 1.0-2.1 | 0.25-0.6 | 35-67 | 80-100 |
| PATIENT | 11.9 | 180 | 0.45 | 1.11 | 0.42 | 58 | 91 |
| FELINE CARDIAC PARAMETERS | LA/AO (M-mode) | LA/AO HEART BASE (Sisson) | LAD LA MAX 4 Chamber | | LVOT VEL. (m/s) | RVOT VEL. (m/s) | IVRT (m/) |
| NORMAL PARAMETER | <1.5 | 1.6 | 0.7-1.7 | | <1.6 | <1.3 | 40-60 |
| PATIENT | 1.3 | 1.3 | 1.3 | | -- | -- | NM |
| Adapted from June Boon, Veterinary Echocardiography, 1998 | | | | | | | |
| Sisson D et al. JVIM 1991; 5: 232, Jacobs et al. Am J Vet Res 1985; 46:1705 | | | | | | | |

EPSS: 0.1

Cardiac Presentation

The echocardiogram in this patient demonstrated normal **left atrial** size based on 3 separate LA measurements. The cranial and caudal **mitral** valve leaflets presented normal linear structure and kinetics. The **left ventricle** presented normal thicknesses with linear contour and was not dilated nor restricted. The **myocardium** presented normal echogenicity without subjective evidence of significant fibrotic or ischemic disease. **Contractility** of the ventricular walls was adequate and in normal range for this patient evidenced by the fractional shortening measurement and subjective evaluation of the different regions and angles of the myocardium. The **left ventricular outflow** tract demonstrated normal laminar flow and subjective structural integrity. The **right atrium** and auricle revealed normal size, structure and content. No evidence of masses was noted or chamber overload. Trivial **tricuspid** insufficiency was noted in this patient. The **right ventricle** was of normal size (1/3 diameter of LV), chordae structure, myocardial echogenicity and thickness. **Pulmonic** tract assessment revealed normal valve structure, laminar flow, and diameter (approx. 1:1 pa/ao ratio). No visible **pericardial** or free pleura fluid was noted or extra cardiac pathology in the visible planes. The cranial **mediastinum and pericardial regions** were free of masses in the visible window.

ULTRASONOGRAPHIC FINDINGS

- Normal echocardiogram with trivial tricuspid insufficiency.



PATIENT

Elf Kibuye

SPECIES

Feline

BREED

DSH

SEX

Neutered Male

AGE

16

WEIGHT

11.9

INTERPRETED BY

Eric Lindquist, DMV,
DABVP(CFM), Cert.
IVUSS

IMAGING PERFORMED BY

Susan Lincoski VMD

HOSPITAL NAME

University Drive
Veterinary Hospital

REFERRING VET

Dr. Lincoski

INVOICE

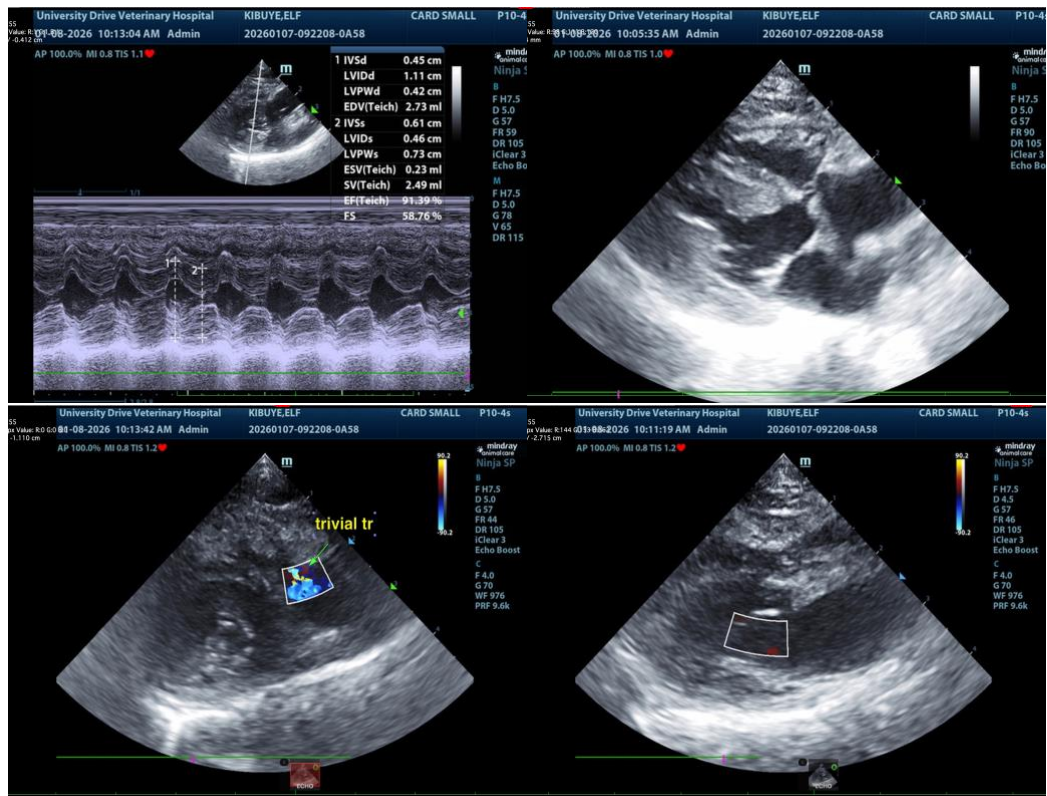
13011

DATE

01/08/2026

INTERPRETATION OF THE FINDINGS & FURTHER RECOMMENDATIONS

No contraindication for anesthetic procedures if needed. The murmur may be exacerbated by volume contraction issues if systemic disease is present. No evidence of structural or functional disease.



The information and recommendations provided are based on the images presented by the referring veterinarian/sonographer. No evaluation can be communicated regarding pathology that was not visible in the image/video clips provided.

Thank you for this referral. If the clinical or image interpretation does not parallel your findings or if I can be of any further assistance, please contact me.

Eric Lindquist, DMV, DABVP(CFM), Cert. IVUSS,

CEO, Owner, Founder -- SonoPath.com

info@SonoPath.com