



**PATIENT**

Hazyl Meldrum

**SPECIES**

Canine

**BREED**

Pitbull Mix

**SEX**

Spayed Female

**AGE**

10

**WEIGHT**

46.1

**INTERPRETED BY**

Eric Lindquist, DMV  
DABVP, Cert. IVUSS

**IMAGING PERFORMED BY**

Sarah Green

**HOSPITAL NAME**

Healing Spirit AW

**REFERRING VET**

Sarah Green

**INVOICE**

20487

**DATE**

1/8/23

**PRESENTING CLINICAL SIGNS**

History: Multi focal SCC on the ventral abdomen. Lesions recently excised surgically. Ultrasound performed to evaluate for evidence of metastasis prior to ECT

Abnormal PE/Chem/CBC/UA Results: No significant exam or laboratory findings.

**ULTRASONOGRAPHIC EXAMINATION OF THE ABDOMEN**

**Urinary System**

The **urinary bladder**, trigone, and pelvic urethra presented normal thicknesses and normal tone. The ureters were not visible which is normal. No uroliths or sediment were visualized, and anechoic urine was present. No evidence of inflammatory or neoplastic changes were noted. Ureteral papillae were normal. The pelvic urethra was imaged 1.0 cm beyond the cystourethral junction.

The **kidneys** revealed normal size and structure, corticomedullary definition and ratio for this age. The cortices presented largely uniform texture with normal echogenic relationship to liver and spleen. Medullary structure differed distinctly from the cortex. The capsules were acceptably uniform without significant irregularities. Slight pyelectasia was noted in the right kidney. Both kidneys measured 6.0 cm.

**Adrenal Glands**

The **right adrenal gland** was visualized and recognized as having normal shape, size, position and echogenicity for this breed. The phrenic vasculature, glandular echogenicity and detail were unremarkable. Capsule, cortex, and medullary definition were normal for this age patient. The right adrenal gland measured 0.5 cm.

The region of the **left adrenal gland** was imaged and revealed no evident pathology.

**Spleen**

The **spleen** presented a smooth homogeneous parenchyma hyperechoic to liver and renal cortical parenchyma. The capsule was smooth without noticeable expansion or deviation from within the spleen or adjacent pathology. The splenic vasculature demonstrated normal volume without signs of congestion or thrombosis. No sonographic evidence of acute or chronic inflammatory, neoplastic, or infarctual changes were noted. Cranial folding of the spleen was noted, uniform.

**Liver**

The **liver** images from right and left intercostal as well as subcostal views revealed subjectively normal liver size, contour, and structure. Some mild age-related parenchymal remodeling was noted but likely not clinically significant at this time. Vascular and biliary tracts were of normal volume and no evidence of congestion was noted. The gallbladder presented some dependent debris with essentially normal contour. The cystic and common bile ducts were normal. No overt evidence of active inflammatory, infiltrative or regenerative pathology was noted but should be paired with current or past LE elevations regarding any clinical significance to this presentation. The hepatic lymph nodes were unremarkable.

**Gastrointestinal**

Examination of the **gastrointestinal tract** revealed a stomach and intestine free of stasis, of normal wall thickness, acceptable curvilinear mural detail, and peristaltic activity. Small and large intestine



**PATIENT**

Hazyl Meldrum

demonstrated normal luminal chyme and stool consistency respectively. No obstructive or overt infiltrative disease was noted. No associated abnormal lymphatic activity was noted.

**Pancreas**

**SPECIES**

Canine

The base and limbs of the **pancreas** were observed to be largely isoechoic to surrounding omental fat. Pancreatic duct and capsular contour were acceptably normal and parenchyma respected normal curvilinear patterns. No overt evidence of active inflammatory or neoplastic disease was noted.

**BREED**

Pitbull Mix

**ULTRASONOGRAPHIC FINDINGS**

- Structurally unremarkable abdomen
- Age-related hepatic changes
- Splenic fold, uniform

**SEX**

Spayed Female

**INTERPRETATION OF THE FINDINGS & FURTHER RECOMMENDATIONS**

No evidence of primary or metastatic pathology.

**AGE**

10

**WEIGHT**

46.1

**INTERPRETED BY**

Eric Lindquist, DMV  
DABVP, Cert. IVUSS

**IMAGING PERFORMED BY**

Sarah Green

**HOSPITAL NAME**

Healing Spirit AW

**REFERRING VET**

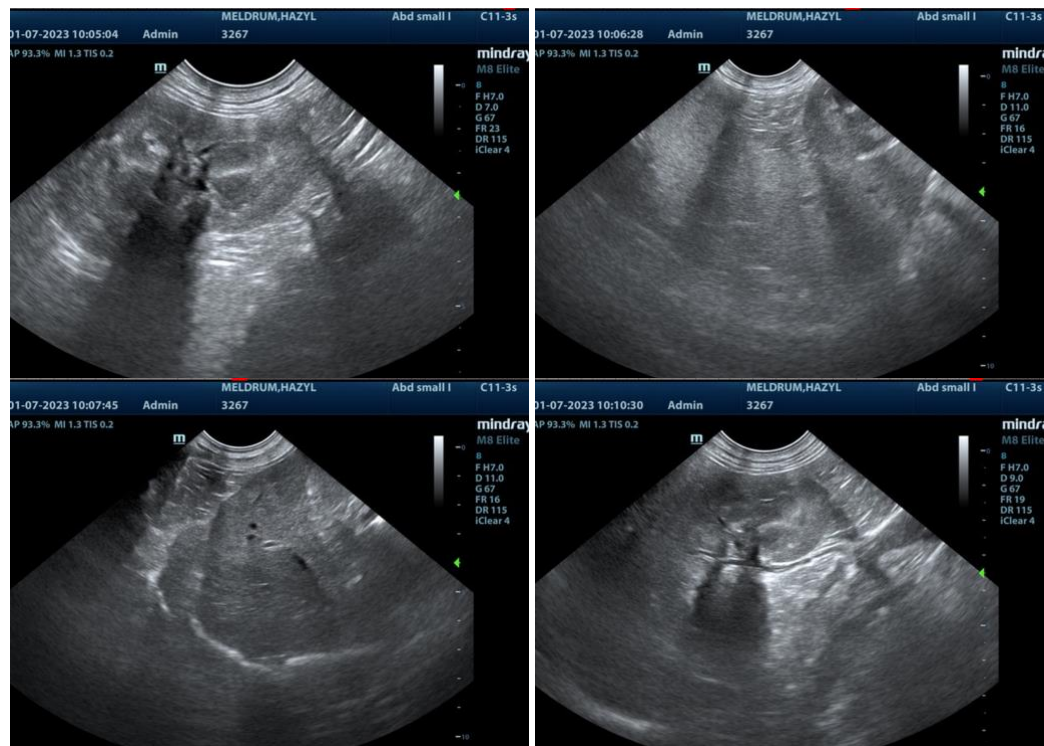
Sarah Green

**INVOICE**

20487

**DATE**

1/8/23





**PATIENT**

Hazyl Meldrum

**SPECIES**

Canine

**BREED**

Pitbull Mix

**SEX**

Spayed Female

**AGE**

10

**WEIGHT**

46.1

**INTERPRETED BY**

Eric Lindquist, DMV  
DABVP, Cert. IVUSS

**IMAGING PERFORMED BY**

Sarah Green

**HOSPITAL NAME**

Healing Spirit AW

**REFERRING VET**

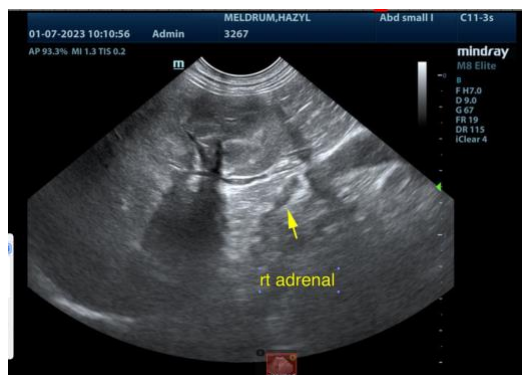Sarah Green

**INVOICE**

20487

**DATE**

1/8/23



The information and recommendations provided are based on the images presented by the referring veterinarian. No evaluation can be communicated regarding pathology that was not visible in the image/video clips provided.

Thank you for this referral. If the clinical or image interpretation does not parallel your findings or if I can be of any further assistance please contact me.

**Eric Lindquist**, DMV, DABVP, Cert. IVUSS, CEO of SonoPath.com  
info@SonoPath.com