

**DATE**

1/7/22

PRESENTING CLINICAL SIGNS**PATIENT**

Wellington Heinlein

History: History: Presenting Complaint: Vomiting, Not Eating, Bloody Diarrhea Date: 01-06-2022 Notes: Today P started having vomiting, diarrhea, and lethargy, O tried to give P some water and P drank it but then vomited back up today. P has not been interested in food or water.

SPECIES

Canine

Current Medications: Buprenex, Acepromazine, Unasyn, Pantoprazole.

Lab Results: Attached separately.

Radiographs: Repeat lat abdomen- stomach has emptied, no obvious obstruction, concern for splenomegaly.

Date of Previous IntraPet Ultrasound: No previous IntraPet scans.

Sedation: Not required to complete full diagnostic ultrasound.

Stat Report: Not requested.

BREEDLabrador Retriever
Mix

Imaging Performed By: Rachel Brillhart, RDMS.

SEX

Neutered Male

ULTRASONOGRAPHIC EXAMINATION OF THE ABDOMEN**AGE**

1/6/15

Urinary System

The **urinary bladder**, trigone, and pelvic urethra presented normal thicknesses and normal tone. The ureters were not visible which is normal. No uroliths or sediment were visualized and anechoic urine was present. No evidence of inflammatory or neoplastic changes were noted. Ureteral papillae were normal. The residual prostate was uniform, measuring 1.58 cm.

WEIGHT

44.6 Lbs.

The **kidneys** revealed normal size and structure, corticomedullary definition and ratio for this age. The cortices presented largely uniform texture with normal echogenic relationship to liver and spleen. Medullary structure differed distinctly from the cortex and no evidence of pelvic dilation was present. The capsules were acceptably uniform without significant irregularities. The right kidney measured 5.34 cm. The left kidney measured 5.58 cm.

INTERPRETED BYEric Lindquist, DMV
DABVP, Cert. IVUSS**Adrenal Glands**

Both **adrenal glands** were visualized and recognized as having normal shape, size, position and echogenicity for this breed. The phrenic vasculature, glandular echogenicity and detail were unremarkable. Capsule, cortex, and medullary definition were normal for this age patient. The right adrenal gland measured 2.98 cm x 0.56 cm at the caudal pole and 0.78 cm at the cranial pole. The left adrenal gland measured 2.96 cm x 0.5 cm at the caudal pole and 0.52 cm at the cranial pole.

HOSPITAL NAME

Animal Emergency H

Spleen

The **spleen** was uniformly enlarged with relatively uniform parenchyma without evidence of masses. The capsule was mildly swollen. This is most consistent with mild hypersplenism and reactive hyperplasia deriving from splenic white or red pulp. However, early infiltrative disease, such as lymphoma or mast cell neoplasia can, at times, present in this manner but not suspected. 25g US-guided FNA would be best in order to ensure only reactive hyperplasia is present. If clinical signs fit with potential neoplasia or mast cell disease, then Benadryl injection (1 mg/pound IM) 15 minutes prior to FNA would be recommended. Caudal folding of the spleen was noted.

REFERRING VET

Dr. Roper

INVOICE

13321

Liver

The **liver** images submitted revealed subjectively normal liver size, contour, and structure. Parenchymal echogenicity was naturally coarse and hypoechoic to the spleen. Vascular and biliary tracts were of normal volume with no evidence of congestion. The gallbladder presented acceptably thin walls with primarily anechoic content. The cystic and common bile ducts were normal. No pathological hepatic lymphadenopathy was evident. No overt structural evidence of inflammatory, infiltrative or regenerative pathology was evident.

Gastrointestinal

The **gastrointestinal** presentation revealed mild uniform prominence of the gastric mucosa as well as areas of "ropy" small intestinal wall with slight disruption of the normal 1:3 muscularis/mucosal ratio. The intestinal submucosa was slightly irregular, thickened and hyperechoic suggestive of low grade, chronic disease. No concerning lymphadenopathy was visible. No evidence of obstruction was present. Mild Chronic inflammatory bowel disease is likely with a low possibility of an early neoplastic event such as lymphoma. Full thickness tissue biopsies via open laparotomy, ideally guided by intraoperative ultrasound in order to obtain the most representative mural sample, would be necessary to rule out this possibility.

Pancreas

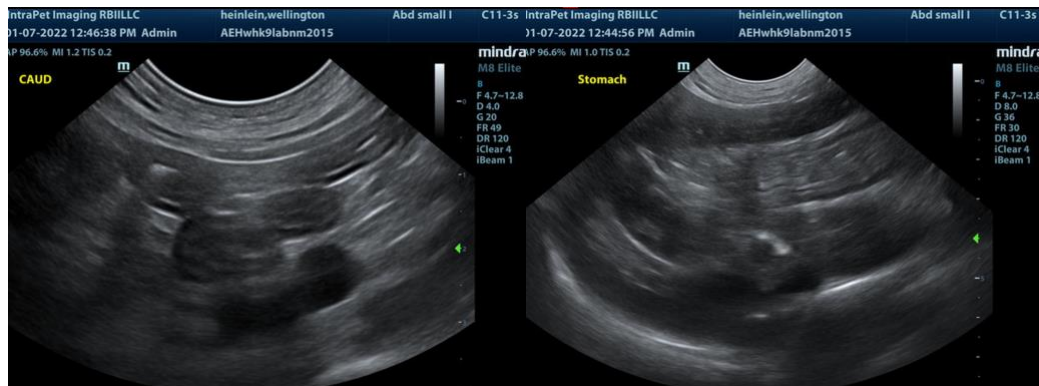
The base and limbs of the **pancreas** were observed to be largely isoechoic to surrounding omental fat. Pancreatic duct and capsular contour were acceptably normal and parenchyma respected normal curvilinear patterns. No overt evidence of active inflammatory or neoplastic disease was noted.

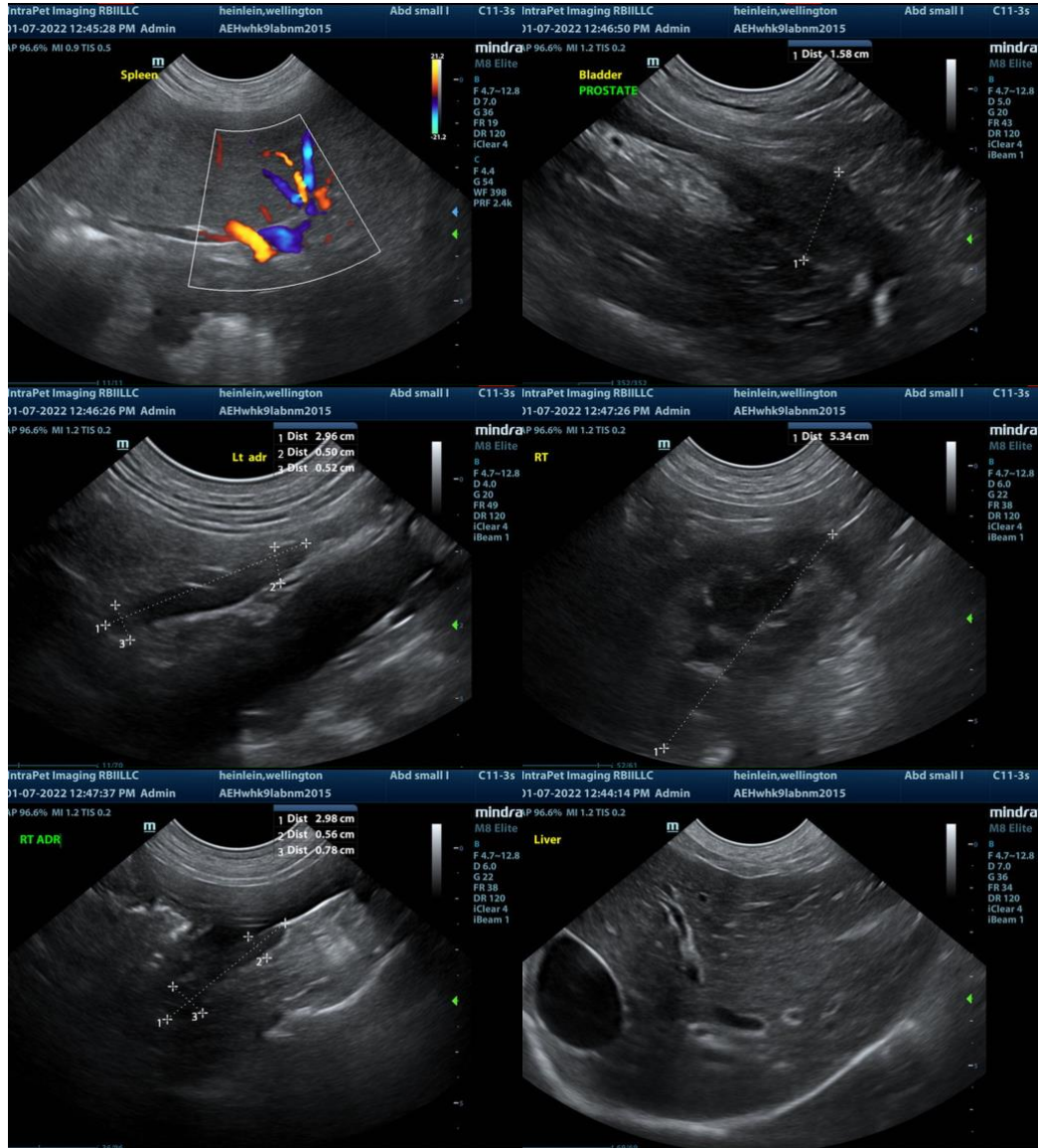
ULTRASONOGRAPHIC FINDINGS

- Hypersplenism, not likely clinically significant
- Mild IBD GI pattern. No evidence of foreign body or neoplasia

INTERPRETATION OF THE FINDINGS & FURTHER RECOMMENDATIONS

No other evidence of pathology appears responsible for the clinical signs. Palpation of the spleen recommended. If discomfort is noted, then proactive splenectomy could be considered yet no active inflammation present. If splenectomy, core GI biopsies could be considered. However, structurally the abdomen appears benign. GI support warranted and assessment for other causes of the clinical signs. Dietary indiscretion, food intolerance, structurally insignificant inflammatory bowel or occult parasitism and occult Addison's are all potentials.





The information and recommendations provided are based on the images presented by the referring veterinarian. No evaluation can be communicated regarding pathology that was not visible in the image/video clips provided.

Thank you for this referral. If the clinical or image interpretation does not parallel your findings or if I can be of any further assistance please contact me.

Eric Lindquist, DMV, DABVP, Cert. IVUSS, CEO of SonoPath.com
 Eric.Lindquist@SonoPath.com