



PATIENT

Lucy Zepeda

SPECIES

Canine

BREED

Yorkshire Terrier

SEX

Spayed Female

AGE

10 Years

WEIGHT

5 kg

INTERPRETED BY

Eric Lindquist, DMV,
DABVP (CFM), Cert.
IVUSS

IMAGING PERFORMED BY

Catherine Alexander,
LVT

HOSPITAL NAME

Northstar VS, PLLC

REFERRING VET

Dr. Kaiser

INVOICE

35291

DATE

1/7/26

PRESENTING CLINICAL SIGNS

History: Mast cell tumor, low grade II, at base of external haired vulva, < 1 cm; incompletely excised Nov 15, 2025. MC < 1History of allergic dermatitis. History of tracheal collapse. Elevated BUN. Elevated ALT.

ULTRASONOGRAPHIC EXAMINATION OF THE ABDOMEN

Urinary System

The **urinary bladder**, trigone, and pelvic urethra presented normal thicknesses and normal tone. The ureters were not visible which is normal. No uroliths or sediment were visualized and anechoic urine was present. No evidence of inflammatory or neoplastic changes was noted. Ureteral papillae were normal. The iliac trifurcation was unremarkable.

The **kidneys** revealed largely normal size and structure, corticomedullary definition and ratio (cortex 1/3 of medulla) were essentially maintained with some mild age-related loss of curvilinear patterns regarding the capsule and C/M junction. The cortices presented largely uniform texture with some increased echogenicity expected for this age patient. Medullary structure differed distinctly from that of the cortex, and no evidence of pelvic dilation was present. The right kidney measured 4.4 cm. The left kidney measured 4.16 cm.

Adrenal Glands

Both **adrenal glands** were visualized and recognized as having normal shape, size, position and echogenicity for this breed. The phrenic vasculature, glandular echogenicity and detail were unremarkable. Capsule, cortex, and medullary definition were normal for this age patient. The right adrenal gland measured 0.63 cm at the cranial pole and 0.63 cm at the caudal pole. The left adrenal gland measured 0.5 cm at the caudal pole and 0.34 cm at the cranial pole.

Spleen

The **spleen** presented a smooth homogeneous parenchyma hyperechoic to liver and renal cortical parenchyma. The capsule was smooth without noticeable expansion or deviation from within the spleen or adjacent pathology. The splenic vasculature demonstrated normal volume without signs of congestion or thrombosis. No sonographic evidence of acute or chronic inflammatory, neoplastic, or infarctual changes were noted.

Liver

The **liver** itself was unremarkable. The gallbladder revealed coalesced bile and sand, not pathological.

Gastrointestinal

There was some residual chyme and gas noted in the **stomach**, yet not pathological. This is consistent with end post prandial presentation. Transit of chyme into the small intestine was normal. Curvilinear patterns were maintained throughout the GI tract. No evidence of pathology. Small and large intestine demonstrated normal luminal chyme and stool consistency respectively. No obstructive or overt infiltrative disease was noted. No associated abnormal lymphatic activity was noted.

Pancreas



PATIENT

Lucy Zepeda

SPECIES

Canine

BREED

Yorkshire Terrier

SEX

Spayed Female

AGE

10 Years

WEIGHT

5 kg

INTERPRETED BY

Eric Lindquist, DMV,
DABVP (CFM), Cert.
IVUSS

IMAGING PERFORMED BY

Catherine Alexander,
LVT

HOSPITAL NAME

Northstar VS, PLLC

REFERRING VET

Dr. Kaiser

INVOICE

35291

DATE

1/7/26

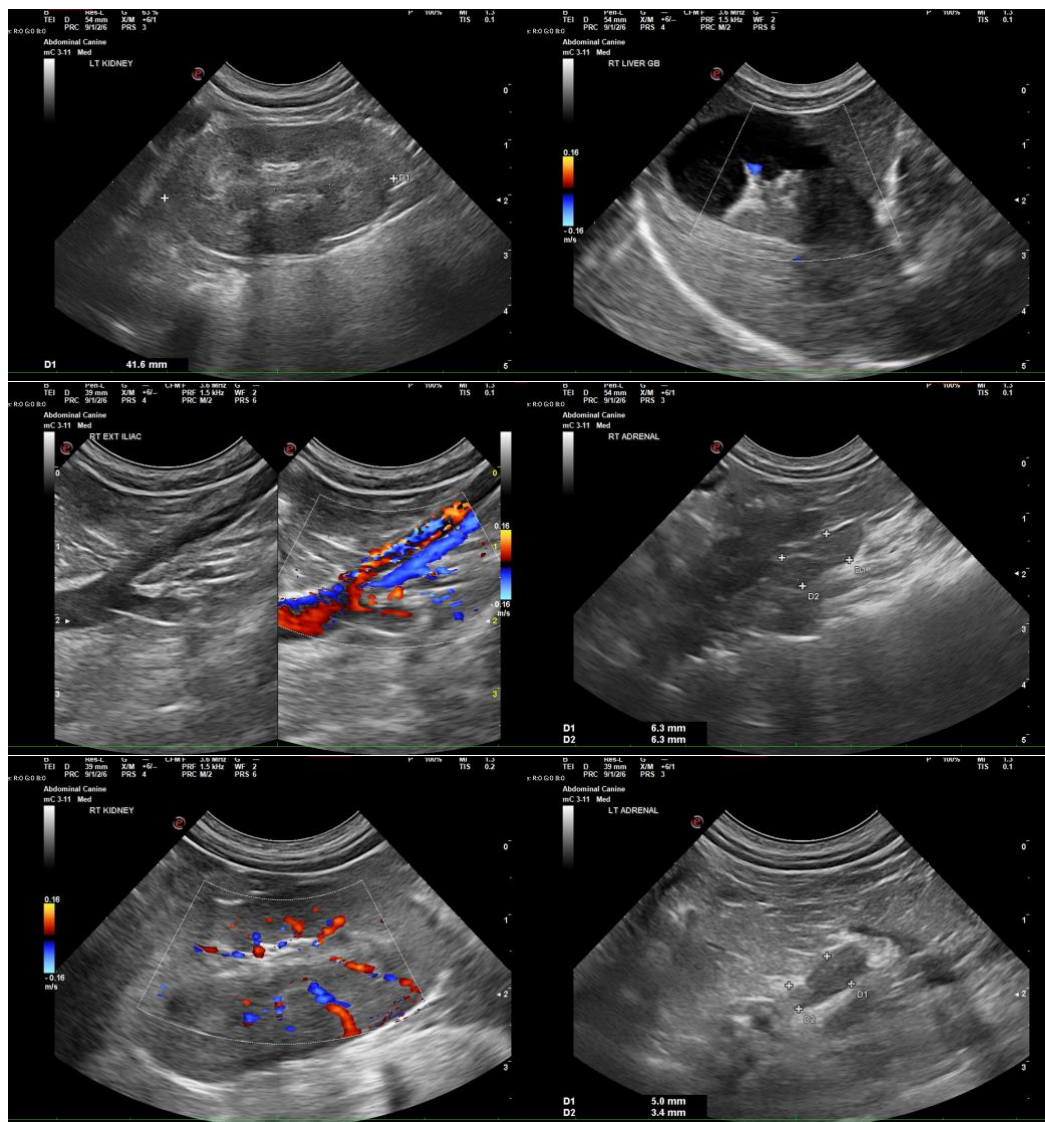
The base and limbs of the **pancreas** were observed to be largely isoechoic to surrounding omental fat. Pancreatic duct and capsular contour were acceptably normal and parenchyma respected normal curvilinear patterns. No overt evidence of active inflammatory or neoplastic disease was noted.

ULTRASONOGRAPHIC FINDINGS

- Minor gallbladder sand/debris
- Partially full stomach
- Structurally unremarkable abdomen otherwise

INTERPRETATION OF THE FINDINGS & FURTHER RECOMMENDATIONS

Ursodiol trial could be considered proactively. No evidence of significant pathology.





PATIENT

Lucy Zepeda

SPECIES

Canine

BREED

Yorkshire Terrier

SEX

Spayed Female

AGE

10 Years

WEIGHT

5 kg

INTERPRETED BY

Eric Lindquist, DMV,
DABVP (CFM), Cert.
IVUSS

IMAGING PERFORMED BY

Catherine Alexander,
LVT

HOSPITAL NAME

Northstar VS, PLLC

REFERRING VET

Dr. Kaiser

INVOICE

35291

DATE

1/7/26

The information and recommendations provided are based on the images presented by the referring veterinarian/sonographer. No evaluation can be communicated regarding pathology that was not visible in the image/video clips provided.

Thank you for this referral. If the clinical or image interpretation does not parallel your findings or if I can be of any further assistance please contact me.

Eric Lindquist, DMV, DABVP(CFM), Cert. IVUSS,
CEO, Owner, Founder -- SonoPath.com
info@SonoPath.com