



PATIENT

Cody Chon

SPECIES

Canine

BREED

Jindo

SEX

Neutered Male

AGE

11 Years

WEIGHT

51.7 lbs

INTERPRETED BY

Eric Lindquist, DMV,
DABVP (CFM), Cert.
IVUS

IMAGING PERFORMED BY

Dr. Kyoung Han

HOSPITAL NAME

Tenafly Vet Center

REFERRING VET

Dr. Kyoung Han

INVOICE

72047

DATE

1/7/26

PRESENTING CLINICAL SIGNS

Chronic vomiting on and off for the past couple of months . recently , night time liquid vomiting happens almost every night . he vomited food and liquid last night . lab work is pending . slight weight loss

ULTRASONOGRAPHIC EXAMINATION OF THE ABDOMEN

Urinary System

The **urinary bladder**, trigone, and pelvic urethra presented normal thicknesses and normal tone. The ureters were not visible which is normal. No uroliths or sediment were visualized and anechoic urine was present. No evidence of inflammatory or neoplastic changes were noted. Ureteral papillae were normal.

The **kidneys** revealed normal size and structure, corticomedullary definition and ratio for this age. The cortices presented largely uniform texture with normal echogenic relationship to liver and spleen. Medullary structure differed distinctly from the cortex and no evidence of pelvic dilation was present. The capsules were acceptably uniform without significant irregularities. Left kidney measured 5.2 cm. Right kidney measured 5.4 cm.

Adrenal Glands

The **left adrenal gland** was visualized obliquely, measuring small-normal in size at 0.50 cm.

The **right adrenal gland** was not visualized.

Spleen

The **spleen** presented a smooth homogeneous parenchyma hyperechoic to liver and renal cortical parenchyma. The capsule was smooth without noticeable expansion or deviation from within the spleen or adjacent pathology. The splenic vasculature demonstrated normal volume without signs of congestion or thrombosis. No sonographic evidence of acute or chronic inflammatory, neoplastic, or infarctual changes were noted.

Liver

The **liver** images submitted revealed subjectively normal liver size, contour, and structure. Parenchymal echogenicity was naturally coarse and hypoechoic to the spleen. Vascular and biliary tracts were of normal volume with no evidence of congestion. The gallbladder presented a minor amount of debris.

Gastrointestinal

The **stomach** revealed shadowing material strongly suggestive for foreign matter if the patient was NPO at the time of the sonogram, measuring approximately 4.4 cm. Large amount of gastric gas noted. The small intestine and colon were unremarkable.

Pancreas

The base and limbs of the **pancreas** were observed to be largely isoechoic to surrounding omental fat. Pancreatic duct and capsular contour were acceptably normal and parenchyma respected normal curvilinear patterns. No overt evidence of active inflammatory or neoplastic disease was noted.



PATIENT

Cody Chon

SPECIES

Canine

BREED

Jindo

SEX

Neutered Male

AGE

11 Years

WEIGHT

51.7 lbs

INTERPRETED BY

Eric Lindquist, DMV,
DABVP (CFM), Cert.
IVUSS

IMAGING PERFORMED BY

Dr. Kyoung Han

HOSPITAL NAME

Tenafly Vet Center

REFERRING VET

Dr. Kyoung Han

INVOICE

72047

DATE

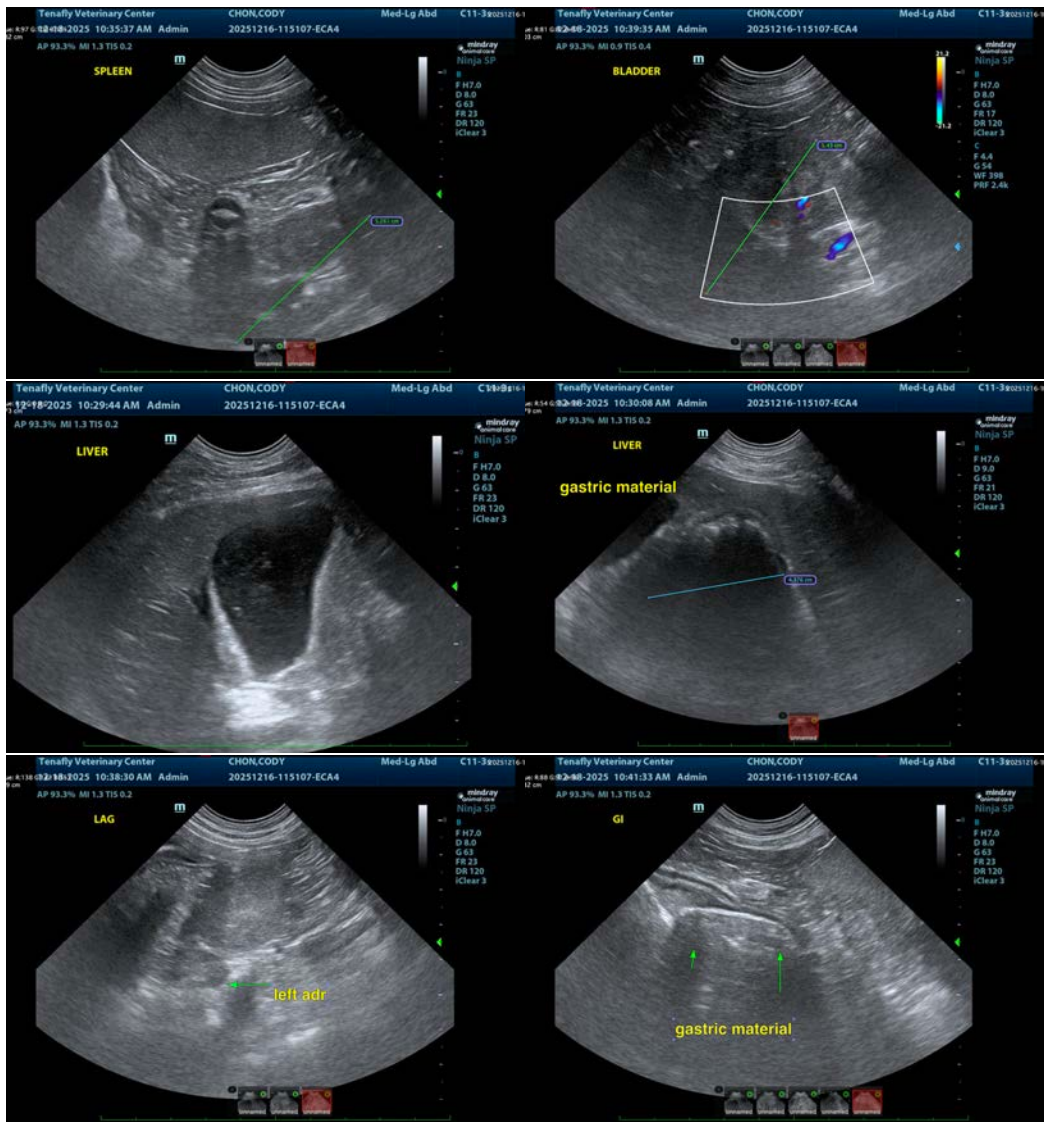
1/7/26

ULTRASONOGRAPHIC FINDINGS

- Full stomach with shadowing material.
- Unremarkable abdomen otherwise.

INTERPRETATION OF THE FINDINGS & FURTHER RECOMMENDATIONS

Assuming the patient was NPO at the time of the sonogram, endoscopy would be indicated. The cause of weight loss is unclear. Screening for Addison's indicated, given that the right adrenal gland was not visible. The left adrenal appeared small-normal in size.





PATIENT

Cody Chon

The information and recommendations provided are based on the images presented by the referring veterinarian/sonographer. No evaluation can be communicated regarding pathology that was not visible in the image/video clips provided.

SPECIES

Canine

Thank you for this referral. If the clinical or image interpretation does not parallel your findings or if I can be of any further assistance please contact me.

BREED

Jindo

Eric Lindquist, DMV, DABVP(CFM), Cert. IVUSS,
CEO, Owner, Founder -- SonoPath.com

info@SonoPath.com

SEX

Neutered Male

AGE

11 Years

WEIGHT

51.7 lbs

INTERPRETED BY

Eric Lindquist, DMV,
DABVP (CFM), Cert.
IVUSS

IMAGING PERFORMED BY

Dr. Kyoung Han

HOSPITAL NAME

Tenafly Vet Center

REFERRING VET

Dr. Kyoung Han

INVOICE

72047

DATE

1/7/26