



PATIENT

Athena Hsieh

SPECIES

Canine

BREED

Mix

SEX

Spayed female

AGE

1 year

WEIGHT

38 lbs

INTERPRETED BY

Eric Lindquist, DMV
DABVP, Cert. IVUSS

IMAGING PERFORMED BY

Jeremiah Gabriel

HOSPITAL NAME

Central Jersey AH

REFERRING VET

Dr. Gabriel

INVOICE

69946

DATE

1/7/26

PRESENTING CLINICAL SIGNS

History: vomiting, bloody diarrhea and anorexia acting lethargic for 1 days
CBC/chem WNL CPL WNL

ULTRASONOGRAPHIC EXAMINATION OF THE ABDOMEN

Urinary System

The **urinary bladder**, trigone, and pelvic urethra presented normal thicknesses and normal tone. The ureters were not visible which is normal. No uroliths or sediment were visualized and anechoic urine was present. No evidence of inflammatory or neoplastic changes was noted. Ureteral papillae were normal.

The **kidneys** revealed normal size and structure, corticomedullary definition and ratio for this age. The cortices presented largely uniform texture with normal echogenic relationship to liver and spleen. Medullary structure differed distinctly from the cortex and no evidence of pelvic dilation was present. The capsules were acceptably uniform without significant irregularities. The left kidney measured 6.1 cm. The right kidney measured 5.7 cm.

Adrenal Glands

The left **adrenal gland** was visualized and recognized as having normal shape, size, position and echogenicity for this breed. The phrenic vasculature, glandular echogenicity and detail were unremarkable. Capsule, cortex, and medullary definition were normal for this age patient. The left adrenal gland measured 0.5 cm at the cranial pole and 0.4 cm at the caudal pole. The right adrenal gland was not visualized.

Spleen

The **spleen** was mildly enlarged and folded upon itself cranially with uniform parenchyma with subtle, micronodular changes.

Liver

The **liver** images submitted revealed subjectively normal liver size, contour, and structure. Parenchymal echogenicity was naturally coarse and hypoechoic to the spleen. Vascular and biliary tracts were of normal volume with no evidence of congestion. The gallbladder presented acceptably thin walls with primarily anechoic content. The cystic and common bile ducts were normal. No pathological hepatic lymphadenopathy was evident. No overt structural evidence of inflammatory, infiltrative or regenerative pathology was evident.



PATIENT

Athena Hsieh

SPECIES

Canine

BREED

Mix

SEX

Spayed female

AGE

1 year

WEIGHT

38 lbs

INTERPRETED BY

Eric Lindquist, DMV
DABVP, Cert. IVUSS

IMAGING PERFORMED BY

Jeremiah Gabriel

HOSPITAL NAME

Central Jersey AH

REFERRING VET

Dr. Gabriel

INVOICE

69946

DATE

1/7/26

Gastrointestinal

Examination of the **gastrointestinal tract** revealed an unremarkable stomach and small intestine regarding structure. The stomach and upper small intestine was empty. There was no evidence of obstructive pattern. Curvilinear patterns were retained throughout the gastrointestinal tract. Areas of hyperperistalsis were noted. This is consistent with response to irritation. The colon was unremarkable, yet fluid filled.

Pancreas

The base and limbs of the **pancreas** were observed to be largely isoechoic to surrounding omental fat. Pancreatic duct and capsular contour were acceptably normal and parenchyma respected normal curvilinear patterns. No overt evidence of active inflammatory or neoplastic disease was noted.

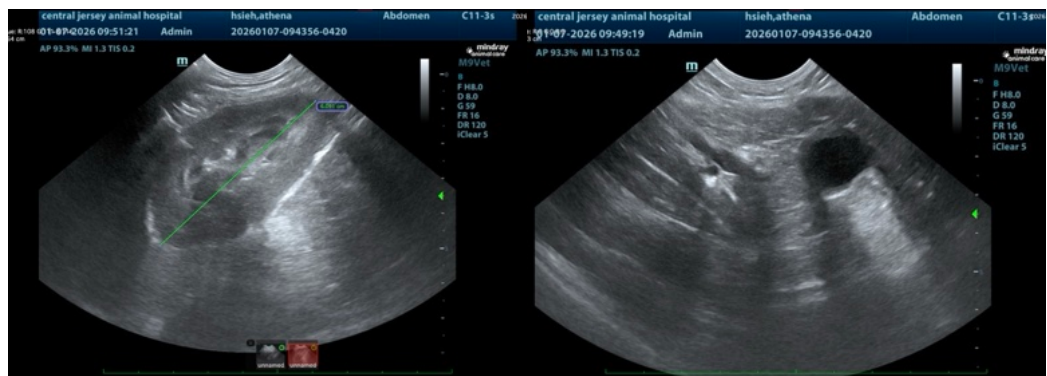
ULTRASONOGRAPHIC FINDINGS

Resolving enterocolitis pattern.

INTERPRETATION OF THE FINDINGS & FURTHER RECOMMENDATIONS

I suspect enterotoxin. There was no evidence of foreign body. Fecal test is recommended. IV fluid support, management for enterotoxin, plasma expanders, GI protectants and antiparasitic protocol is all indicated.

Dietary indiscretion, food intolerance, structurally significant inflammatory bowel or occult parasitism and occult Addison's are all potentials.





PATIENT

Athena Hsieh

SPECIES

Canine

BREED

Mix

SEX

Spayed female

AGE

1 year

WEIGHT

38 lbs

INTERPRETED BY

Eric Lindquist, DMV
DABVP, Cert. IVUSS

**IMAGING
PERFORMED BY**

Jeremiah Gabriel

HOSPITAL NAME

Central Jersey AH

REFERRING VET

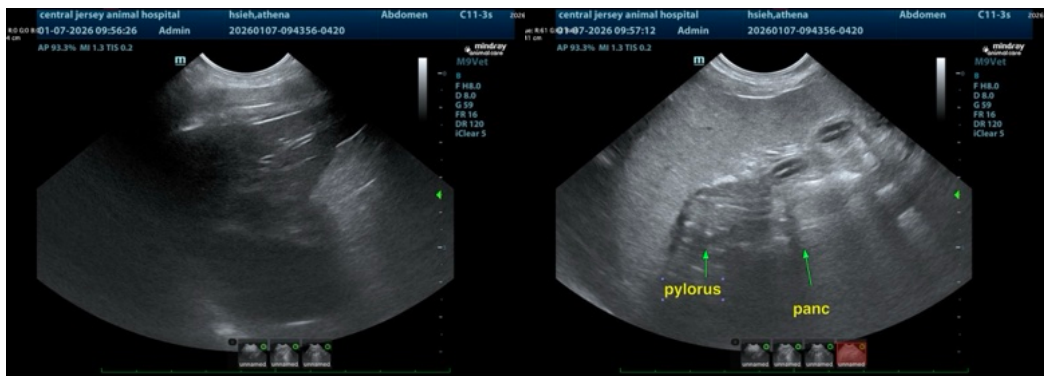
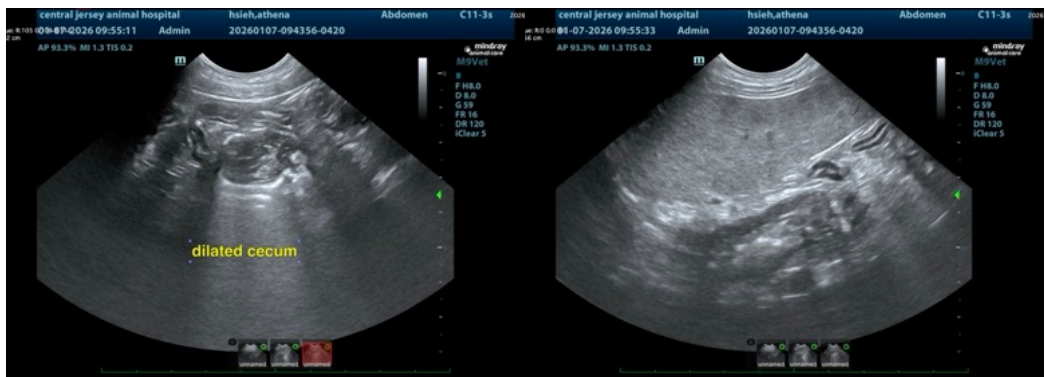
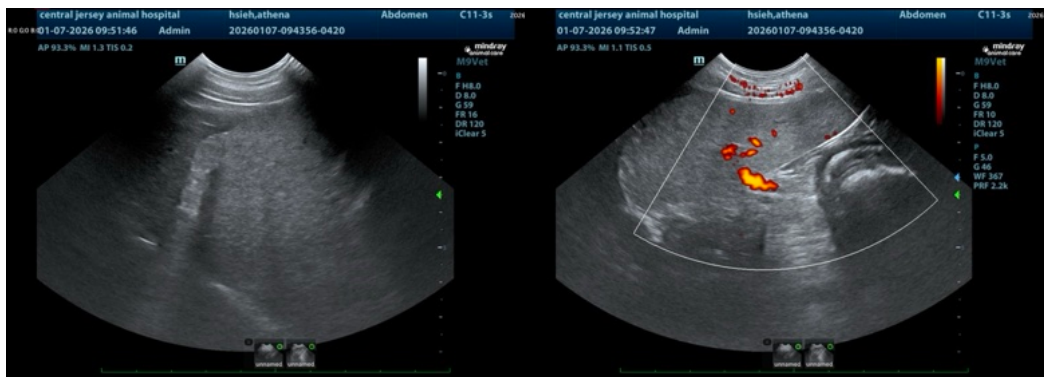
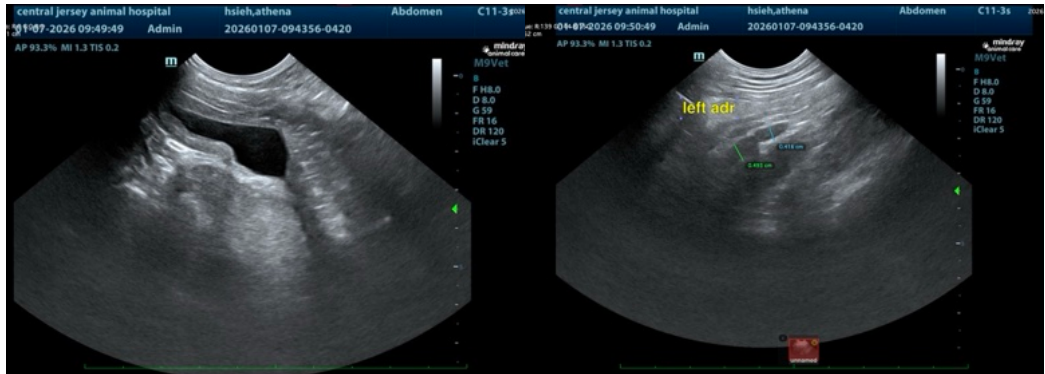
Dr. Gabriel

INVOICE

69946

DATE

1/7/26





PATIENT

Athena Hsieh

SPECIES

Canine

BREED

Mix

SEX

Spayed female

AGE

1 year

WEIGHT

38 lbs

INTERPRETED BY

Eric Lindquist, DMV
DABVP, Cert. IVUSS

IMAGING PERFORMED BY

Jeremiah Gabriel

HOSPITAL NAME

Central Jersey AH

REFERRING VET

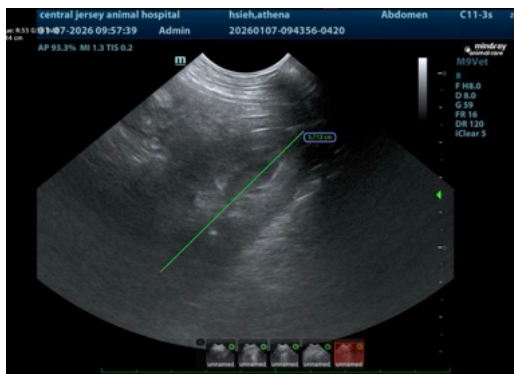
Dr. Gabriel

INVOICE

69946

DATE

1/7/26



The information and recommendations provided are based on the images presented by the referring veterinarian/sonographer. No evaluation can be communicated regarding pathology that was not visible in the image/video clips provided.

Thank you for this referral. If the clinical or image interpretation does not parallel your findings or if I can be of any further assistance please contact me.

Eric Lindquist, DMV, DABVP (CFM), Cert. IVUSS, CEO of SonoPath.com

info@SonoPath.com