



PATIENT

Mia Clements

SPECIES

Canine

BREED

Labrador

SEX

Spayed Female

AGE

13

WEIGHT

73

INTERPRETED BY

Eric Lindquist, DMV
DABVP, Cert. IVUSS

IMAGING PERFORMED BY

Adrienne Waffle

HOSPITAL NAME

Torch Lake VC

REFERRING VET

Dr. Pattenburge

INVOICE

20482

DATE

1/7/23

PRESENTING CLINICAL SIGNS

History: Seen at RDVM this am for annual exam. Currently on meloxicam, gabapentin, fish oil, glucosamine/chondroitin. Senior blood work showed non-regenerative anemia.

Abnormal PE/Chem/CBC/UA Results: MM - pink<2 BCS 5/9 Attitude - BAR HCT - 32.1 MCV - 57.8 MCHC - 43 Platelets - 309 Chemistry - unremarkable

ULTRASONOGRAPHIC EXAMINATION OF THE ABDOMEN

Urinary System

The **urinary bladder**, trigone, and pelvic urethra presented normal thicknesses and normal tone. The ureters were not visible which is normal. No uroliths or sediment were visualized, and anechoic urine was present. No evidence of inflammatory or neoplastic changes were noted. Ureteral papillae were normal.

The **kidneys** revealed largely normal size and structure, corticomedullary definition and ratio (cortex 1/3 of medulla) were essentially maintained with some age-related loss of curvilinear patterns regarding the capsule and C/M junction. The cortices presented largely uniform texture with some increased echogenicity expected for his age patient. Medullary structure differed distinctly from that of the cortex and no evidence of pelvic dilation was present. Mineralization was present in the kidneys. The left kidney measured 6.4 cm. The right kidney measured 6.5 cm.

Adrenal Glands

Both **adrenal glands** were visualized and recognized as having normal shape, size, position and echogenicity for this breed. The phrenic vasculature, glandular echogenicity and detail were unremarkable. Capsule, cortex, and medullary definition were normal for this age patient. The left adrenal gland measured 0.5 cm. The right adrenal gland measured approximately 8.0 mm at the cranial pole and 6.0 mm at the caudal pole.

Spleen

The **spleen** presented a smooth homogeneous parenchyma hyperechoic to liver and renal cortical parenchyma. The capsule was smooth without noticeable expansion or deviation from within the spleen or adjacent pathology. The splenic vasculature demonstrated normal volume without signs of congestion or thrombosis. No sonographic evidence of acute or chronic inflammatory, neoplastic, or infarctual changes were noted.

Liver

The **liver** images from right and left intercostal as well as subcostal views revealed subjectively normal liver size, contour, and structure. Some mild age-related parenchymal remodeling was noted but likely not clinically significant at this time. Vascular and biliary tracts were of normal volume and no evidence of congestion was noted. The gallbladder presented some dependent debris with essentially normal contour. The cystic and common bile ducts were normal. No overt evidence of active inflammatory, infiltrative or regenerative pathology was noted but should be paired with current or past LE elevations regarding any clinical significance to this presentation. The hepatic lymph nodes were unremarkable.

Gastrointestinal



PATIENT

Mia Clements

SPECIES

Canine

BREED

Labrador

SEX

Spayed Female

AGE

13

WEIGHT

73

INTERPRETED BY

Eric Lindquist, DMV
DABVP, Cert. IVUSS

IMAGING PERFORMED BY

Adrienne Waffle

HOSPITAL NAME

Torch Lake VC

REFERRING VET

Dr. Pattenbuge

INVOICE

20482

DATE

1/7/23

The **gastrointestinal tract** presented considerable gastric artifact due to the presence of ingesta. This did not permit thorough evaluation of portions of the gastric and upper intestinal structure. No overt abnormality was seen in the visualized tissue, however. This is consistent with a post-prandial presentation within a few hours of mealtime. If the prandial temporal interval does not fit the case history, and the patient presents a history of post-prandial vomiting, this could indicate a delayed upper gastrointestinal outflow due to primary or secondary pyloric hypertrophy, upper GI infiltrative disease, motor deficits, or a non-visualized foreign body. A prudent approach would be to rescan this patient at 24 hour NPO status to further review the non-visible regions if stomach primarily as well as assess any delayed outflow issue.

Pancreas

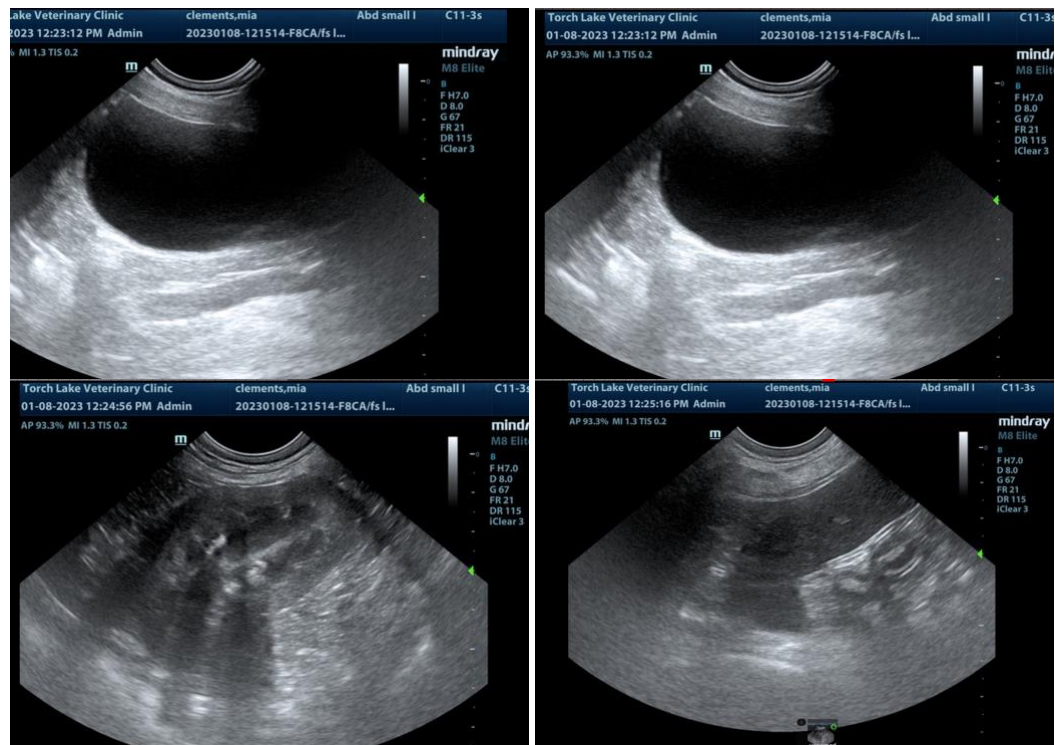
The base and limbs of the **pancreas** were observed to be largely isoechoic to surrounding omental fat. Pancreatic duct and capsular contour were acceptably normal and parenchyma respected normal curvilinear patterns. No overt evidence of active inflammatory or neoplastic disease was noted.

ULTRASONOGRAPHIC FINDINGS

- Age-related abdominal changes
- Minor renal mineralization (nonobstructive)
- Full stomach

INTERPRETATION OF THE FINDINGS & FURTHER RECOMMENDATIONS

No evidence of significant pathology. The cause of anemia is unclear. CBC path review +/- bone marrow aspirates indicated.





PATIENT

Mia Clements

SPECIES

Canine

BREED

Labrador

SEX

Spayed Female

AGE

13

WEIGHT

73

INTERPRETED BY

Eric Lindquist, DMV
DABVP, Cert. IVUSS

IMAGING PERFORMED BY

Adrienne Waffle

HOSPITAL NAME

Torch Lake VC

REFERRING VET

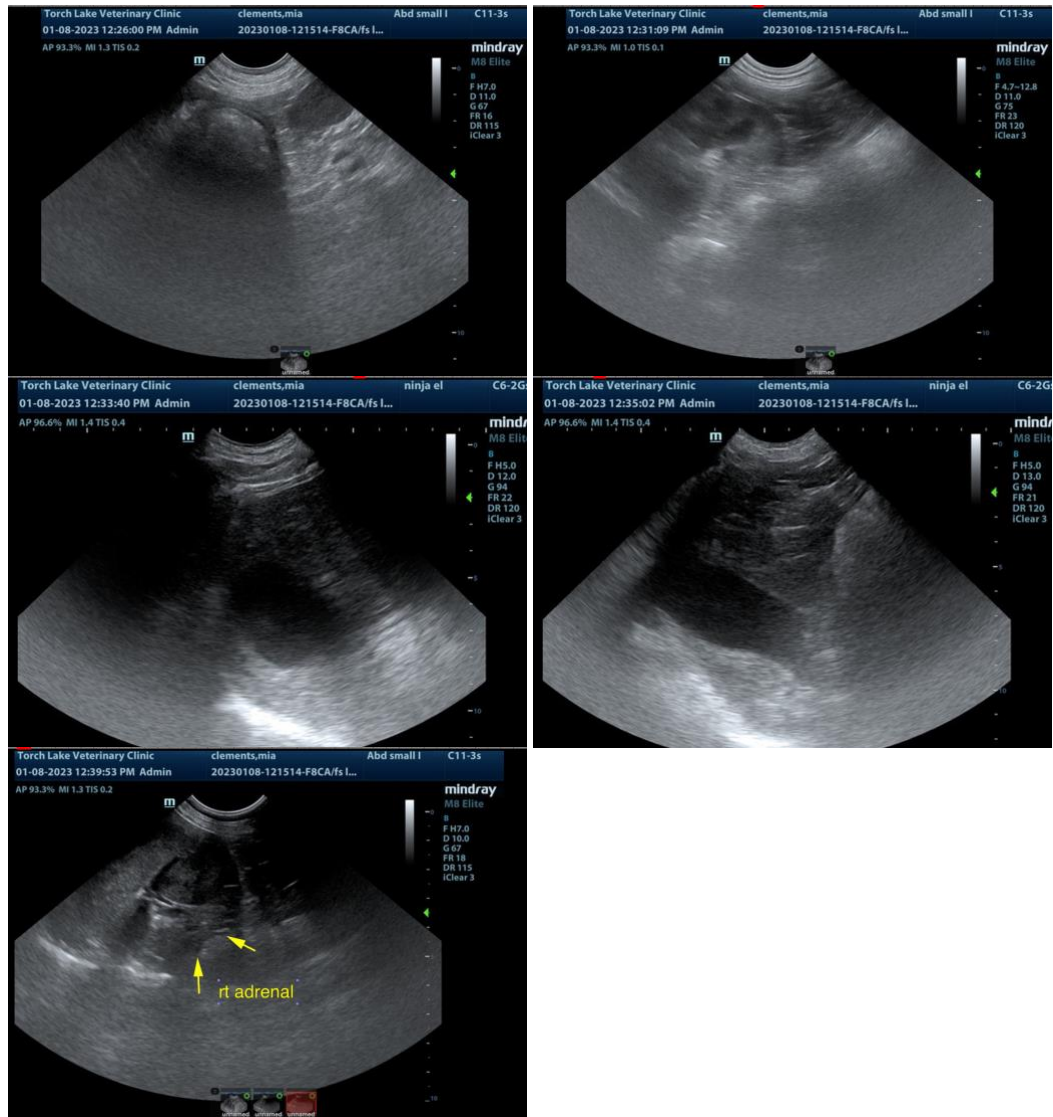
Dr. Pattenburge

INVOICE

20482

DATE

1/7/23



The information and recommendations provided are based on the images presented by the referring veterinarian. No evaluation can be communicated regarding pathology that was not visible in the image/video clips provided.

Thank you for this referral. If the clinical or image interpretation does not parallel your findings or if I can be of any further assistance please contact me.

Eric Lindquist, DMV, DABVP, Cert. IVUSS, CEO of SonoPath.com
info@SonoPath.com