



**PATIENT**

Sox Glessing

**SPECIES**

Feline

**BREED**

DSH

**SEX**

Male

**AGE**

1 Year

**WEIGHT**

7 Lbs.

**INTERPRETED BY**

Eric Lindquist, DMV  
DABVP, Cert. IVUSS

**IMAGING  
PERFORMED BY**

Jill Rumachik

**HOSPITAL NAME**

Mazomanie AH

**REFERRING VET**

CC Sheldon

**INVOICE**

13309

**DATE**

1/7/22

**PRESENTING CLINICAL SIGNS**

History: Intact male cat - presented for neuter. Pre-op bw revealed elevated kidney values - kidneys felt large upon palpation. Neuter postponed.

Abnormal PE/Chem/CBC/UA Results: 1/5/22 SDMA 47 (normal 0-14) PHOS 7.9 (normal 3.1-7.5) LIPA 2069 (normal 100-1400) Monocytosis 1.19 (normal 0.05 - 0.67) U/A wnl -- culture pending

**ULTRASONOGRAPHIC EXAMINATION OF THE ABDOMEN**

**Urinary System**

The **urinary bladder**, trigone, and pelvic urethra presented normal thicknesses and normal tone. The ureters were not visible which is normal. No uroliths or sediment were visualized and anechoic urine was present. No evidence of inflammatory or neoplastic changes were noted. Ureteral papillae were normal.

The **kidneys** were normal in size and contour with slight subjective cortical thickening with hyperechoic medullary rim sign. The left kidney measured 4.24 cm. The right kidney measured 4.48 cm.

**Adrenal Glands**

The regions of the **adrenal glands** revealed no evidence of pathology.

**Spleen**

The **spleen** presented a smooth homogeneous parenchyma hyperechoic to liver and renal cortical parenchyma. The capsule was smooth without noticeable expansion or deviation from within the spleen or adjacent pathology. The splenic vasculature demonstrated normal volume without signs of congestion or thrombosis. No sonographic evidence of acute or chronic inflammatory, neoplastic, or infarctual changes were noted. The spleen measured the upper limits of normal at 1.1 cm.

**Liver**

The **liver** images submitted revealed subjectively normal liver size, contour, and structure. Parenchymal echogenicity was naturally coarse and hypoechoic to the spleen. Vascular and biliary tracts were of normal volume with no evidence of congestion. The gallbladder presented acceptably thin walls with primarily anechoic content. The cystic and common bile ducts were normal. No pathological hepatic lymphadenopathy was evident. No overt structural evidence of inflammatory, infiltrative or regenerative pathology was evident.

**Gastrointestinal**

Some retention of ingesta was noted in the **stomach**. The small intestine and colon were unremarkable.

**Pancreas**

The base and limbs of the **pancreas** were observed to be largely isoechoic to surrounding omental fat. Pancreatic duct and capsular contour were acceptably normal and parenchyma respected normal curvilinear patterns. No overt evidence of active inflammatory or neoplastic disease was noted.

**ULTRASONOGRAPHIC FINDINGS**



**PATIENT**

- Unremarkable abdomen with nonspecific mild hyperechoic medullary rim kidney

Sox Glessing

**INTERPRETATION OF THE FINDINGS & FURTHER RECOMMENDATIONS**

**SPECIES**

Toxin exposure, infectious agents and FIP all a potential. However, this is a very nonspecific presentation. Renal biopsy could be considered, however, false positive SDMA may be an issue in this patient. I recommend rechecking the SDMA value + renal biopsy, if still an issue.

Feline

**BREED**

DSH

**SEX**

Male

**AGE**

1 Year

**WEIGHT**

7 Lbs.

**INTERPRETED BY**

Eric Lindquist, DMV  
DABVP, Cert. IVUSS

**IMAGING PERFORMED BY**

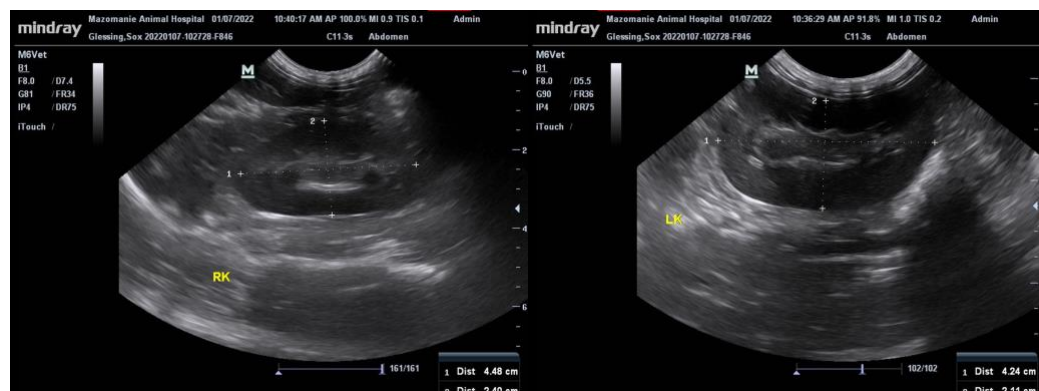
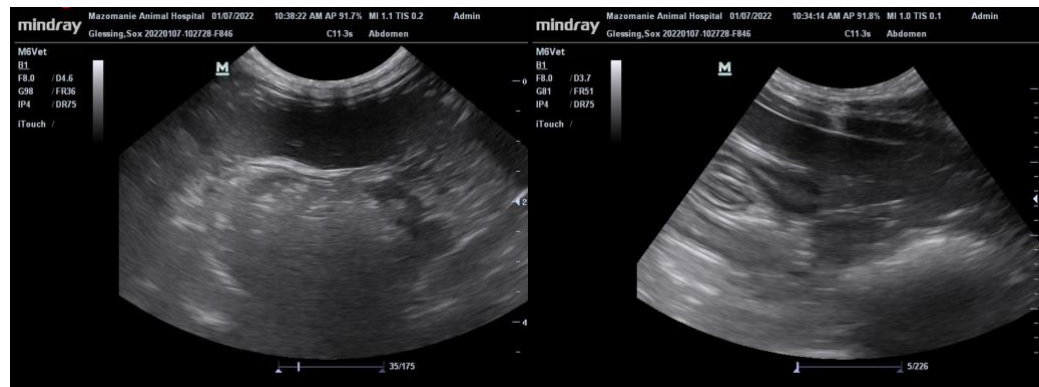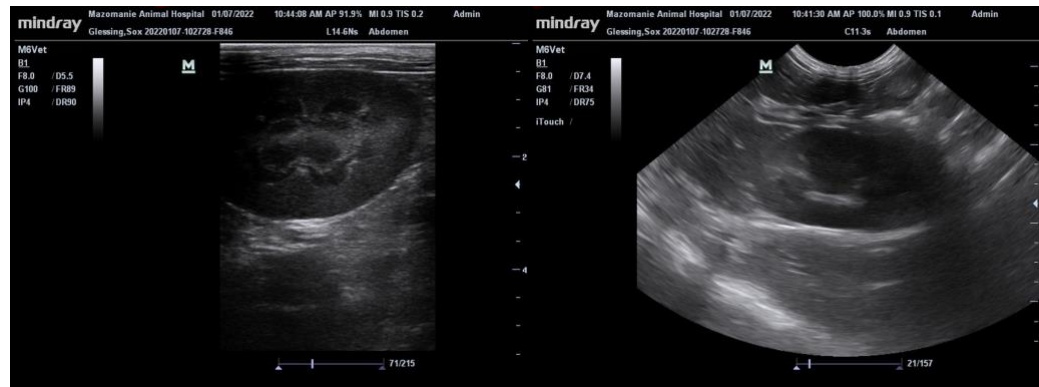Jill Rumachik

**HOSPITAL NAME**

Mazomanie AH

**REFERRING VET**

CC Sheldon



**INVOICE**

13309

**DATE**

1/7/22

The information and recommendations provided are based on the images presented by the referring veterinarian. No evaluation can be communicated regarding pathology that was not visible in the image/video clips provided.

Thank you for this referral. If the clinical or image interpretation does not parallel your findings or if I can be of any further assistance please contact me.



**PATIENT**

Sox Glessing

**Eric Lindquist**, DMV, DABVP, Cert. IVUSS, CEO of SonoPath.com  
info@SonoPath.com

**SPECIES**

Feline

**BREED**

DSH

**SEX**

Male

**AGE**

1 Year

**WEIGHT**

7 Lbs.

**INTERPRETED BY**

Eric Lindquist, DMV  
DABVP, Cert. IVUSS

**IMAGING  
PERFORMED BY**

Jill Rumachik

**HOSPITAL NAME**

Mazomanie AH

**REFERRING VET**

CC Sheldon

**INVOICE**

13309

**DATE**

1/7/22