



PATIENT PRESENTING CLINICAL SIGNS

Paco Saez
HGE, recurring.
Abnormal PE/Chem/CBC/UA Results: nsf

SPECIES ULTRASONOGRAPHIC EXAMINATION OF THE ABDOMEN

Canine

Urinary System

BREED

American Staffordshire

The **urinary bladder**, trigone, and pelvic urethra presented normal thicknesses and normal tone. The ureters were not visible which is normal. No uroliths or sediment were visualized and anechoic urine was present. No evidence of inflammatory or neoplastic changes were noted. Ureteral papillae were normal. The pelvic urethra was imaged 3.0 cm beyond the cystourethral junction.

SEX

Neutered Male

The **kidneys** revealed normal size and structure, corticomedullary definition and ratio for this age. The cortices presented largely uniform texture with normal echogenic relationship to liver and spleen. Medullary structure differed distinctly from the cortex and no evidence of pelvic dilation was present. The capsules were acceptably uniform without significant irregularities. The left kidney measured 5.77 cm. The right kidney measured 7.0 cm.

AGE

1 Year

Adrenal Glands

WEIGHT

63 Pounds

Both **adrenal glands** were visualized and recognized as having normal shape, size, position and echogenicity for this breed. The phrenic vasculature, glandular echogenicity and detail were unremarkable. Capsule, cortex, and medullary definition were normal for this age patient. The right adrenal gland measured 3.19 cm x 1.04 cm at the cranial pole and 0.48 cm at the caudal pole. The left adrenal gland measured 2.8 cm x 0.43 cm at the caudal pole and 0.43 cm at the cranial pole.

INTERPRETED BY

Eric Lindquist, DMV
DABVP, Cert. IVUSS

Spleen

The **spleen** presented a smooth homogeneous parenchyma hyperechoic to liver and renal cortical parenchyma. The capsule was smooth without noticeable expansion or deviation from within the spleen or adjacent pathology. The splenic vasculature demonstrated normal volume without signs of congestion or thrombosis. No sonographic evidence of acute or chronic inflammatory, neoplastic, or infarctual changes were noted.

IMAGING PERFORMED BY

Shari Reffi, CVT

Liver

HOSPITAL NAME

Rockaway AH

The **liver** images submitted revealed subjectively normal liver size, contour, and structure. Parenchymal echogenicity was naturally coarse and hypoechoic to the spleen. Vascular and biliary tracts were of normal volume with no evidence of congestion. The gallbladder presented acceptably thin walls with primarily anechoic content. The cystic and common bile ducts were normal. No pathological hepatic lymphadenopathy was evident. No overt structural evidence of inflammatory, infiltrative or regenerative pathology was evident.

REFERRING VET

Dr. Maniar

Gastrointestinal

INVOICE

34078

The **stomach** itself was unremarkable. Minor distal small intestinal thickening noted with hypertrophied muscularis, typical inflammatory bowel. Minor reactive mesenteric lymph nodes noted measuring 3.0 cm x 1.5 cm.

Pancreas

DATE

1/7/22

The base and limbs of the **pancreas** were observed to be largely isoechoic to surrounding omental fat. Pancreatic duct and capsular contour were acceptably normal and parenchyma respected normal curvilinear patterns. No overt evidence of active inflammatory or neoplastic disease was noted.



PATIENT

Paco Saez

ULTRASONOGRAPHIC FINDINGS

- Inflammatory bowel presentation

SPECIES

Canine

INTERPRETATION OF THE FINDINGS & FURTHER RECOMMENDATIONS

Broad-spectrum anti-parasitic protocol warranted. Enrofloxacin/Metronidazole or Enrofloxacin/Clindamycin recommended over a 10 day period to treat for enterotoxins. Otherwise, colonoscopy would be indicated or full thickness gastrointestinal biopsies.

BREED

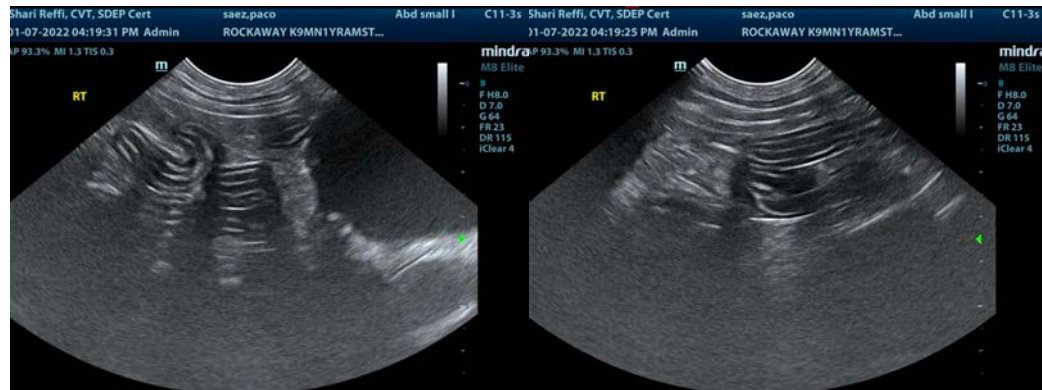
American Staffordshire

SEX

Neutered Male

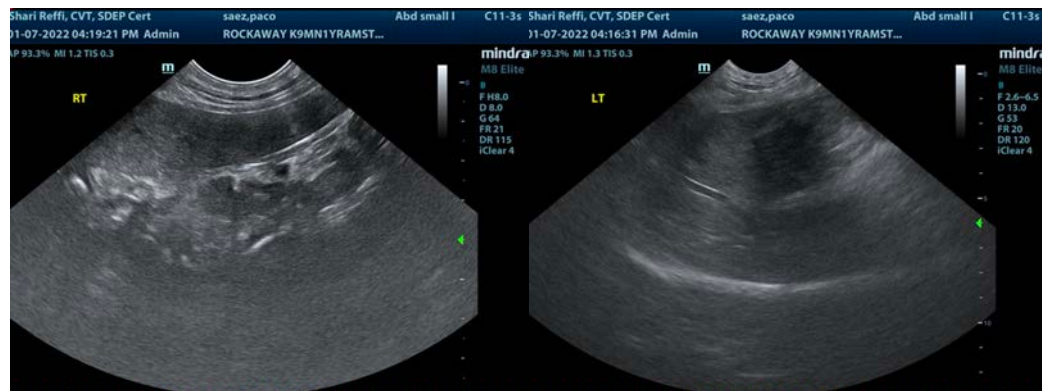
AGE

1 Year



WEIGHT

63 Pounds

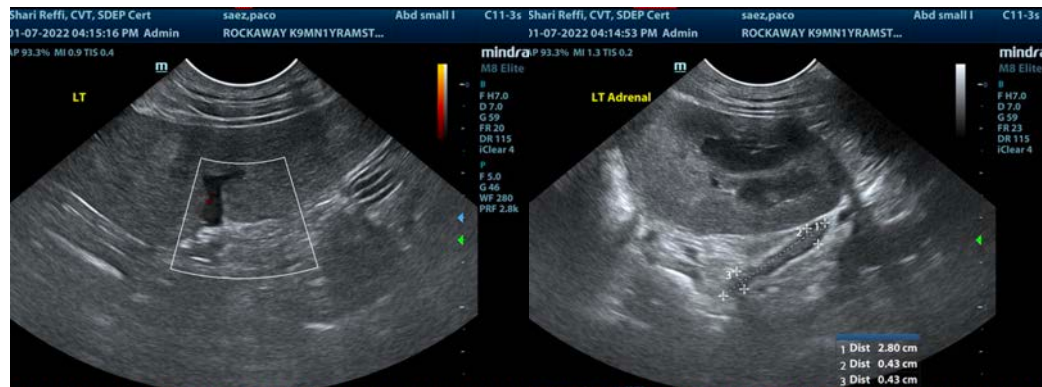


INTERPRETED BY

Eric Lindquist, DMV
DABVP, Cert. IVUSS

IMAGING PERFORMED BY

Shari Reffi, CVT



HOSPITAL NAME

Rockaway AH

REFERRING VET

Dr. Maniar

INVOICE

34078

DATE

1/7/22



PATIENT

Paco Saez

SPECIES

Canine

BREED

American Staffordshire

SEX

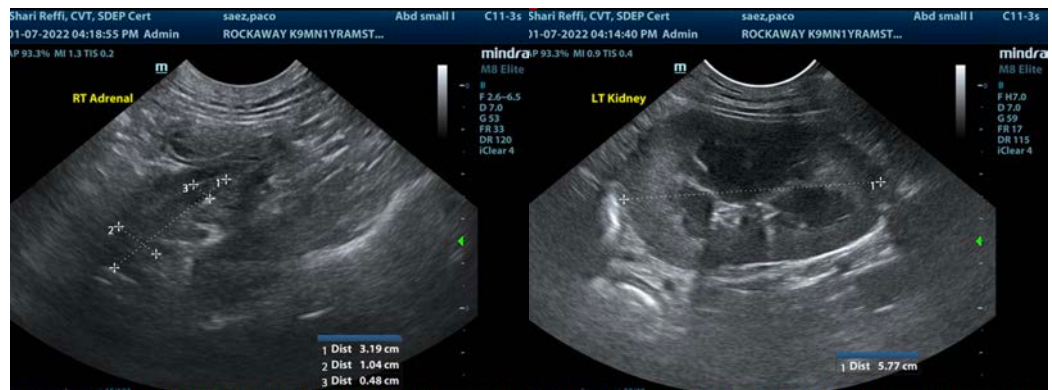
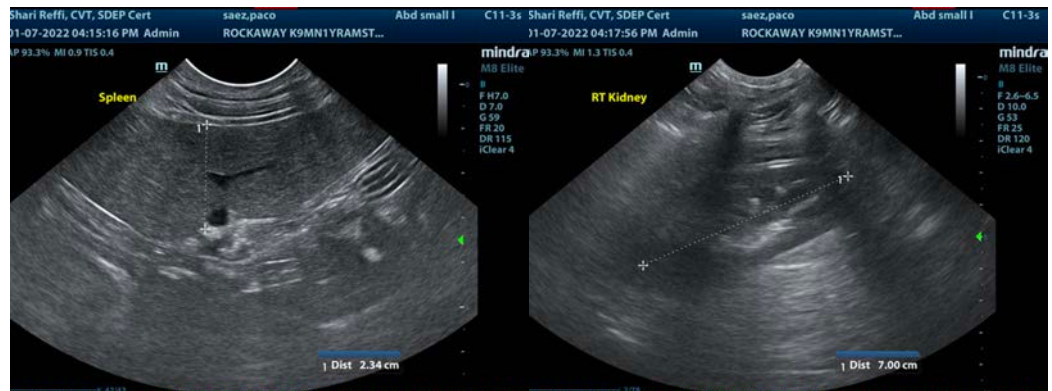
Neutered Male

AGE

1 Year

WEIGHT

63 Pounds



INTERPRETED BY

Eric Lindquist, DMV
DABVP, Cert. IVUSS

IMAGING PERFORMED BY

Shari Reffi, CVT

HOSPITAL NAME

Rockaway AH

REFERRING VET

Dr. Maniar

INVOICE

34078

DATE

1/7/22

The information and recommendations provided are based on the images presented by the referring veterinarian. No evaluation can be communicated regarding pathology that was not visible in the image/video clips provided.

Thank you for this referral. If the clinical or image interpretation does not parallel your findings or if I can be of any further assistance please contact me.

Eric Lindquist, DMV, DABVP, Cert. IVUSS, CEO of SonoPath.com
info@SonoPath.com