SonoPath
Clinical Sonography & Telecytology
EDUCATIONAL TELECONSULTATION SERVICES™
1-800-838-4268 info@sonopath.com SonoPath.com

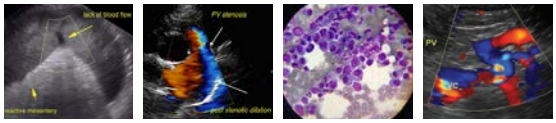

ANIMAL SOUNDS NW
MOBILE VETERINARY ULTRASOUND
IMAGING PERFORMED BY
AnimalSoundsNW.com 541-357-9423

PATIENT

Baxter Billings

SPECIES

Canine

BREED

West Highland Terrier

SEX

Neutered Male

AGE

13 Years

WEIGHT

18.9 Pounds

INTERPRETED BY

Eric Lindquist, DMV, DABVP, Cert. IVUSS

IMAGING PERFORMED BY

Jenna Walsh, CVT

HOSPITAL NAME

Edgewood AC

REFERRING VET

Dr. Kimball

DATE

1/7/22

INVOICE

34094

PRESENTING CLINICAL SIGNS

PU/PD
Abnormal PE/Chem/CBC/UA Results: Mildly elevated Alkp. Chronic (over 3yr) history of hypercalcemia (12.2 in December) Normal LDDS

ULTRASONOGRAPHIC EXAMINATION OF THE ABDOMEN

Urinary System

The **urinary bladder**, trigone, and pelvic urethra presented normal thicknesses and normal tone. The ureters were not visible which is normal. No uroliths or sediment were visualized and anechoic urine was present. No evidence of inflammatory or neoplastic changes were noted. Ureteral papillae were normal. The pelvic urethra was imaged 2.0 cm beyond the cystourethral junction. The residual prostate measured 8.0 mm.

The **kidneys** revealed largely normal size and structure, corticomedullary definition and ratio (cortex 1/3 of medulla) were essentially maintained with some age-related loss of curvilinear patterns regarding the capsule and C/M junction. The cortices presented largely uniform texture with some increased echogenicity expected for his age patient. Medullary structure differed distinctly from that of the cortex and no evidence of pelvic dilation was present. The left kidney measured 4.5 cm. The right kidney measured 5.0 cm.

Adrenal Glands

Both **adrenal glands** were visualized and recognized as having normal shape, size, position and echogenicity for this breed. The phrenic vasculature, glandular echogenicity and detail were unremarkable. Capsule, cortex, and medullary definition were normal for this age patient. The right adrenal gland measured 1.74 cm x 0.57 cm at the cranial pole and 0.49 cm at the caudal pole. The left adrenal gland measured 1.63 cm x 0.52 cm at the caudal pole and 0.50 cm at the cranial pole.

Spleen

The **spleen** presented a smooth homogeneous parenchyma hyperechoic to liver and renal cortical parenchyma. The capsule was smooth without noticeable expansion or deviation from within the spleen or adjacent pathology. The splenic vasculature demonstrated normal volume without signs of congestion or thrombosis. No sonographic evidence of acute or chronic inflammatory, neoplastic, or infarctual changes were noted.

Liver

The **liver** presented largely age related with minor heterogeneous parenchymal changes. A cystic lesion was noted in the left cranial liver, adjacent to the gallbladder. Some echogenic debris was noted in the cyst. The cystic lesion was multiple cysts coalescing into one lesion. It does not appear overtly pathological. Minor potential for abscessation. However, no inflammatory pattern noted around the cystic lesion.

Gastrointestinal

Minor retention of ingesta noted in the **stomach**. The small intestine and colon were unremarkable.

SonoPath
Clinical Sonography & Telecytology
EDUCATIONAL TELECONSULTATION SERVICES™
1-800-838-4268 info@sonopath.com SonoPath.com

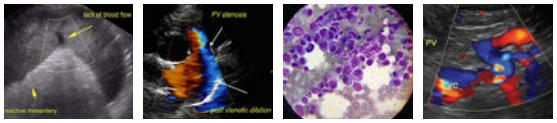

ANIMAL SOUNDS NW
MOBILE VETERINARY ULTRASOUND
IMAGING PERFORMED BY
AnimalSoundsNW.com 541-357-9423

PATIENT

Baxter Billings

SPECIES

Canine

BREED

West Highland Terrier

SEX

Neutered Male

AGE

13 Years

WEIGHT

18.9 Pounds

INTERPRETED BY

Eric Lindquist, DMV, DABVP, Cert. IVUSS

IMAGING PERFORMED BY

Jenna Walsh, CVT

HOSPITAL NAME

Edgewood AC

REFERRING VET

Dr. Kimball

DATE

1/7/22

INVOICE

34094

Pancreas

The right limb of the **pancreas** revealed diffuse coarse hyperechoic changes, consistent with remodeling. History of pancreatitis likely.

ULTRASONOGRAPHIC FINDINGS

- Pancreatic remodeling
- Left cranial hepatic cyst – Minor potential for cystic carcinoma or abscessation
- Geriatric abdomen otherwise

INTERPRETATION OF THE FINDINGS & FURTHER RECOMMENDATIONS

No evidence of significant disease. Some possibility of minor chronic active pancreatic inflammation. The cause of hypercalcemia is not evident in the abdomen. If hypercalcemia is persistent, then full hypercalcemia panel would be recommended +/- anal gland, spinal, cranial mediastinum, and parathyroid imaging. The cause of PU/PD is unclear. The adrenal glands appear normal. However, assessment for any evidence of UTI would be appropriate if not already performed. Recheck sonogram in one month primarily regarding the cystic lesion in the left cranial liver. If growing, then ultrasound guided sampling, drainage and cytospin recommended as well as culture.

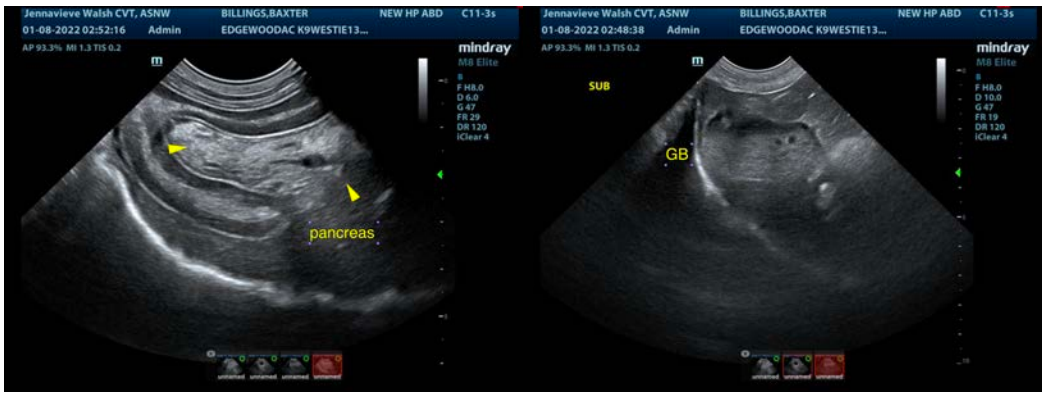

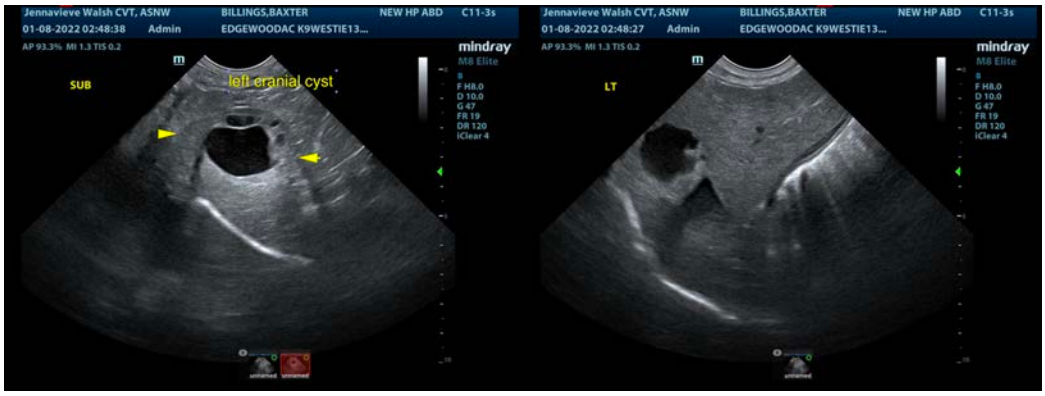

SonoPath
Clinical Sonography & Telecytology

EDUCATIONAL TELECONSULTATION SERVICES™

1-800-838-4268 info@sonopath.com SonoPath.com

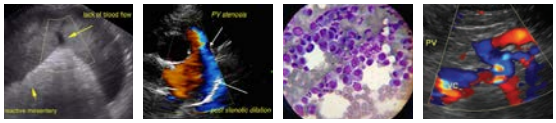

ANIMAL SOUNDS NW
MOBILE VETERINARY ULTRASOUND

IMAGING PERFORMED BY

AnimalSoundsNW.com 541-357-9423

PATIENT

Baxter Billings

SPECIES

Canine

BREED

West Highland Terrier

SEX

Neutered Male

AGE

13 Years

WEIGHT

18.9 Pounds

INTERPRETED BY

Eric Lindquist, DMV, DABVP, Cert. IVUSS

IMAGING PERFORMED BY

Jenna Walsh, CVT

HOSPITAL NAME

Edgewood AC

REFERRING VET

Dr. Kimball

DATE

1/7/22

INVOICE

34094

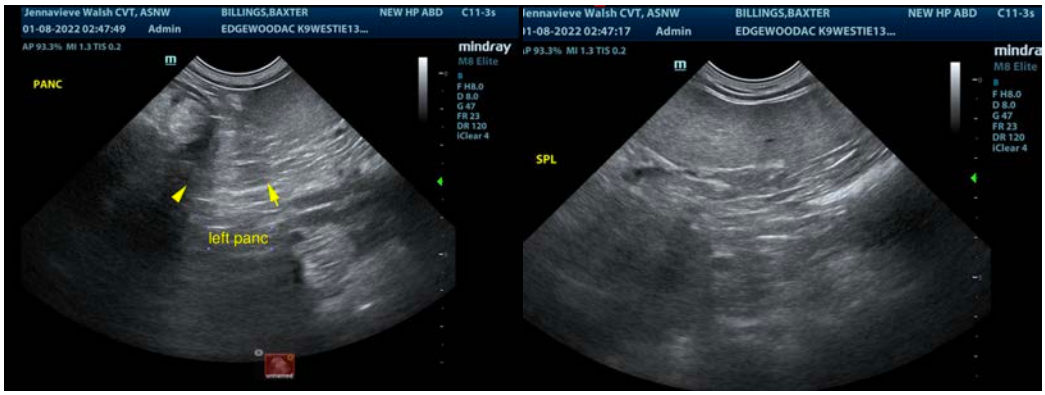

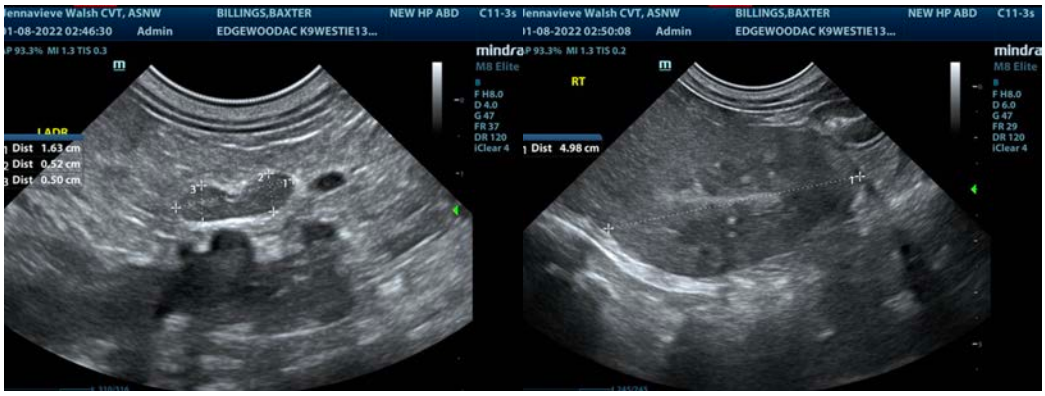

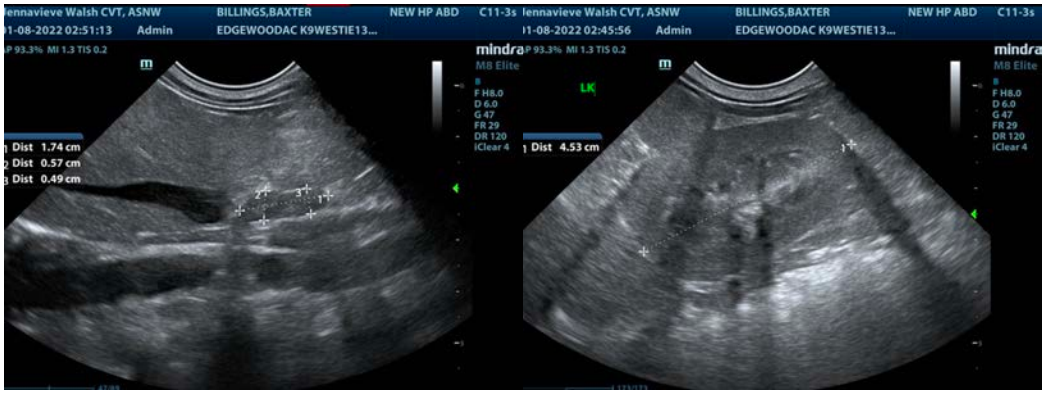

The information and recommendations provided are based on the images presented by the referring veterinarian. No evaluation can be communicated regarding pathology that was not visible in the image/video clips provided.

Thank you for this referral. If the clinical or image interpretation does not parallel your findings or if I can be of any further assistance please contact me.

Eric Lindquist, DMV, DABVP, Cert. IVUSS

CEO of Sonopath.com

Eric.Lindquist@SonoPath.com