SonoPath

Clinical Sonography & Telecytology

EDUCATIONAL TELECONSULTATION SERVICES™

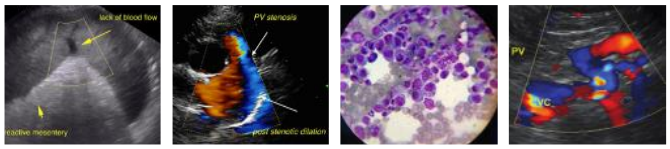

SonoPath.com™
1-800-838-4268 info@sonopath.com

PATIENT

Addi Anderson

SPECIES

Canine

BREED

Springer Spaniel

SEX

Spayed Female

AGE

4 Years

WEIGHT

43 Lbs.

INTERPRETED BY

Eric Lindquist, DMV
DABVP, Cert. IVUSS

IMAGING PERFORMED BY

Ray Caughman

HOSPITAL NAME

Dogwood AH

REFERRING VET

Dr. Ray Caughman

INVOICE

13313

DATE

1/7/22

PRESENTING CLINICAL SIGNS

History: Presented lethargic and not eating much. Ate overcooked bacon 36 hours ago. No vomit or diarrhea.

Abnormal PE/Chem/CBC/UA Results: Mild pain on palpation cranial abdomen. Rectal temp 103.2 WBC 23,000 CPL normal

ULTRASONOGRAPHIC EXAMINATION OF THE ABDOMEN

Urinary System

The **urinary bladder**, trigone, and pelvic urethra presented normal thicknesses and normal tone. The ureters were not visible which is normal. No uroliths or sediment were visualized, and anechoic urine was present. No evidence of inflammatory or neoplastic changes were noted. Ureteral papillae were normal. The pelvic urethra was imaged 2.0 cm beyond the cystourethral junction.

The **kidneys** revealed normal size and structure, corticomedullary definition and ratio for this age. The cortices presented largely uniform texture with normal echogenic relationship to liver and spleen. Medullary structure differed distinctly from the cortex and no evidence of pelvic dilation was present. The capsules were acceptably uniform without significant irregularities. The right kidney measured 6.11 cm. The left kidney measured 5.75 cm.

Adrenal Glands

The **adrenal glands** technically measure within normal limits, however, appear subjectively flattened. Screening for Addison's warranted given the age of the patient and the vague clinical signs. The left adrenal gland measured 1.59 cm x 0.36 cm. The right adrenal gland measured 1.29 cm x 0.41 cm.

Spleen

The **spleen** presented a smooth homogeneous parenchyma hyperechoic to liver and renal cortical parenchyma. The capsule was smooth without noticeable expansion or deviation from within the spleen or adjacent pathology. The splenic vasculature demonstrated normal volume without signs of congestion or thrombosis. No sonographic evidence of acute or chronic inflammatory, neoplastic, or infarctual changes were noted.

Liver

The **liver** images submitted revealed subjectively normal liver size, contour, and structure. Parenchymal echogenicity was naturally coarse and hypoechoic to the spleen. Vascular and biliary tracts were of normal volume with no evidence of congestion. The gallbladder presented acceptably thin walls with primarily anechoic content. The cystic and common bile ducts were normal. No pathological hepatic lymphadenopathy was evident. No overt structural evidence of inflammatory, infiltrative or regenerative pathology was evident.

Gastrointestinal

Examination of the **gastrointestinal tract** revealed a stomach and intestine free of stasis, of normal wall thickness, acceptable curvilinear mural detail, and peristaltic activity. Small and large intestine demonstrated normal luminal chyme and stool consistency respectively. No obstructive or overt infiltrative disease was noted. No associated abnormal lymphatic activity was noted.

Pancreas

SonoPath
Clinical Sonography & Telecytology

EDUCATIONAL TELECONSULTATION SERVICES™

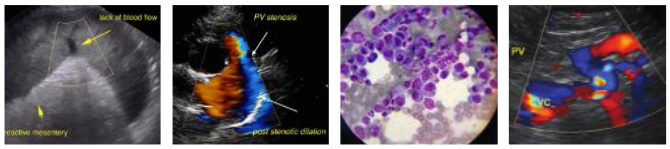

SonoPath.com
1-800-838-4268 info@sonopath.com

PATIENT

Addi Anderson

SPECIES

Canine

BREED

Springer Spaniel

SEX

Spayed Female

AGE

4 Years

WEIGHT

43 Lbs.

INTERPRETED BY

Eric Lindquist, DMV
DABVP, Cert. IVUSS

IMAGING PERFORMED BY

Ray Caughman

HOSPITAL NAME

Dogwood AH

REFERRING VET

Dr. Ray Caughman

INVOICE

13313

DATE

1/7/22

The base and limbs of the **pancreas** were observed to be largely isoechoic to surrounding omental fat. Pancreatic duct and capsular contour were acceptably normal and parenchyma respected normal curvilinear patterns. No overt evidence of active inflammatory or neoplastic disease was noted.

ULTRASONOGRAPHIC FINDINGS

- Structurally unremarkable abdomen
- Adrenal glands, subjectively flattened

INTERPRETATION OF THE FINDINGS & FURTHER RECOMMENDATIONS

Screening for Addison's warranted given the age of the patient and the vague clinical signs. Otherwise, supportive care should prove effective. Other causes of lethargy and anorexia, such as orthopedic/spinal pain, CNS or thoracic disease should be considered.

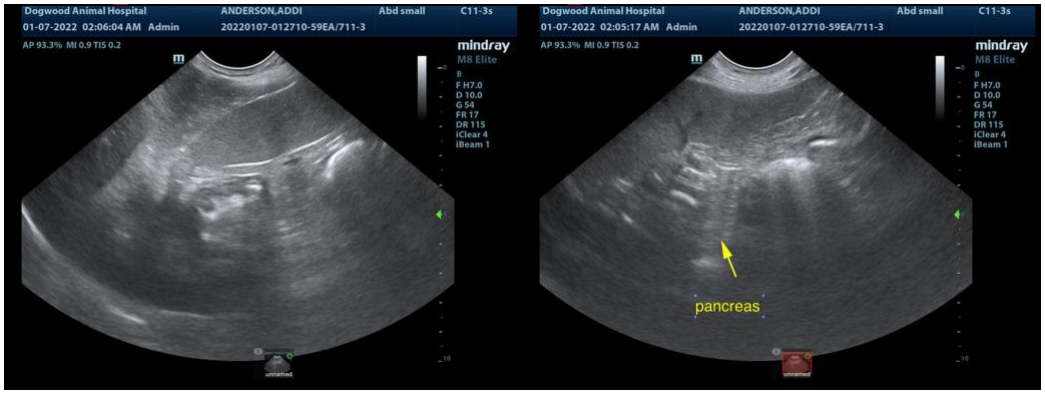

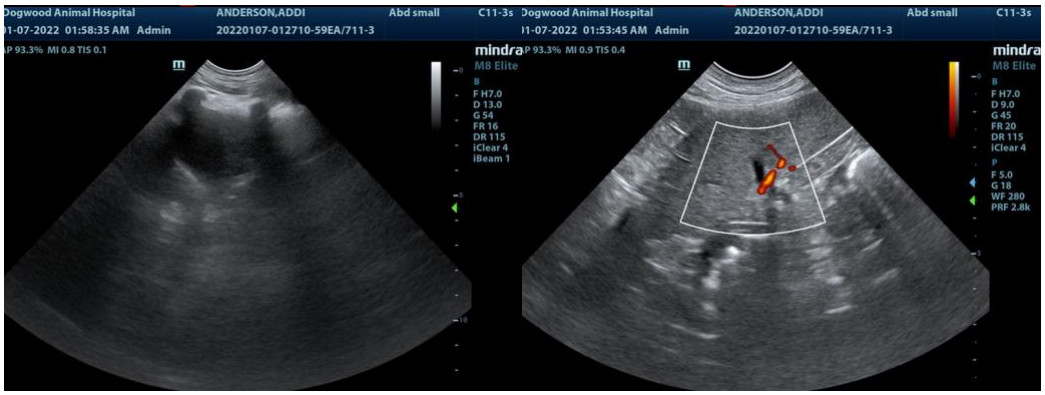

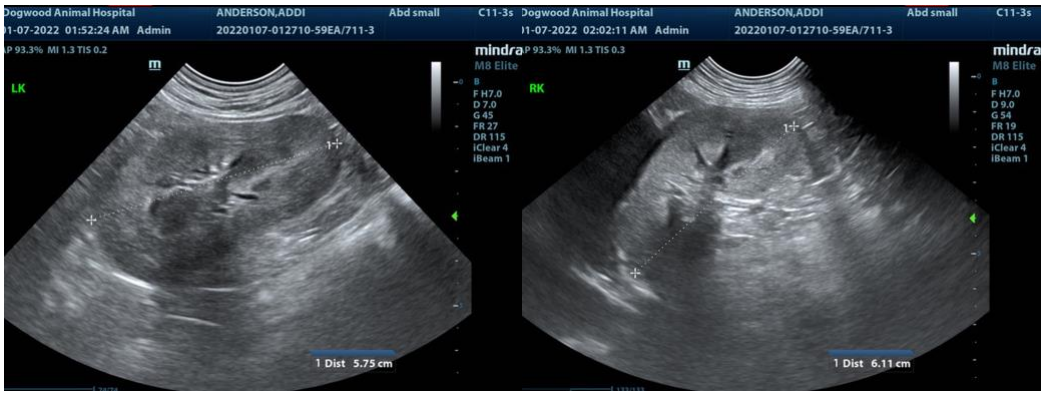

SonoPath

Clinical Sonography & Telecytology

EDUCATIONAL TELECONSULTATION SERVICES™

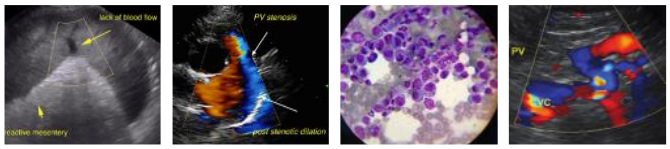

SonoPath.com™
1-800-838-4268 info@sonopath.com

PATIENT

Addi Anderson

SPECIES

Canine

BREED

Springer Spaniel

SEX

Spayed Female

AGE

4 Years

WEIGHT

43 Lbs.

INTERPRETED BY

Eric Lindquist, DMV
DABVP, Cert. IVUSS

IMAGING PERFORMED BY

Ray Caughman

HOSPITAL NAME

Dogwood AH

REFERRING VET

Dr. Ray Caughman

INVOICE

13313

DATE

1/7/22

The information and recommendations provided are based on the images presented by the referring veterinarian. No evaluation can be communicated regarding pathology that was not visible in the image/video clips provided.

Thank you for this referral. If the clinical or image interpretation does not parallel your findings or if I can be of any further assistance please contact me.

Eric Lindquist, DMV, DABVP, Cert. IVUSS, CEO of SonoPath.com
info@SonoPath.com