



PATIENT

Sprinkles Ratliff

SPECIES

Feline

BREED

Domestic Shorthair

SEX

Spayed female

AGE

16 years

WEIGHT

7.7 lbs

INTERPRETED BY

Eric Lindquist, DMV
DABVP, Cert. IVUSS

IMAGING PERFORMED BY

Ashley Whitesell

HOSPITAL NAME

Dickson AC

REFERRING VET

Dr. Rubow

INVOICE

69852

DATE

1/6/26

PRESENTING CLINICAL SIGNS

History: Losing weight over the last few months, Bloodwork WNL

ULTRASONOGRAPHIC EXAMINATION OF THE ABDOMEN

Urinary System

The **urinary bladder**, trigone, and pelvic urethra presented normal thicknesses and normal tone. The pelvic urethra was imaged 2.0 cm beyond the cystourethral junction and appeared normal. No uroliths or sediment were visualized and anechoic urine was present. No evidence of inflammatory or neoplastic changes was noted. Ureteral papillae were normal.

The **kidneys** revealed largely normal size and structure, corticomedullary definition and ratio (cortex 1/3 of medulla) were essentially maintained with some age-related loss of curvilinear patterns regarding the capsule and C/M junction. The cortices presented largely uniform texture with some increased echogenicity expected for this age patient. Medullary structure differed distinctly from that of the cortex. Mineralization was noted in the kidneys. Non-obstructive nephrolithiasis was noted in the right kidney with cortical infarcts. The right kidney measured 3.4 cm. The left kidney measured 5.47 cm with slight pyelectasia and pelvic calculi that measured up to 0.56 cm. The left kidney revealed hydroureter that was dilated to 0.56 cm. The left ureteral dilation cannot be followed to its termination.

Adrenal Glands

The **adrenal glands** were not overtly visualized. However, the regions of the adrenal glands appeared unremarkable.

Spleen

The **spleen** presented a smooth homogeneous parenchyma hyperechoic to liver and renal cortical parenchyma. The capsule was smooth without noticeable expansion or deviation from within the spleen or adjacent pathology. The splenic vasculature demonstrated normal volume without signs of congestion or thrombosis. No sonographic evidence of acute or chronic inflammatory, neoplastic, or infarctual changes was noted.

Liver

The **liver** images from right and left intercostal as well as subcostal views revealed subjectively normal liver size, contour, and structure. Some age-related parenchymal remodeling was noted but likely not clinically significant at this time. Vascular and biliary tracts were of normal volume and no evidence of congestion was noted. The gallbladder presented some dependent debris with essentially normal contour. The cystic and common bile ducts were normal. No overt evidence of active inflammatory, infiltrative or regenerative pathology was noted but should be paired with current or past LE elevations regarding any clinical significance to this presentation. The hepatic lymph nodes were unremarkable.



PATIENT

Sprinkles Ratliff

SPECIES

Feline

BREED

Domestic Shorthair

SEX

Spayed female

AGE

16 years

WEIGHT

7.7 lbs

INTERPRETED BY

Eric Lindquist, DMV
DABVP, Cert. IVUSS

IMAGING PERFORMED BY

Ashley Whitesell

HOSPITAL NAME

Dickson AC

REFERRING VET

Dr. Rubow

INVOICE

69852

DATE

1/6/26

Gastrointestinal

The **gastrointestinal** presentation revealed mild uniform prominence of the gastric mucosa as well as areas of "ropey" small intestinal wall with slight disruption of the normal 1:3 muscularis/mucosal ratio. The intestinal submucosa was slightly irregular, thickened and hyperechoic suggestive of low grade, chronic disease. The mesenteric lymph nodes were reactive.

Pancreas

The base and limbs of the **pancreas** were observed to be largely isoechoic to surrounding omental fat. Pancreatic duct and capsular contour were acceptably normal and parenchyma respected normal curvilinear patterns. No overt evidence of active inflammatory or neoplastic disease was noted.

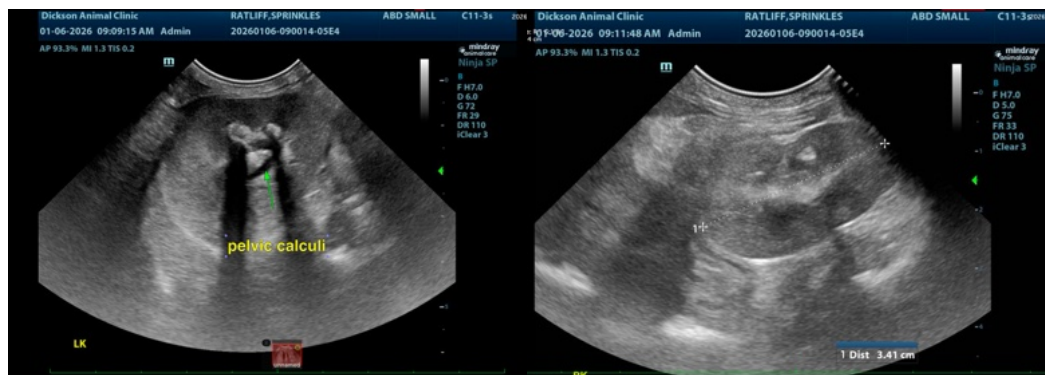
ULTRASONOGRAPHIC FINDINGS

Hydroureter, likely owing to structure or calculus with left renal pelvic calculi.

INTERPRETATION OF THE FINDINGS & FURTHER RECOMMENDATIONS

Surgical intervention is ideal with GI biopsies. There was no overt evidence of neoplasia. Malassimilation of nutrients is a strong potential in this patient. Full urinary work-up and blood pressure measurements are indicated.

Maldigestion panel, three view chest radiographs and full CNS examination is recommended to examine for occult disease that could be responsible for the weight loss. Evaluation for competitive eating environments should also be considered.





PATIENT

Sprinkles Ratliff

SPECIES

Feline

BREED

Domestic Shorthair

SEX

Spayed female

AGE

16 years

WEIGHT

7.7 lbs

INTERPRETED BY

Eric Lindquist, DMV
DABVP, Cert. IVUSS

IMAGING PERFORMED BY

Ashley Whitesell

HOSPITAL NAME

Dickson AC

REFERRING VET

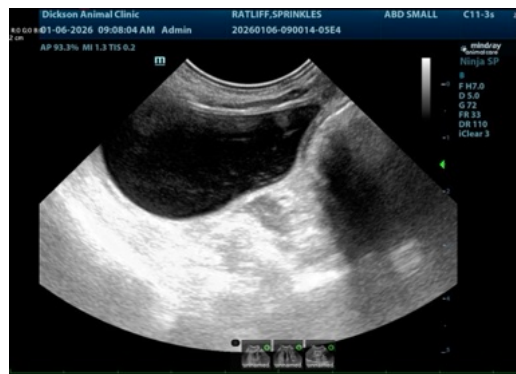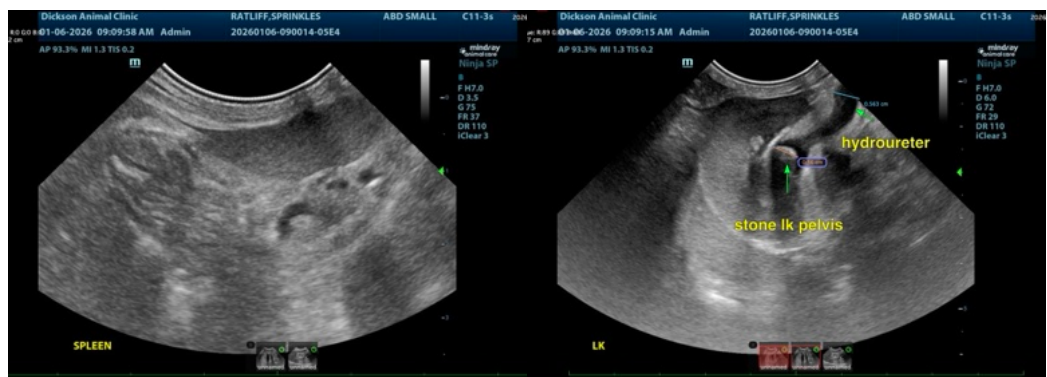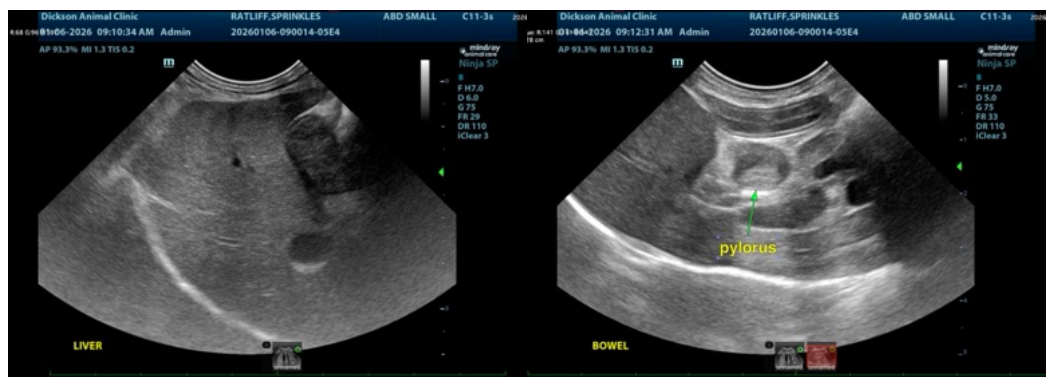
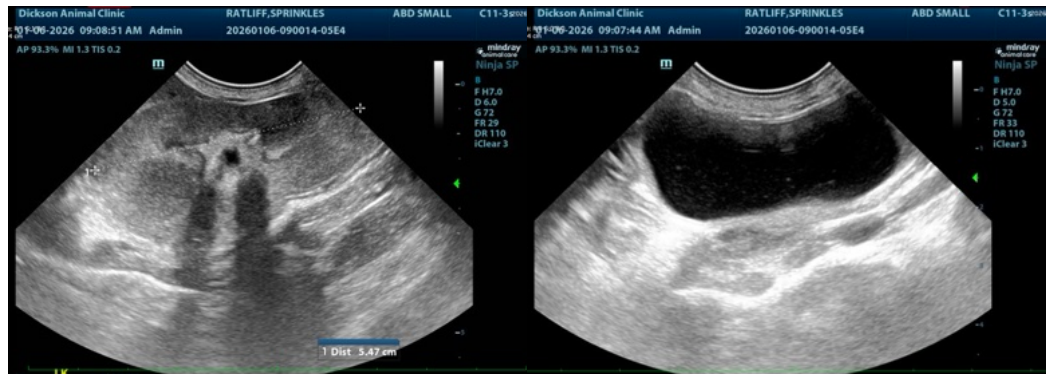
Dr. Rubow

INVOICE

69852

DATE

1/6/26





PATIENT

Sprinkles Ratliff

SPECIES

Feline

BREED

Domestic Shorthair

SEX

Spayed female

AGE

16 years

WEIGHT

7.7 lbs

INTERPRETED BY

Eric Lindquist, DMV
DABVP, Cert. IVUSS

IMAGING PERFORMED BY

Ashley Whitesell

HOSPITAL NAME

Dickson AC

REFERRING VET

Dr. Rubow

INVOICE

69852

DATE

1/6/26

The information and recommendations provided are based on the images presented by the referring veterinarian/sonographer. No evaluation can be communicated regarding pathology that was not visible in the image/video clips provided.

Thank you for this referral. If the clinical or image interpretation does not parallel your findings or if I can be of any further assistance please contact me.

Eric Lindquist, DMV, DABVP (CFM), Cert. IVUSS, CEO of SonoPath.com

info@SonoPath.com