

Clinical Sonography & Telecytology
Educational Teleconsultation Services™

PATIENT
Fiona Gates

SPECIES
Canine

BREED
Boston Terrier

SEX
Female

AGE
6 Months

WEIGHT
11 lbs

INTERPRETED BY
Eric Lindquist, DMV, DABVP (CFM), Cert. IVUSS

IMAGING PERFORMED BY
Dr. Ken Leal

HOSPITAL NAME
Budd Lake Animal Hospital

REFERRING VET
Dr. Horn

INVOICE
72970

DATE
1/6/26

PRESENTING CLINICAL SIGNS

Chronic cough (cough found to be tracheal in origin. (no improvement despite prednisone/cerenia
Grade 2/6 left systolic murmur Normal cardiac X-ray on 11/5/25 Medications: none
Abnormal PE/Chem/CBC/UA Results: Bloodwork all WNL

ULTRASONOGRAPHIC EXAMINATION OF THE HEART

CANINE CARDIAC PARAMETERS	MR VMAX (m/s)	TR VMAX (m/s)	LA/AO (M-Mode)	LA/AO (Heart Base; Swe)	FS (%)	EF (%)	EPSS (cm)
NORMAL PARAMETER	4.5-5.5	<2.7	1.3	Up to 1.6	28-40	40-100	<0.6
PATIENT	--	--	1.0	1.3	49	83	0.2
CANINE CARDIAC PARAMETERS	**HR** (BPM)	**AV VMAX** (m/s)	**PV MAX** (m/s)	**BODY WEIGHT** (lbs)	**LAD** LA MAX 4 Chamber	**LVIDd** Avg; 2D and m-mode short axis (cm)	**LVIDs** Avg; 2D and m-mode short axis (cm)
NORMAL PARAMETER	50-100	0.7-1.7	0.7-1.6				
PATIENT	~90	2.2	1.5	11	2.2	2.09	--

Cardiac Presentation

The echocardiogram in this patient demonstrated normal **left atrial** size based on 3 separate methods of LA evaluation. The cranial and caudal **mitral** valve leaflets presented normal linear structure, extension in systole, and union in diastole with normal kinesis. The **left ventricle** presented thicknesses with linear contour and was not dilated nor restricted. The **myocardium** presented normal echogenicity without subjective evidence of significant fibrotic or ischemic disease. **Contractility** of the ventricular walls was adequate and in normal range for this patient evidenced by the fractional shortening measurement and subjective evaluation of the different regions of the myocardium. The **left ventricular outflow** tract demonstrated slight increased velocity. Periodic arrhythmia note. The **right atrium** and auricle revealed normal size, structure and content. No evidence of masses was noted. **Tricuspid** valvular assessment demonstrated adequate linear morphology and kinesis. The **right ventricle** was of normal size (1/3 diameter of LV), chordae structure, myocardial echogenicity and thickness. **Pulmonary outflow** tract assessment revealed normal valve structure, laminar flow, and diameter (approx.1:1 pa/ao ratio). No visible **pericardial** or free pleura fluid was noted. The cranial **mediastinum and pericardial and extra-cardiac regions** were free of masses in the visible window.

ULTRASONOGRAPHIC FINDINGS

- Normal echocardiogram with idiopathic mild increased LVOT velocity, not clinically significant, and periodic arrhythmia.

PATIENT

Fiona Gates

SPECIES

Canine

BREED

Boston Terrier

SEX

Female

AGE

6 Months

WEIGHT

11 lbs

INTERPRETED BY

Eric Lindquist, DMV, DABVP (CFM), Cert. IVUSS

IMAGING PERFORMED BY

Dr. Ken Leal

HOSPITAL NAME

Budd Lake Animal Hospital

REFERRING VET

Dr. Horn

INVOICE

72970

DATE

1/6/26

INTERPRETATION OF THE FINDINGS & FURTHER RECOMMENDATIONS

Likely idiopathic flow murmur. No evidence of gross congenital pathology noted in this patient. Long lead II ECG indicated. The cough is non-cardiogenic in this patient. No evidence of hemodynamically significant pathology. No contraindication to anesthetic procedure as long as ECG is benign.

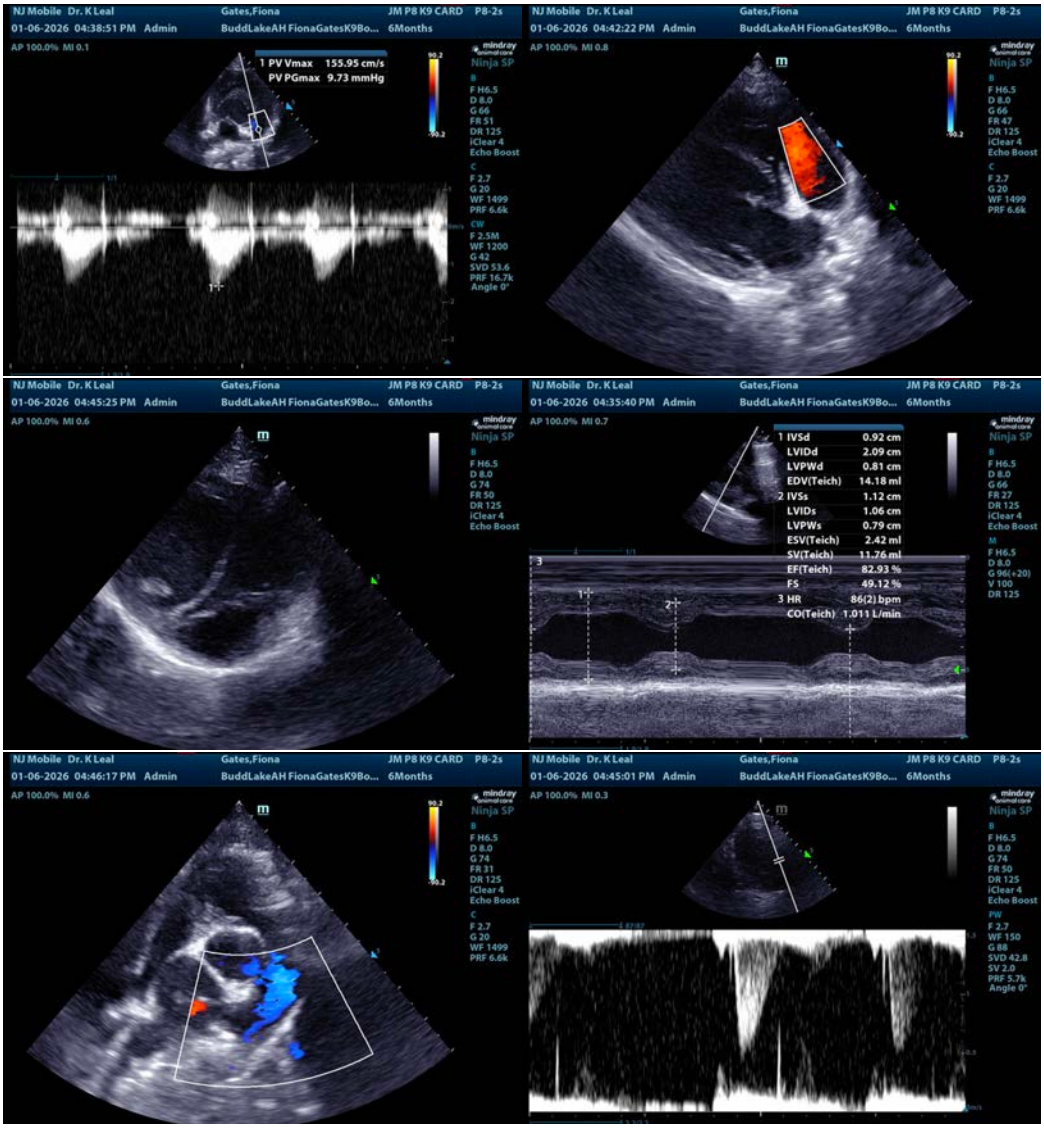

New Jersey Mobile
FUELED BY SONOPATH VETERINARY ULTRASOUND



Clinical Sonography & Telecytology
Educational Teleconsultation Services™

SonoPath
www.SonoPath.com
info@sonopath.com 800.838.4268

PATIENT

Fiona Gates

SPECIES

Canine

BREED

Boston Terrier

SEX

Female

AGE

6 Months

WEIGHT

11 lbs

INTERPRETED BY

Eric Lindquist, DMV, DABVP (CFM), Cert. IVUSS

IMAGING PERFORMED BY

Dr. Ken Leal

HOSPITAL NAME

Budd Lake Animal Hospital

REFERRING VET

Dr. Horn

INVOICE

72970

DATE

1/6/26

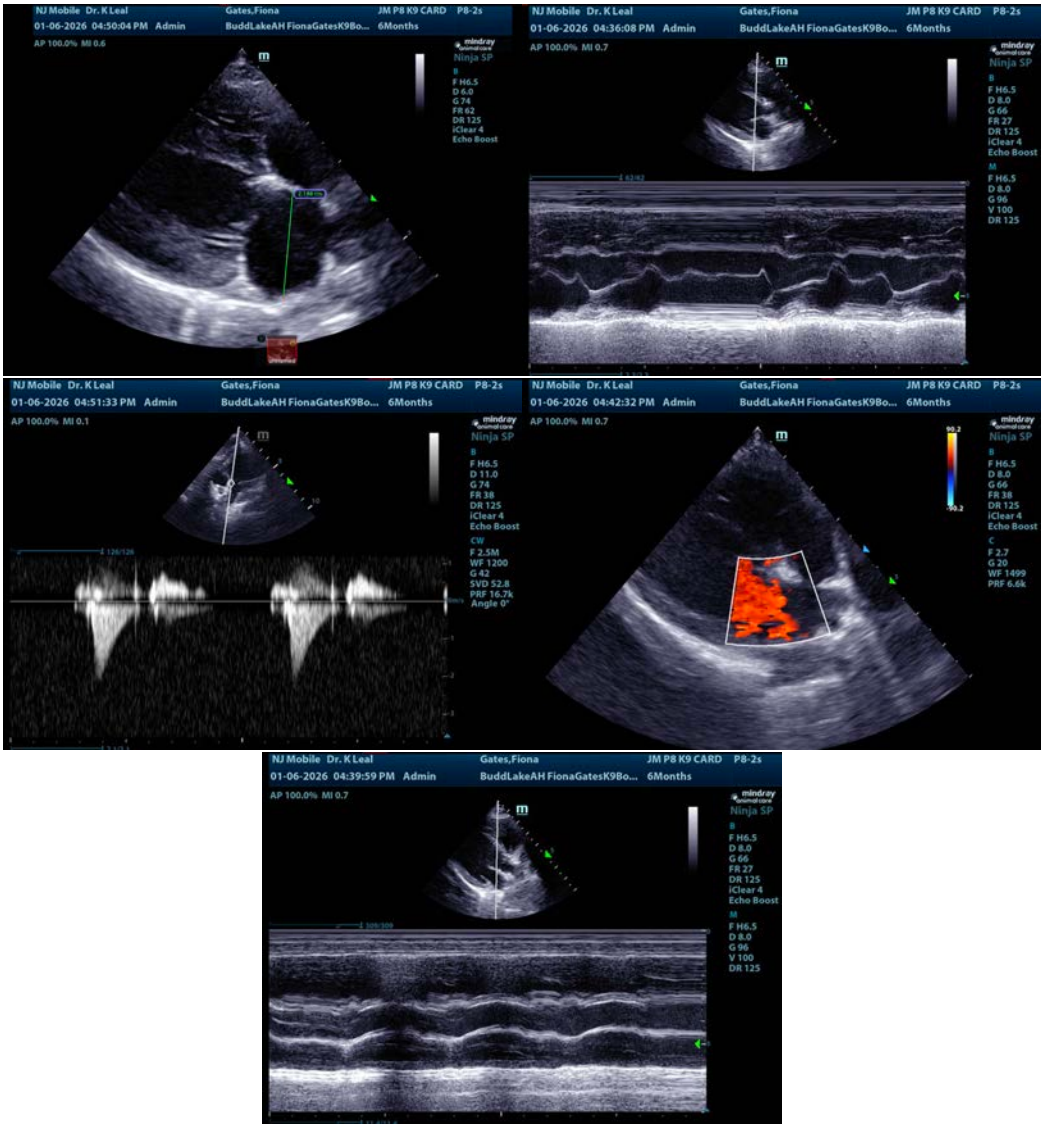

The information and recommendations provided are based on the images presented by the referring veterinarian/sonographer. No evaluation can be communicated regarding pathology that was not visible in the image/video clips provided.

Thank you for this referral. If the clinical or image interpretation does not parallel your findings or if I can be of any further assistance please contact me.

Eric Lindquist, DMV, DABVP(CFM), Cert. IVUSS,
CEO, Owner, Founder -- SonoPath.com
info@SonoPath.com