

Clinical Sonography & Telecytology
Educational Teleconsultation Services™

PATIENT
Edward Simon

SPECIES
Feline

BREED
DSH

SEX
Neutered Male

AGE
6 Years

WEIGHT
Not Provided

INTERPRETED BY
Eric Lindquist, DMV, DABVP (CFM), Cert. IVUSS

IMAGING PERFORMED BY
Kerri Becker

HOSPITAL NAME
Northvale Vet

REFERRING VET
Dr. Simon

INVOICE
72969

DATE
1/6/26

PRESENTING CLINICAL SIGNS

HX of pyelonephritis oct. 2025 treated on zenaquin for 2 weeks- symptoms returned after abx d/c- has been on zenaquin for 5 weeks- doing great clinically. Zenaquin 25mg 1.5 tab sid 5 weeks.

Abnormal PE/Chem/CBC/UA Results: 1/6/26 and 12/18/25 Purrfect(sdma-10 creat-1.4 bun-25) 12/2/25- SDMA-18 creat 2.5 bun-32 12/6/25-SDMA-10 Creat-1.4 BUN-33

ULTRASONOGRAPHIC EXAMINATION OF THE ABDOMEN

Urinary System

The **urinary bladder**, trigone, and pelvic urethra presented normal thicknesses and normal tone. The ureters were not visible which is normal. No uroliths or sediment were visualized. Minimal amount of urine present at the time of the sonogram. No evidence of inflammatory or neoplastic changes were noted. Ureteral papillae were normal.

The **left kidney** presented residual mild to moderate degenerative changes with slight irregular contour, yet no pericapsular inflammatory pattern noted. Appears to be stabilized. The left kidney measured 3.95 cm.

The **right kidney** appears stable. No evidence of active inflammation. The right kidney measured 4.2 cm.

Adrenal Glands

Both **adrenal glands** were visualized and recognized as having normal shape, size, position and echogenicity for this breed. The phrenic vasculature, glandular echogenicity and detail were unremarkable. Capsule, cortex, and medullary definition were normal for this age patient. Right measured 0.38 cm. Left measured 0.34 cm.

Spleen

The **spleen** presented a smooth homogeneous parenchyma hyperechoic to liver and renal cortical parenchyma. The capsule was smooth without noticeable expansion or deviation from within the spleen or adjacent pathology. The splenic vasculature demonstrated normal volume without signs of congestion or thrombosis. No sonographic evidence of acute or chronic inflammatory, neoplastic, or infarctual changes were noted.

Liver

The **liver** images submitted revealed subjectively normal liver size, contour, and structure. Parenchymal echogenicity was naturally coarse and hypoechoic to the spleen. Vascular and biliary tracts were of normal volume with no evidence of congestion. The gallbladder presented acceptably thin walls with primarily anechoic content. The cystic and common bile ducts were normal. No pathological hepatic lymphadenopathy was evident. No overt structural evidence of inflammatory, infiltrative or regenerative pathology was evident.

Gastrointestinal

Examination of the **gastrointestinal tract** revealed a stomach and intestine free of stasis, of normal wall thickness, acceptable curvilinear mural detail, and peristaltic activity. Small and large intestine demonstrated normal luminal chyme and stool consistency respectively. No obstructive or overt infiltrative disease was noted. No associated abnormal lymphatic activity was noted.

PATIENT

Edward Simon

SPECIES

Feline

BREED

DSH

SEX

Neutered Male

AGE

6 Years

WEIGHT

Not Provided

INTERPRETED BY

Eric Lindquist, DMV, DABVP (CFM), Cert. IVUSS

IMAGING PERFORMED BY

Kerri Becker

HOSPITAL NAME

Northvale Vet

REFERRING VET

Dr. Simon

INVOICE

72969

DATE

1/6/26

Pancreas

The base and limbs of the **pancreas** were observed to be largely isoechoic to surrounding omental fat. Pancreatic duct and capsular contour were acceptably normal and parenchyma respected normal curvilinear patterns. No overt evidence of active inflammatory or neoplastic disease was noted.

ULTRASONOGRAPHIC FINDINGS

- Stabilized kidneys with mild to moderate degenerative changes on the left and mild on the right.

INTERPRETATION OF THE FINDINGS & FURTHER RECOMMENDATIONS

Recommend further management based on renal values and any inflammatory sediment. If any inflammatory sediment is present in the urine, then repeat culture would be indicated. Geriatric or renal oriented diet indicated. However, from a sonographic standpoint the patient appears to have stabilized.

For an additional charge an internal medicine consult can be utilized through Sonopath.com. You can select the internal medicine drop down at http://spa.sonopath.com/.

One of the world's top internists & SonoPath associate Dr. Remo Lobetti BVSc, MMedVet, PhD, DECVIM can evaluate your case through SonoPath. https://sonopath.com/resources/sonopath-services/internal-medicine-teleconsultation-services

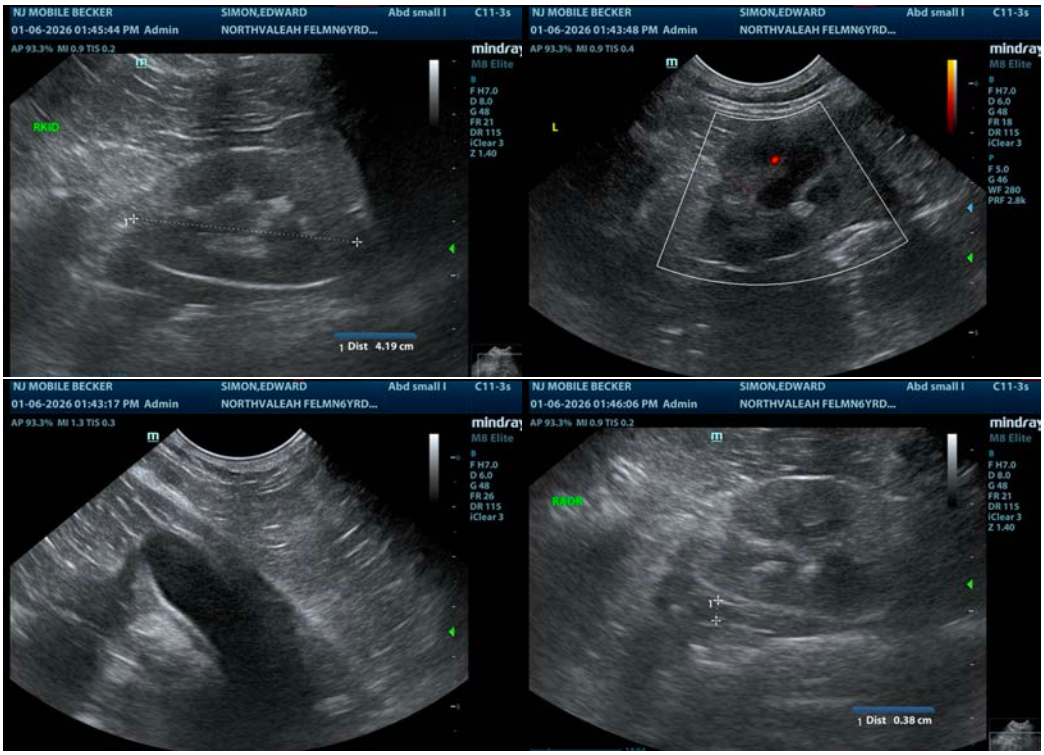

New Jersey Mobile
FUELED BY SONOPATH VETERINARY ULTRASOUND

SonoPath
www.SonoPath.com
info@sonopath.com 800.838.4268



Clinical Sonography & Telecytology
Educational Teleconsultation Services™

PATIENT

Edward Simon

SPECIES

Feline

BREED

DSH

SEX

Neutered Male

AGE

6 Years

WEIGHT

Not Provided

INTERPRETED BY

Eric Lindquist, DMV, DABVP (CFM), Cert. IVUSS

IMAGING PERFORMED BY

Kerri Becker

HOSPITAL NAME

Northvale Vet

REFERRING VET

Dr. Simon

INVOICE

72969

DATE

1/6/26

The information and recommendations provided are based on the images presented by the referring veterinarian/sonographer. No evaluation can be communicated regarding pathology that was not visible in the image/video clips provided.

Thank you for this referral. If the clinical or image interpretation does not parallel your findings or if I can be of any further assistance please contact me.

Eric Lindquist, DMV, DABVP(CFM), Cert. IVUSS,
CEO, Owner, Founder -- SonoPath.com
info@SonoPath.com