



PATIENT

Charlie Hasty

SPECIES

Canine

BREED

Bichon Frise

SEX

Neutered Male

AGE

13 Years 9 Months

WEIGHT

12.2 lbs

INTERPRETED BY

Eric Lindquist, DMV,
DABVP (CFM), Cert.
IVUSS

IMAGING PERFORMED BY

Ashley Whitesell

HOSPITAL NAME

Dickson Animal Clinic

REFERRING VET

Dr. Richard Hovis

INVOICE

72983

DATE

1/6/26

PRESENTING CLINICAL SIGNS

Combined Echocardiogram and abdominal ultrasound- Owners noticed heart racing and appears to have gallop rhythm - radiographs ok - past history of ALT 1,247 on 5-6-2025 now ALT normal - current medications - Prednisone 1 mg once a day Pentoxifylline 400mg 1/4 BID Atopica once weekly - forgets some Farmers Dog Breath stinks so add clindamycin 150mg once a day not doing but can refill Nexgard plus will have gabapentin 100mg and trazodone 100mg on board systolic was 170 mmHg last night HR 144 bpm

ULTRASONOGRAPHIC EXAMINATION OF THE HEART & ABDOMEN

CANINE CARDIAC PARAMETERS	MR VMAX (m/s)	TR VMAX (m/s)	LA/AO (M-Mode)	LA/AO (Heart Base; Swe)	FS (%)	EF (%)	EPSS (cm)
NORMAL PARAMETER	4.5-5.5	<2.7	1.3	Up to 1.6	28-40	40-100	<0.6
PATIENT	--	--	1.3	--	45	90	0.1
CANINE CARDIAC PARAMETERS	HR (BPM)	AV VMAX (m/s)	PV MAX (m/s)	BODY WEIGHT (lbs)	LAD LA MAX 4 Chamber	LVIDd Avg; 2D and m-mode short axis (cm)	LVIDs Avg; 2D and m-mode short axis (cm)
NORMAL PARAMETER	50-100	0.7-1.7	0.7-1.6				
PATIENT	80	1.0	1.3	12.2	2.0	1.66	--

Cardiac Presentation

The echocardiogram in this patient demonstrated normal left atrial size based on 3 separate methods of LA evaluation. Trivial mitral insufficiency noted on color flow assessment. The left ventricle presented thicknesses with linear contour and was not dilated nor restricted. The myocardium presented normal echogenicity without subjective evidence of significant fibrotic or ischemic disease. Contractility of the ventricular walls was adequate and in normal range for this patient evidenced by the fractional shortening measurement and subjective evaluation of the different regions of the myocardium. The left ventricular outflow tract demonstrated normal laminar flow and subjective structural integrity. A vegetative lesion was noted in the septal aspect of the right atrium, measuring 0.76 cm x 0.74 cm. The lesion appeared to expand to a 1.5 cm x 1.9 cm area in the right atrium continuing into the right ventricle. The mass appears to be deriving from the myocardium. Tricuspid insufficiency noted on color flow assessment. Pulmonary outflow tract assessment revealed normal valve structure, laminar flow, and diameter (approx. 1:1 pa/ao ratio). No visible pericardial or free pleura fluid was noted. The cranial mediastinum and pericardial and extra-cardiac regions were free of masses in the visible window.

Urinary System

The **urinary bladder** revealed a grouping of small calculi and sand measuring up to 1.1 cm.

The **kidneys** revealed largely normal size and structure, corticomedullary definition and ratio (cortex 1/3 of medulla) were essentially maintained with some age-related loss of curvilinear patterns regarding



PATIENT

Charlie Hasty

SPECIES

Canine

BREED

Bichon Frise

SEX

Neutered Male

AGE

13 Years 9 Months

WEIGHT

12.2 lbs

INTERPRETED BY

Eric Lindquist, DMV,
DABVP (CFM), Cert.
IVUSS

IMAGING PERFORMED BY

Ashley Whitesell

HOSPITAL NAME

Dickson Animal Clinic

REFERRING VET

Dr. Richard Hovis

INVOICE

72983

DATE

1/6/26

the capsule and C/M junction. The cortices presented largely uniform texture with some increased echogenicity expected for his age patient. Medullary structure differed distinctly from that of the cortex and no evidence of pelvic dilation was present. Pinpoint mineralization noted in the kidneys. The left kidney measured 4.0 cm. Blood flow to the kidneys appeared to be adequate on power doppler assessment.

Adrenal Glands

Both **adrenal glands** were visualized and recognized as having normal shape, size, position and echogenicity for this breed. The phrenic vasculature, glandular echogenicity and detail were unremarkable. Capsule, cortex, and medullary definition were normal for this age patient. Right measured 0.37 cm at the caudal pole and 0.80 cm at the cranial pole. Left measured 0.39 cm at the caudal pole and 0.30 cm at the cranial pole.

Spleen

The **spleen** presented multifocal hyperechoic myelolipomas, not overtly pathological.

Liver

The **liver** images from right and left intercostal as well as subcostal views revealed subjectively normal liver size, contour, and structure. Some age-related parenchymal remodeling was noted but likely not clinically significant at this time. Vascular and biliary tracts were of normal volume and no evidence of congestion was noted. The gallbladder presented some dependent debris with essentially normal contour. The cystic and common bile ducts were normal. No overt evidence of active inflammatory, infiltrative or regenerative pathology was noted but should be paired with current or past LE elevations regarding any clinical significance to this presentation. The hepatic lymph nodes were unremarkable.

Gastrointestinal

Minor retention of ingesta noted in the **stomach**. The small intestines and colon were unremarkable with normal curvilinear mural patterns and content.

Pancreas

The base and limbs of the **pancreas** were observed to be largely isoechoic to surrounding omental fat. Pancreatic duct and capsular contour were acceptably normal and parenchyma respected normal curvilinear patterns. No overt evidence of active inflammatory or neoplastic disease was noted.

ULTRASONOGRAPHIC FINDINGS

- Right ventricular/right atrial myocardial mass – suspect myocardial sarcoma.
- Trivial valvular disease.
- Minor urinary bladder sand.
- Splenic myelolipomas.
- Age related renal changes with mineralization, moderate.
- Age related hepatic changes.
- Minor gastric ingesta.

INTERPRETATION OF THE FINDINGS & FURTHER RECOMMENDATIONS

The myocardial mass does not appear to be causing an obstructive outflow at this time. Cardio-oncological evaluation recommended. Chest radiographs warranted. Blood pressure and holter monitor would be indicated. Note that the Prednisone may be suppressing a more significant presentation.



PATIENT

Charlie Hasty

SPECIES

Canine

BREED

Bichon Frise

SEX

Neutered Male

AGE

13 Years 9 Months

WEIGHT

12.2 lbs

INTERPRETED BY

Eric Lindquist, DMV,
DABVP (CFM), Cert.
IVUSS

**IMAGING
PERFORMED BY**

Ashley Whitesell

HOSPITAL NAME

Dickson Animal Clinic

REFERRING VET

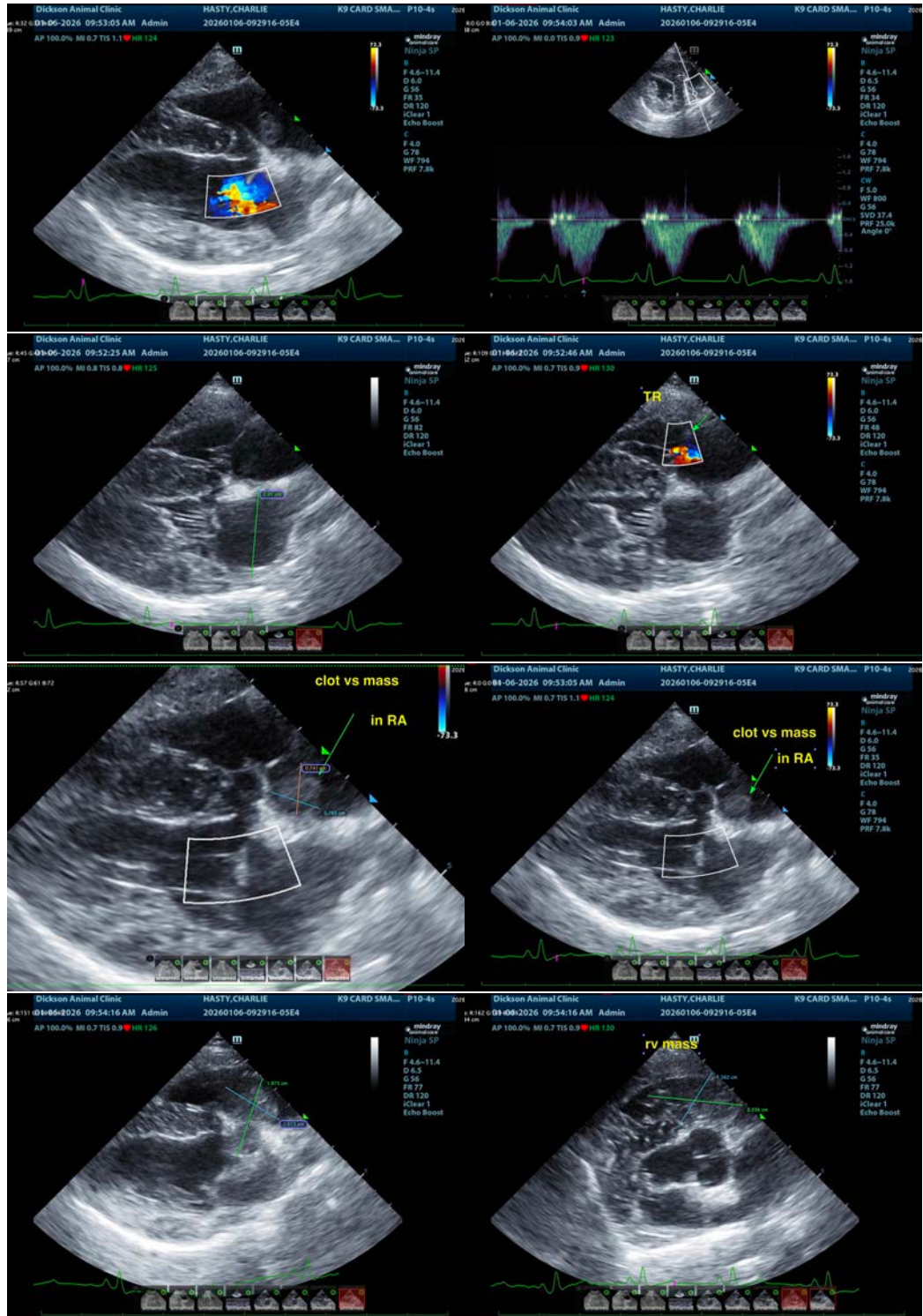
Dr. Richard Hovis

INVOICE

72983

DATE

1/6/26





PATIENT

Charlie Hasty

SPECIES

Canine

BREED

Bichon Frise

SEX

Neutered Male

AGE

13 Years 9 Months

WEIGHT

12.2 lbs

INTERPRETED BY

Eric Lindquist, DMV,
DABVP (CFM), Cert.
IVUSS

**IMAGING
PERFORMED BY**

Ashley Whitesell

HOSPITAL NAME

Dickson Animal Clinic

REFERRING VET

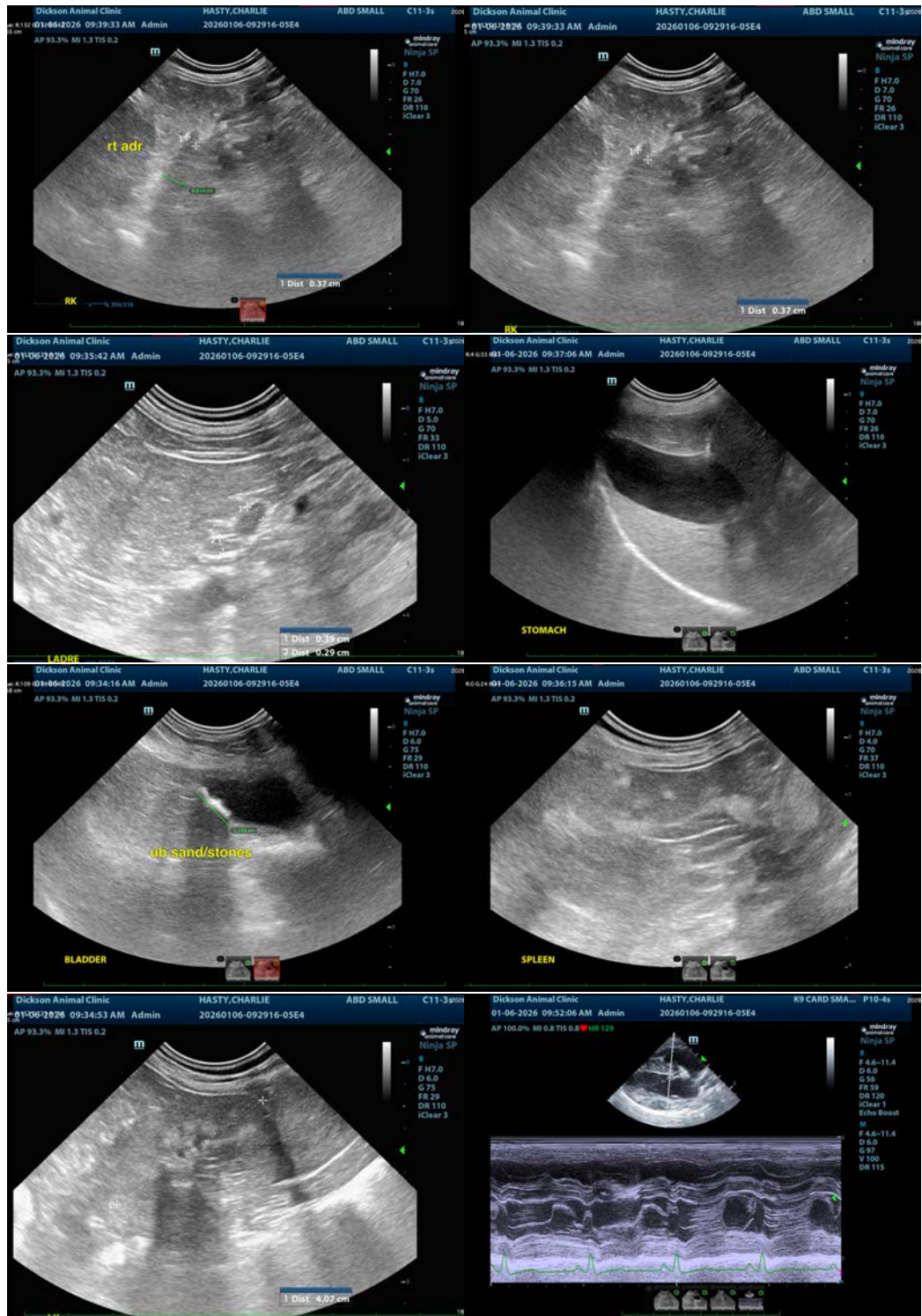
Dr. Richard Hovis

INVOICE

72983

DATE

1/6/26





PATIENT

Charlie Hasty

SPECIES

Canine

BREED

Bichon Frise

SEX

Neutered Male

AGE

13 Years 9 Months

WEIGHT

12.2 lbs

INTERPRETED BY

Eric Lindquist, DMV,
DABVP (CFM), Cert.
IVUSS

IMAGING PERFORMED BY

Ashley Whitesell

HOSPITAL NAME

Dickson Animal Clinic

REFERRING VET

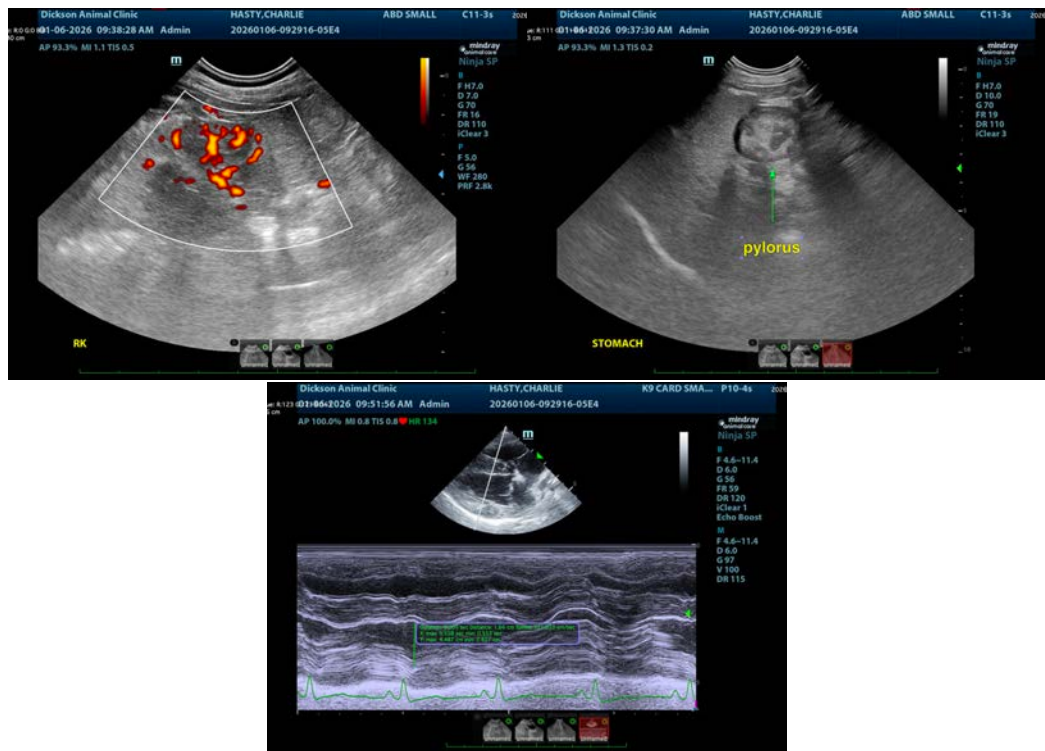
Dr. Richard Hovis

INVOICE

72983

DATE

1/6/26



The information and recommendations provided are based on the images presented by the referring veterinarian/sonographer. No evaluation can be communicated regarding pathology that was not visible in the image/video clips provided.

Thank you for this referral. If the clinical or image interpretation does not parallel your findings or if I can be of any further assistance please contact me.

Eric Lindquist, DMV, DABVP(CFM), Cert. IVUSS,
CEO, Owner, Founder -- SonoPath.com
info@SonoPath.com