



PATIENT

Zero Diggs

SPECIES

Canine

BREED

Husky Mix

SEX

Spayed female

AGE

5 years

WEIGHT

115 lbs

PRESENTING CLINICAL SIGNS

History: recheck prev u/s 1/4 showed shadowing gastric material poss fb or medications

ULTRASONOGRAPHIC EXAMINATION OF THE ABDOMEN

Gastrointestinal

The stomach in this patient revealed progressively shadowing material. If the patient was n.p.o. then soft foreign matter is suspected.

The remainder of the abdomen is similar to the previous sonogram.

ULTRASONOGRAPHIC FINDINGS

Full stomach.

Soft foreign matter or post prandial presentation.

INTERPRETATION OF THE FINDINGS & FURTHER RECOMMENDATIONS

The sonographic appearance should be paired with feeding history in this patient as the material could be consistent with ingesta or soft foreign matter.

INTERPRETED BY

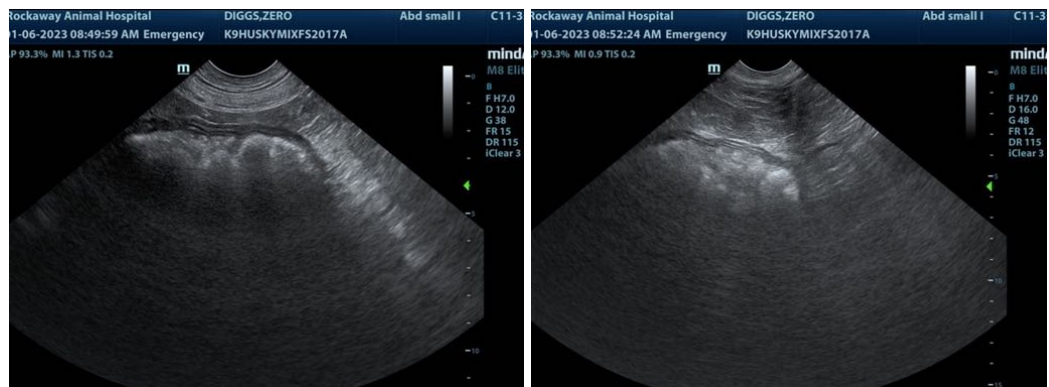
Eric Lindquist, DMV
DABVP, Cert. IVUSS

IMAGING PERFORMED BY

Jenn

HOSPITAL NAME

Rockaway



REFERRING VET

Dr. Maniar

The information and recommendations provided are based on the images presented by the referring veterinarian/sonographer. No evaluation can be communicated regarding pathology that was not visible in the image/video clips provided.

INVOICE

42561

Thank you for this referral. If the clinical or image interpretation does not parallel your findings or if I can be of any further assistance please contact me.

DATE

1/6/23

Eric Lindquist, DMV, DABVP, Cert. IVUSS, CEO of SonoPath.com
info@SonoPath.com