



PATIENT PRESENTING CLINICAL SIGNS

Zak Smith Liver enzymes elevation last ultrasound was done 6/8/22.
Abnormal PE/Chem/CBC/UA Results: ALT 288, ALKP 512, Triglycerides 588, CPK \$*Urine pH 5.0.

SPECIES ULTRASONOGRAPHIC EXAMINATION OF THE ABDOMEN

Canine **Urinary System**

BREED The **urinary bladder**, trigone, and pelvic urethra presented normal thicknesses and normal tone. The ureters were not visible which is normal. No uroliths or sediment were visualized and anechoic urine was present. No evidence of inflammatory or neoplastic changes were noted. Ureteral papillae were normal.

Tibetan Terrier

SEX The **kidneys** revealed largely normal size and structure, corticomedullary definition and ratio (cortex 1/3 of medulla) were essentially maintained with some age-related loss of curvilinear patterns regarding the capsule and C/M junction. The cortices presented largely uniform texture with some increased echogenicity expected for his age patient. Medullary structure differed distinctly from that of the cortex and no evidence of pelvic dilation was present. The left kidney measured 4.7 cm. The right kidney measured 4.58 cm.

Neutered Male

AGE **Adrenal Glands**

14 Years

WEIGHT Both **adrenal glands** were visualized and recognized as having normal shape, size, position and echogenicity for this breed. The phrenic vasculature, glandular echogenicity and detail were unremarkable. Capsule, cortex, and medullary definition were normal for this age patient. The left adrenal gland measures 1.95 cm x 0.60 cm at the caudal pole and 0.53 cm at the cranial pole. The right adrenal gland measures 1.66 cm x 0.52 cm at the cranial pole and 0.53 cm at the caudal pole.

22.2 Pounds

INTERPRETED BY Spleen

Eric Lindquist, DMV The **spleen** presented a smooth homogeneous parenchyma hyperechoic to liver and renal cortical parenchyma. The capsule was smooth without noticeable expansion or deviation from within the spleen or adjacent pathology. The splenic vasculature demonstrated normal volume without signs of congestion or thrombosis. No sonographic evidence of acute or chronic inflammatory, neoplastic, or infarctual changes were noted.

DABVP, Cert. IVUSS

IMAGING PERFORMED BY Liver

Marco Lichfield

HOSPITAL NAME The **liver** presented normal size and contour and vascularity. The gallbladder and common bile duct were unremarkable. Minor increased portal markings noted. This is consistent with benign hepatopathy.

Sova Animal Hospital

Gastrointestinal

REFERRING VET Examination of the **gastrointestinal tract** revealed a stomach and intestine free of stasis, of normal wall thickness, acceptable curvilinear mural detail, and peristaltic activity. Small and large intestine demonstrated normal luminal chyme and stool consistency respectively. No obstructive or overt infiltrative disease was noted. No associated abnormal lymphatic activity was noted.

Dr. Sova

INVOICE Pancreas

44045 The base and limbs of the **pancreas** were observed to be largely isoechoic to surrounding omental fat. Pancreatic duct and capsular contour were acceptably normal and parenchyma respected normal curvilinear patterns. No overt evidence of active inflammatory or neoplastic disease was noted.

DATE

1/6/23



PATIENT

Zak Smith

ULTRASONOGRAPHIC FINDINGS

- Benign hepatopathy
- Age related renal changes

SPECIES

Canine

INTERPRETATION OF THE FINDINGS & FURTHER RECOMMENDATIONS

FNA could be considered for further definition of enzyme elevations. However, likely low-grade reactive hepatopathy.

BREED

Tibetan Terrier

The hepatic clinical sonographic presentation is most consistent with Reactive Hepatopathy which is the most common cause of liver enzyme elevation in dogs and cats. The presumption is that gut and other organ antigen stimuli may be causing a low-grade immune response through portal system with which the liver is reacting to causing low-grade enzyme elevations. US-guided FNA could be performed to assess if low grade lymphoplasmacytic inflammation is present that would support this theory. If FNA is performed, please ask the cytologist to emphasize the primary inflammatory cell type. Empirical treatment measures to address this issue can include diet change to hydrolyzed diet, probiotics, deworming, nutraceuticals (SAmE, Actigall...), dental exam and cleaning, and potentially antibiotics such as Clavamox. Metronidazole and Tylosin have traditionally been utilized for this purpose but new studies show that both these antibiotics can disrupt the normal intestinal bacterial flora (intestinal dysbiosis) for weeks and up to 4-6 months. Therefore, Metronidazole and Tylosin should be utilized as a last resort if other efforts have not been effective and sonographic organ appearance remains benign.

SEX

Neutered Male

AGE

14 Years

WEIGHT

22.2 Pounds

INTERPRETED BY

Eric Lindquist, DMV
DABVP, Cert. IVUSS

IMAGING PERFORMED BY

Marco Lichfield

HOSPITAL NAME

Sova Animal Hospital

REFERRING VET

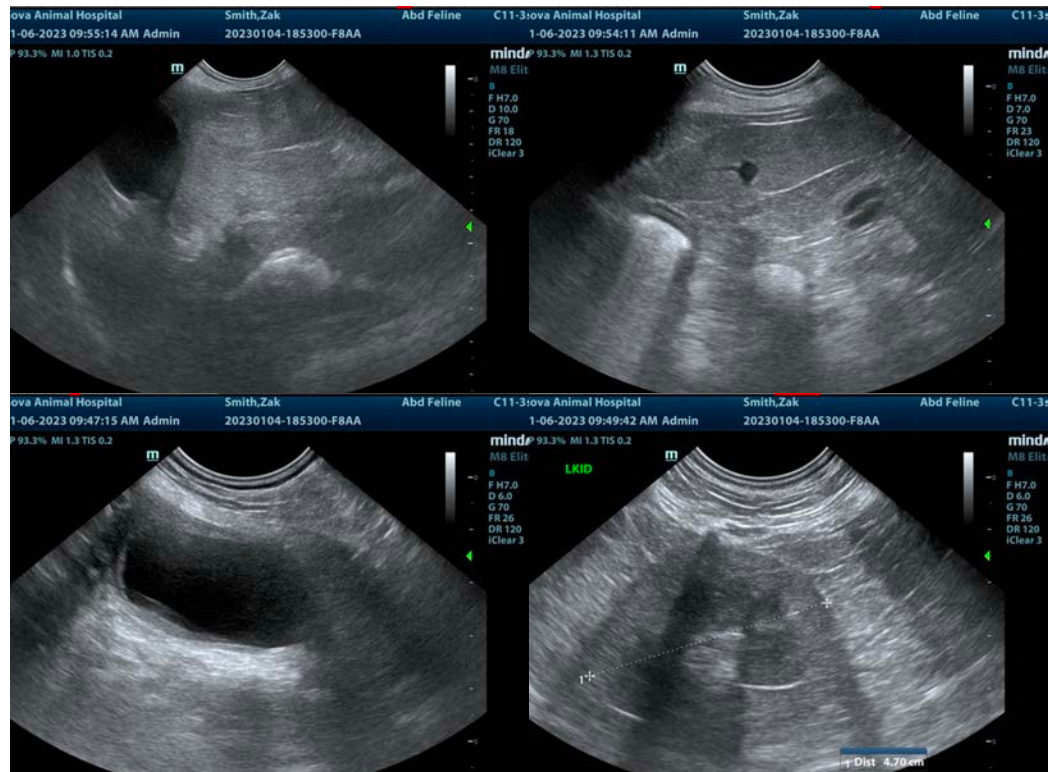
Dr. Sova

INVOICE

44045

DATE

1/6/23





PATIENT

Zak Smith

SPECIES

Canine

BREED

Tibetan Terrier

SEX

Neutered Male

AGE

14 Years

WEIGHT

22.2 Pounds

INTERPRETED BY

Eric Lindquist, DMV

DABVP, Cert. IVUSS

IMAGING PERFORMED BY

Marco Lichfield

HOSPITAL NAME

Sova Animal Hospital

REFERRING VET

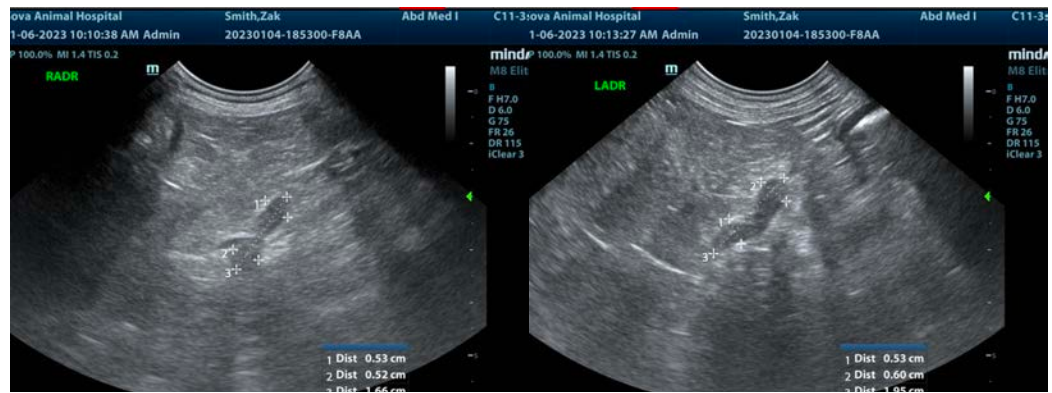
Dr. Sova

INVOICE

44045

DATE

1/6/23



The information and recommendations provided are based on the images presented by the referring veterinarian/sonographer. No evaluation can be communicated regarding pathology that was not visible in the image/video clips provided.

Thank you for this referral. If the clinical or image interpretation does not parallel your findings or if I can be of any further assistance please contact me.

Eric Lindquist, DMV, DABVP, Cert. IVUSS, CEO of SonoPath.com

info@SonoPath.com