



PATIENT

Schatzi Roebel

SPECIES

Canine

BREED

German Shepherd

SEX

Spayed Female

AGE

9 Years

WEIGHT

109.8 Pounds

INTERPRETED BY

Eric Lindquist, DMV
DABVP, Cert. IVUSS

IMAGING PERFORMED BY

Val Shumskaya

HOSPITAL NAME

Riverdale Integrative

REFERRING VET

Dr. Kuo

INVOICE

20429

DATE

1/6/23

PRESENTING CLINICAL SIGNS

History: Owner has concerns for neoplasia, lump on umbilical hernia, unresolving diarrhea Current meds: Supplements

Abnormal PE/Chem/CBC/UA Results: Current B/W pending. Previous B/W showed vitamin D deficiency

ULTRASONOGRAPHIC EXAMINATION OF THE HEART & ABDOMEN

CANINE CARDIAC PARAMETERS	MR VMAX (m/s)	TR VMAX (m/s)	LA/AO (Boon method)	LA/AO (Heart Base; Swe)	FS (%)	EF (%)	EPSS (cm)
NORMAL PARAMETER	4.5-5.5	<2.7	1.3	<1.3	28-40	40-100	<0.6
PATIENT	--	--	1.0	1.3	23	47	0.1
CANINE CARDIAC PARAMETERS	HR (BPM)	AV VMAX (m/s)	PV MAX (m/s)	BODY WEIGHT (kg)	LA 2D short axis Base view (cm)	LVIDd Avg; 2D and m-mode short axis (cm)	LVIDs Avg; 2D and m-mode short axis (cm)
NORMAL PARAMETER	50-100	0.7-1.7	0.7-1.6				
PATIENT	122	1.17	1.04	--	3.7	2.95	--

Cardiac Presentation

The echocardiogram in this patient demonstrated normal **left atrial** size based on 3 separate methods of LA evaluation. Trivial mitral turbulence was noted, not clinically significant. The **left ventricle** presented thicknesses with linear contour and was not dilated nor restricted. The **myocardium** presented normal echogenicity without subjective evidence of significant fibrotic or ischemic disease. **Contractility** of the ventricular walls was adequate and in normal range for this patient evidenced by the fractional shortening measurement and subjective evaluation of the different regions of the myocardium. The **left ventricular outflow** tract demonstrated normal laminar flow and subjective structural integrity. The **right atrium** and auricle revealed normal size, structure and content. No evidence of masses was noted. **Tricuspid** valvular assessment demonstrated adequate linear morphology and kinesis. The **right ventricle** was of normal size (1/3 diameter of LV), chordae structure, myocardial echogenicity and thickness. **Pulmonary outflow** tract assessment revealed normal valve structure, laminar flow, and diameter (approx.1:1 pa/ao ratio). No visible **pericardial** or free pleura fluid was noted. The cranial **mediastinum and pericardial and extra-cardiac regions** were free of masses in the visible window.

Urinary System

The **urinary bladder**, trigone, and pelvic urethra presented normal thicknesses and normal tone. The ureters were not visible which is normal. No uroliths or sediment were visualized, and anechoic urine



PATIENT

Schatzi Roebel

was present. No evidence of inflammatory or neoplastic changes were noted. Ureteral papillae were normal.

SPECIES

Canine

The **kidneys** revealed normal size and structure, corticomedullary definition and ratio for this age. The cortices presented largely uniform texture with normal echogenic relationship to liver and spleen. Medullary structure differed distinctly from the cortex and no evidence of pelvic dilation was present. The capsules were acceptably uniform without significant irregularities. The right kidney measured 7.08 cm. The left kidney measured 3.7 cm.

BREED

German Shepherd

Adrenal Glands

Both **adrenal glands** were visualized and recognized as having normal shape, size, position and echogenicity for this breed. The phrenic vasculature, glandular echogenicity and detail were unremarkable. Capsule, cortex, and medullary definition were normal for this age patient. The right adrenal gland measured 3.09 cm x 0.6 cm at the caudal pole and 0.7 cm at the cranial pole. The left adrenal gland measured 2.97 cm x 0.62 cm at the caudal pole and 0.39 cm at the cranial pole.

SEX

Spayed Female

Spleen

The **spleen** revealed slight heterogenous parenchyma and mild uniform enlargement with splenic fold.

AGE

9 Years

Liver

The **liver** itself was unremarkable. Minor gallbladder debris was noted.

WEIGHT

109.8 Pounds

Gastrointestinal

Examination of the **gastrointestinal tract** revealed a stomach and intestine free of stasis, of normal wall thickness, acceptable curvilinear mural detail, and peristaltic activity. Small and large intestine demonstrated normal luminal chyme and stool consistency respectively. No obstructive or overt infiltrative disease was noted. No associated abnormal lymphatic activity was noted.

INTERPRETED BY

Eric Lindquist, DMV
DABVP, Cert. IVUSS

Pancreas

The base and limbs of the **pancreas** were observed to be largely isoechoic to surrounding omental fat. Pancreatic duct and capsular contour were acceptably normal and parenchyma respected normal curvilinear patterns. No overt evidence of active inflammatory or neoplastic disease was noted.

IMAGING PERFORMED BY

Val Shumskaya

ULTRASONOGRAPHIC FINDINGS

HOSPITAL NAME

Riverdale Integrative

- Minor hypersplenism and benign splenic fold
- Minor gallbladder debris
- Structurally unremarkable abdomen otherwise
- Normal echocardiogram with trivial mitral turbulence- not clinically significant

REFERRING VET

Dr. Kuo

INTERPRETATION OF THE FINDINGS & FURTHER RECOMMENDATIONS

No evidence of visceral or cardiac disease.

INVOICE

20429

DATE

1/6/23



PATIENT

Schatzi Roebel

SPECIES

Canine

BREED

German Shepherd

SEX

Spayed Female

AGE

9 Years

WEIGHT

109.8 Pounds

INTERPRETED BY

Eric Lindquist, DMV
DABVP, Cert. IVUSS

IMAGING PERFORMED BY

Val Shumskaya

HOSPITAL NAME

Riverdale Integrative

REFERRING VET

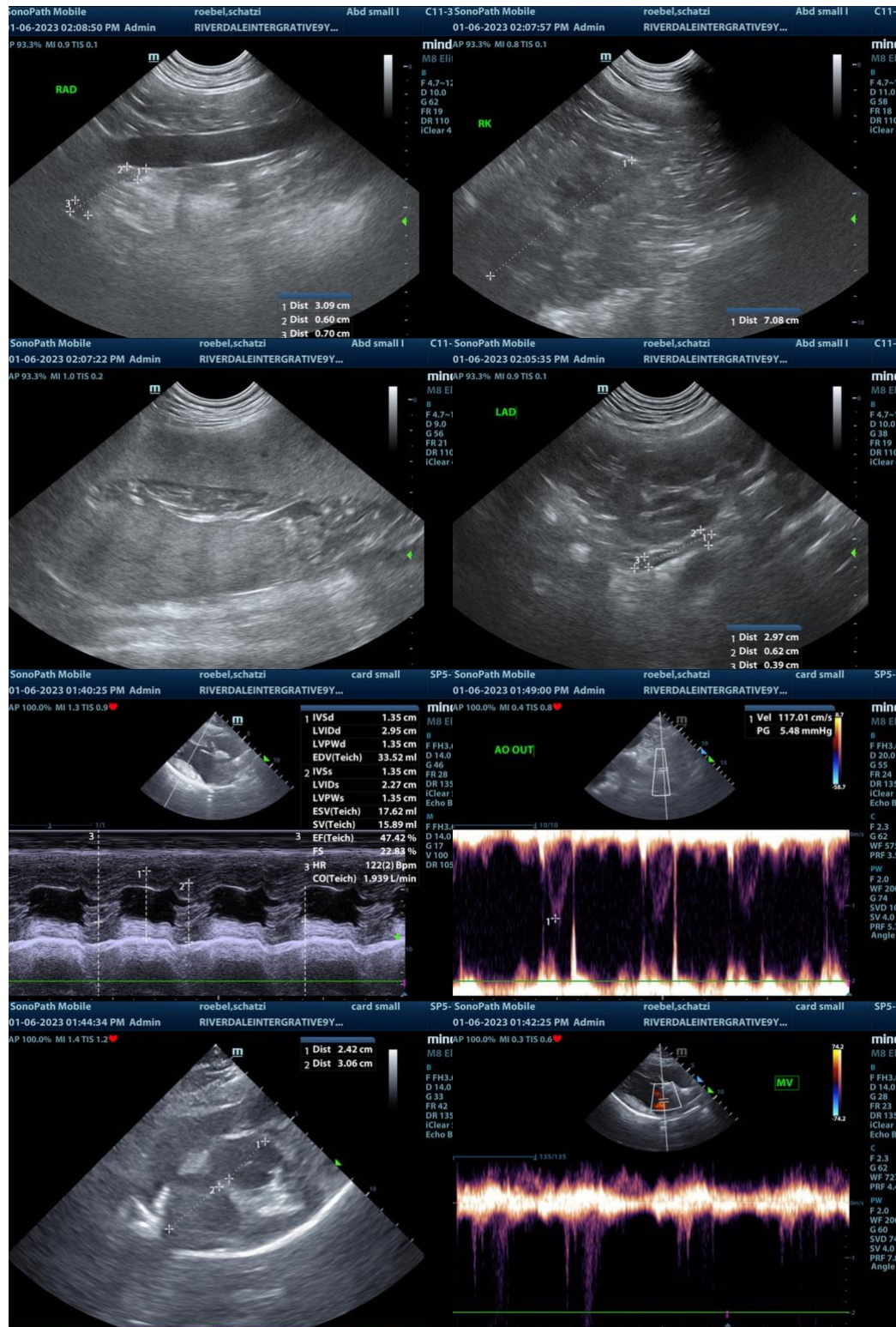
Dr. Kuo

INVOICE

20429

DATE

1/6/23





PATIENT

Schatzi Roebel

SPECIES

Canine

BREED

German Shepherd

SEX

Spayed Female

AGE

9 Years

WEIGHT

109.8 Pounds

INTERPRETED BY

Eric Lindquist, DMV
DABVP, Cert. IVUSS

IMAGING PERFORMED BY

Val Shumskaya

HOSPITAL NAME

Riverdale Integrative

REFERRING VET

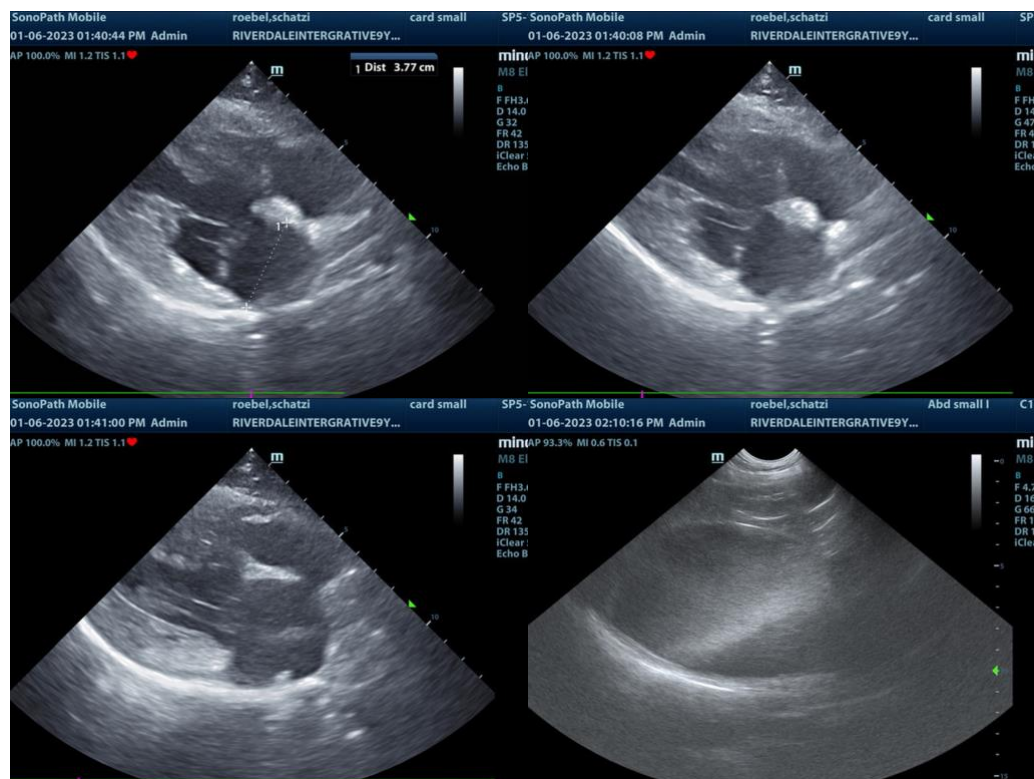
Dr. Kuo

INVOICE

20429

DATE

1/6/23



The information and recommendations provided are based on the images presented by the referring veterinarian. No evaluation can be communicated regarding pathology that was not visible in the image/video clips provided.

Thank you for this referral. If the clinical or image interpretation does not parallel your findings or if I can be of any further assistance please contact me.

Eric Lindquist, DMV, DABVP, Cert. IVUSS, CEO of SonoPath.com
info@SonoPath.com