



PATIENT PRESENTING CLINICAL SIGNS

Lady Witt Seen 10/22 for senior exam, abd palpation non-diagnostic, tense pt, obese -coxofemoral joint reduced ROM, stifle joint reduced ROM and crepitus -sensitivity in hind end, slow to rise, otherwise fairly normal PE -after labs there was concern for hyperparathyroidism, recd US

SPECIES ADDENDUM TO PRIOR THYROID SCAN

Canine

BREED Both thyroid lobes revealed nodular irregular changes. However, the left thyroid presented a more prominent, hypoechoic parathyroid in the mid body of the gland with capsular expansion, measuring 0.35 cm. This is the largest nodule noted and should be monitored. This can be consistent with hyperplasia or early adenoma and should be monitored with eventual ultrasound guided FNA.

Lhasa Apso

SEX

Spayed Female

AGE

9 Years

WEIGHT

19.5 Pounds

ULTRASONOGRAPHIC FINDINGS

- Heterogeneous thyroid glands with prominent left parathyroids – consistent with early adenoma or possible hyperplasia.

INTERPRETATION OF THE FINDINGS & FURTHER RECOMMENDATIONS

Given the minor hypercalcemia, recommend rechecking calcium profile in one month and reassessment of the sonographic +/- FNA if the left parathyroid lesions have expanded, primarily the one that measures 0.35 cm, as this is upper limits of normal for parathyroids themselves. However, the capsular expansion is concerning for potential adenoma.

INTERPRETED BY

Eric Lindquist, DMV
DABVP, Cert. IVUSS

IMAGING PERFORMED BY

Jenna Walsh, CVT

HOSPITAL NAME

VCA Westmoreland

REFERRING VET

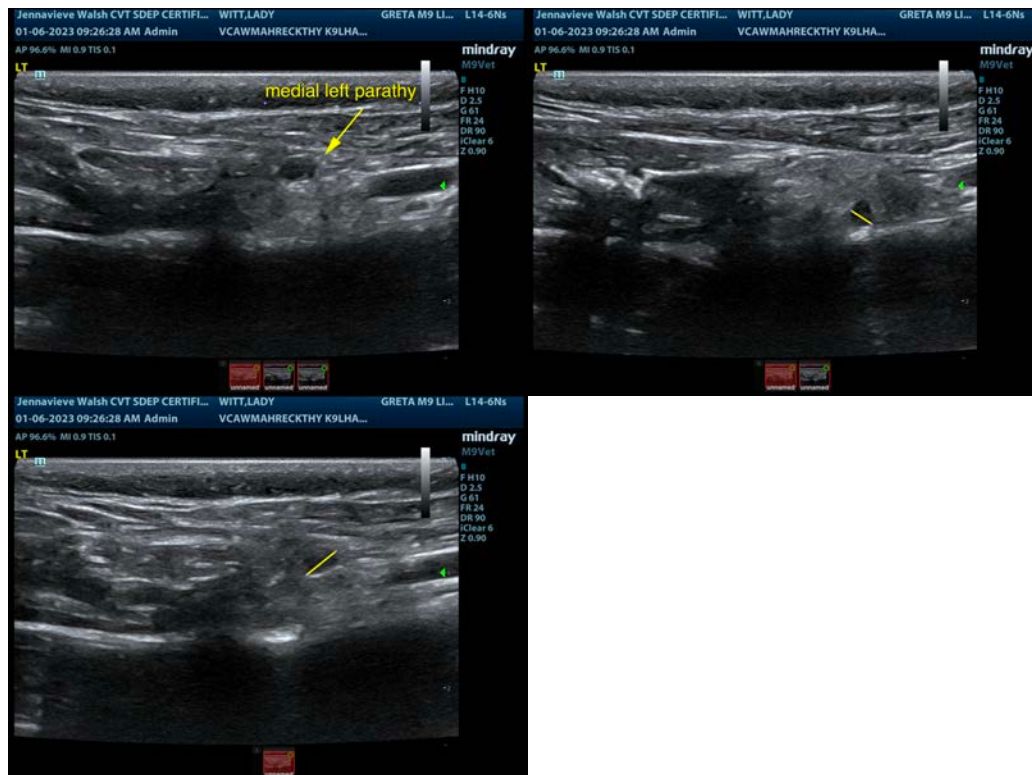
Dr. Sullivan

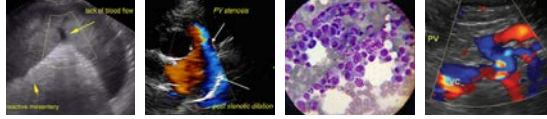
INVOICE

44037

DATE

1/6/23





PATIENT

Lady Witt

The information and recommendations provided are based on the images presented by the referring veterinarian/sonographer. No evaluation can be communicated regarding pathology that was not visible in the image/video clips provided.

SPECIES

Canine

Thank you for this referral. If the clinical or image interpretation does not parallel your findings or if I can be of any further assistance please contact me.

BREED

Lhasa Apso

Kathleen Sennello DVM,MS, Diplomate ACVIM (Small animal Internal Medicine)

kathleen.sennello@sonopath.com

SEX

Spayed Female

AGE

9 Years

WEIGHT

19.5 Pounds

INTERPRETED BY

Eric Lindquist, DMV

DABVP, Cert. IVUSS

**IMAGING
PERFORMED BY**

Jenna Walsh, CVT

HOSPITAL NAME

VCA Westmoreland

REFERRING VET

Dr. Sullivan

INVOICE

44037

DATE

1/6/23