



## PATIENT

Blue Aymar- Smith

## SPECIES

Feline

## BREED

Himalayan/Persian Mix

## SEX

Neutered Male

## AGE

12 Years

## WEIGHT

9.2 Pounds

## PRESENTING CLINICAL SIGNS

History: Patient presents for grade 2/6 heart murmur and coughing. No current meds.

## ULTRASONOGRAPHIC EXAMINATION OF THE HEART

FELINE CARDIAC PARAMETERS	BODY WEIGHT (kg)	HR (BPM)	IVSd (cm)	LVIDd (cm)	LVWd (cm)	FS (%)	EF (%)
<b>NORMAL PARAMETER</b>	-----	150-240	0.3-0.6	1.0-2.1	0.25-0.6	35-67	80-100
<b>PATIENT</b>	--	NM	0.5	1.32	0.67	50	87
FELINE CARDIAC PARAMETERS	LA/AO (Boon)	LA/AO HEART BASE (Sisson)	LA 2D 4-chamber long axis AS to FW (Sisson) (cm)	LVOT VEL. (m/s)	RVOT VEL. (m/s)	IVRT (m/)	
<b>NORMAL PARAMETER</b>	<1.5	0.88-1.79	0.7-1.7	<1.6	<1.3	40-60	
<b>PATIENT</b>	>2.2	2.0	1.8	1.00	.70	NM	

Adapted from June Boon, Veterinary Echocardiography, 1998  
Sisson D et al. JVIM 1991; 5: 232, Jacobs et al. Am J Vet Res 1985; 46:1705

## Cardiac Presentation

The cardiac presentation in this patient presented severe volume overload of the left atrium, left ventricle and right atrium with pericardial effusion. Mitral and tricuspid insufficiency were present. Septal and free wall thicknesses were normal. Hepatic veins were dilated. No overt neoplasia was present, however, the right auricle was slightly irregular.

## ULTRASONOGRAPHIC FINDINGS

- Left and right sided cardiac failure
- Irregular right auricle
- Pericardial effusion

## INTERPRETATION OF THE FINDINGS & FURTHER RECOMMENDATIONS

Changes are consistent with unclassified cardiomyopathy with left and right sided failure and secondary pericardial effusion with possibility of an underlying neoplastic event. There is no tamponade effect from the pericardial effusion, therefore drainage is not necessary. I recommend treating for left and right sided failure, abdominal sonogram and recheck echocardiogram in approximately 2 weeks. Pimobendan off-label 0.3 mg/kg BID, Ace-inhibitor 0.5 mg/kg SID, Lasix 6.25 mg BID and Plavix therapy are also indicated. Monitoring BUN, creatinine, blood pressures and body temperature recommended. Prognosis is very guarded.

## INTERPRETED BY

Eric Lindquist, DMV  
DABVP, Cert. IVUSS

## IMAGING PERFORMED BY

Kelly Vazquez

## HOSPITAL NAME

Veterinary Wellness,  
Glen Rock

## REFERRING VET

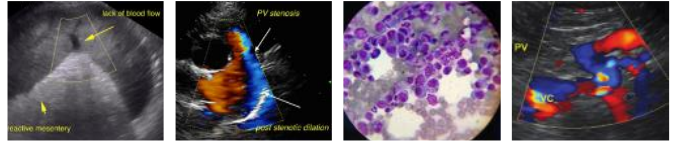
Dr. Sepulveda

## INVOICE

20428

## DATE

1/6/23



**PATIENT**

Blue Aymar- Smith

**SPECIES**

Feline

**BREED**

Himalayan/Persian Mix

**SEX**

Neutered Male

**AGE**

12 Years

**WEIGHT**

9.2 Pounds

**INTERPRETED BY**

Eric Lindquist, DMV  
DABVP, Cert. IVUSS

**IMAGING PERFORMED BY**

Kelly Vazquez

**HOSPITAL NAME**

Veterinary Wellness,  
Glen Rock

**REFERRING VET**

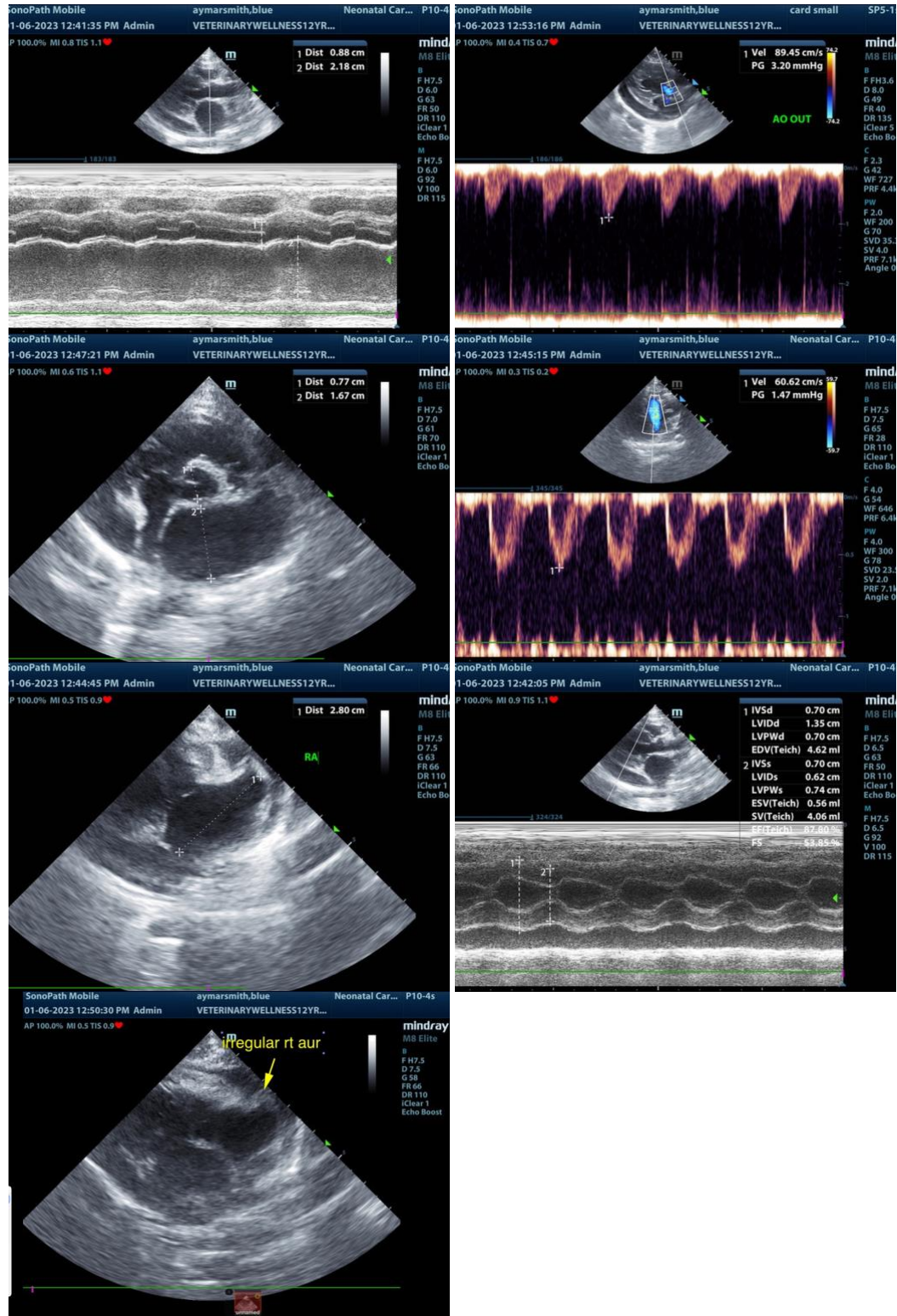
Dr. Sepulveda

**INVOICE**

20428

**DATE**

1/6/23



The information and recommendations provided are based on the images presented by the referring veterinarian. No evaluation can be communicated regarding pathology that was not visible in the image/video clips provided.



**PATIENT**

Blue Aymar- Smith

Thank you for this referral. If the clinical or image interpretation does not parallel your findings or if I can be of any further assistance please contact me.

**SPECIES**

Feline

**Eric Lindquist**, DMV, DABVP, Cert. IVUSS, CEO of SonoPath.com  
info@SonoPath.com

**BREED**

Himalayan/Persian Mix

**SEX**

Neutered Male

**AGE**

12 Years

**WEIGHT**

9.2 Pounds

**INTERPRETED BY**

Eric Lindquist, DMV  
DABVP, Cert. IVUSS

**IMAGING  
PERFORMED BY**

Kelly Vazquez

**HOSPITAL NAME**

Veterinary Wellness,  
Glen Rock

**REFERRING VET**

Dr. Sepulveda

**INVOICE**

20428

**DATE**

1/6/23