



PATIENT PRESENTING CLINICAL SIGNS

Skippy McNally Lost 5 lb.

SPECIES ULTRASONOGRAPHIC EXAMINATION OF THE ABDOMEN

Feline Urinary System

The **urinary bladder**, trigone, and pelvic urethra presented normal thicknesses and normal tone. The ureters were not visible which is normal. No uroliths or sediment were visualized and anechoic urine was present. No evidence of inflammatory or neoplastic changes were noted. Ureteral papillae were normal.

BREED

DSH

SEX

Spayed Female

The **kidneys** revealed largely normal size and structure, corticomedullary definition and ratio (cortex 1/3 of medulla) were essentially maintained with some age-related loss of curvilinear patterns regarding the capsule and C/M junction. The cortices presented largely uniform texture with some increased echogenicity expected for his age patient. Medullary structure differed distinctly from that of the cortex and no evidence of pelvic dilation was present. The left kidney measured 3.74 cm. The right kidney measured 3.4 cm.

AGE

10 Years

Adrenal Glands

The **adrenal glands** were uniform, yet bilaterally swollen and hypoechoic. This is most consistent with stress-induced hyperplasia. The adrenal glands measured 0.6 cm in width each.

INTERPRETED BY

Eric Lindquist, DMV
DABVP, Cert. IVUSS

Spleen

The **spleen** presented a smooth homogeneous parenchyma hyperechoic to liver and renal cortical parenchyma. The capsule was smooth without noticeable expansion or deviation from within the spleen or adjacent pathology. The splenic vasculature demonstrated normal volume without signs of congestion or thrombosis. No sonographic evidence of acute or chronic inflammatory, neoplastic, or infarctual changes were noted.

IMAGING PERFORMED BY

Eric Lindquist, DMV
DABVP, Cert. IVUSS

Liver

The **liver** images submitted revealed subjectively normal liver size, contour, and structure. Parenchymal echogenicity was naturally coarse and hypoechoic to the spleen. Vascular and biliary tracts were of normal volume with no evidence of congestion. The gallbladder presented acceptably thin walls with primarily anechoic content. The cystic and common bile ducts were normal. No pathological hepatic lymphadenopathy was evident. No overt structural evidence of inflammatory, infiltrative or regenerative pathology was evident.

HOSPITAL NAME

Franklin Lakes AH

REFERRING VET

Dr. Stoltz

Gastrointestinal

Examination of the **gastrointestinal tract** revealed a stomach and intestine free of stasis, of normal wall thickness, acceptable curvilinear mural detail, and peristaltic activity. Small and large intestine demonstrated normal luminal chyme and stool consistency respectively. No obstructive or overt infiltrative disease was noted. No associated abnormal lymphatic activity was noted.

INVOICE

34025

Pancreas

DATE

1/6/22

The base and limbs of the **pancreas** were observed to be largely isoechoic to surrounding omental fat. Some parenchymal remodeling, however, with mild deviation from curvilinear normalcy was observed. Pancreatic duct and capsular irregularities were present consistent with age related changes. If pain upon imaging (+ Murphy sign) was present or if the patient is focally painful in subxyphoid palpation then low-grade smoldering chronic pancreatitis should be suspected.



PATIENT ULTRASONOGRAPHIC FINDINGS

Skippy McNally • Unremarkable geriatric abdomen

INTERPRETATION OF THE FINDINGS & FURTHER RECOMMENDATIONS

SPECIES No evidence of pathology. CBC path review +/- bone marrow aspirates recommended. Full CNS exam and chest rads warranted.

Feline

BREED

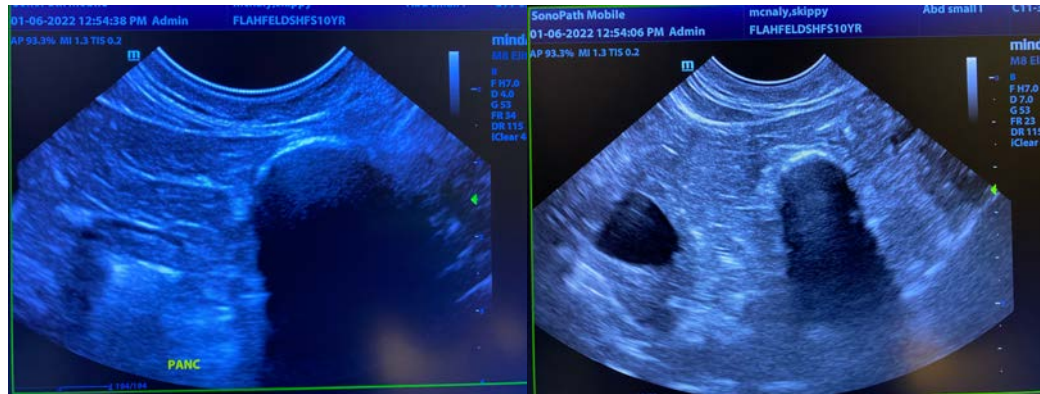
DSH

SEX

Spayed Female

AGE

10 Years

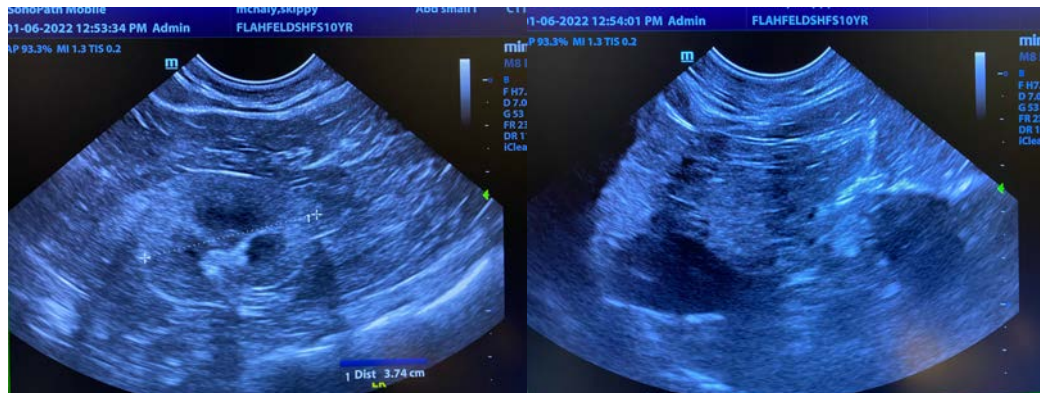


INTERPRETED BY

Eric Lindquist, DMV
DABVP, Cert. IVUS

IMAGING PERFORMED BY

Eric Lindquist, DMV
DABVP, Cert. IVUS



HOSPITAL NAME

Franklin Lakes AH

REFERRING VET

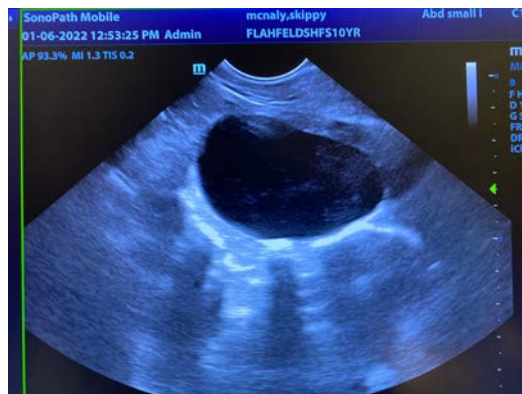Dr. Stoltz

INVOICE

34025

DATE

1/6/22





PATIENT

Skippy McNally

The information and recommendations provided are based on the images presented by the referring veterinarian. No evaluation can be communicated regarding pathology that was not visible in the image/video clips provided.

SPECIES

Feline

Thank you for this referral. If the clinical or image interpretation does not parallel your findings or if I can be of any further assistance please contact me.

BREED

DSH

Eric Lindquist, DMV, DABVP, Cert. IVUSS, CEO of SonoPath.com
Info@SonoPath.com

SEX

Spayed Female

AGE

10 Years

INTERPRETED BY

Eric Lindquist, DMV
DABVP, Cert. IVUSS

**IMAGING
PERFORMED BY**

Eric Lindquist, DMV
DABVP, Cert. IVUSS

HOSPITAL NAME

Franklin Lakes AH

REFERRING VET

Dr. Stoltz

INVOICE

34025

DATE

1/6/22