



**PATIENT**

Kurumi Pearce

**PRESENTING CLINICAL SIGNS**

Follow up ultrasound images in region of right adrenal gland. P previously noted to have right adrenal gland mass but right adrenal gland not visualized on last ultrasound ~1 month ago.

**SPECIES**

Canine

**ULTRASONOGRAPHIC EXAMINATION OF THE ABDOMEN**

The kidneys presented persistent polycystic changes with calculi. The right kidney measured 3.74 cm.

**BREED**

Shih Tzu

A nodular change was noted associated with the caudal aspect of the right liver and right adrenal gland. This was not evident in the prior sonogram. The entire structure measured 2.5 x 2.25 cm and is presumed to be right adrenal gland. The vena cava appeared impinged upon, but not invaded. The adrenal was heterogenous and irregular, yet largely isoechoic to the surrounding tissue.

**SEX**

Spayed Female

**AGE**

16 years

**ULTRASONOGRAPHIC FINDINGS**

Irregular right adrenal with mass effects. Possible contiguous spread to the caudal right liver.

Polycystic right kidney.

**WEIGHT**

12.6 lbs

**INTERPRETATION OF THE FINDINGS & FURTHER RECOMMENDATIONS**

CT evaluation of the region is warranted as well as assessment for any hypertension related to the right adrenal gland. Differentials include carcinoma, adenoma, pheochromocytoma. CT for surgical planning would be ideal.

**INTERPRETED BY**

Eric Lindquist, DMV  
DABVP, Cert. IVUSS

**IMAGING PERFORMED BY**

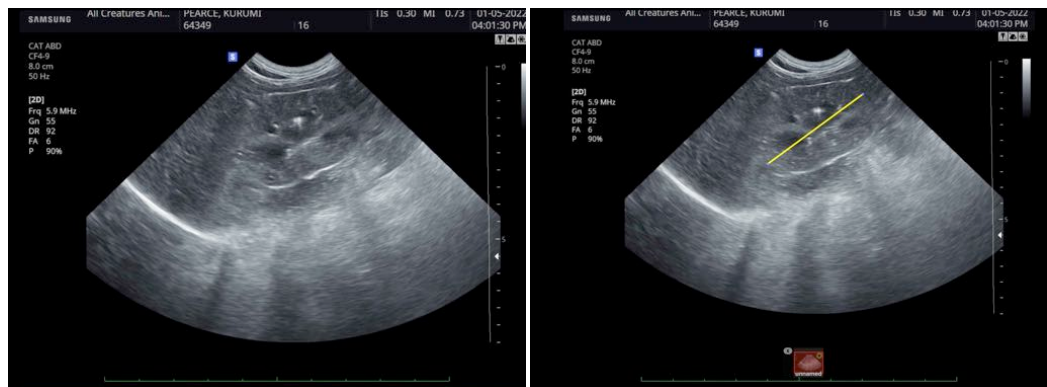
Dr. Preston

**HOSPITAL NAME**

All Creatures AH of  
South Hill

**REFERRING VET**

Dr. Preston

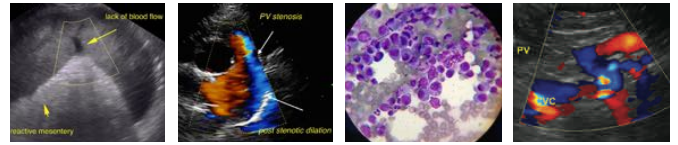


**INVOICE**

95056

**DATE**

1/5/22



**PATIENT**

Kurumi Pearce

**SPECIES**

Canine

**BREED**

Shih Tzu

**SEX**

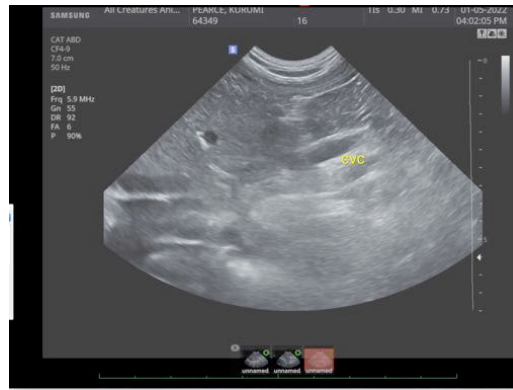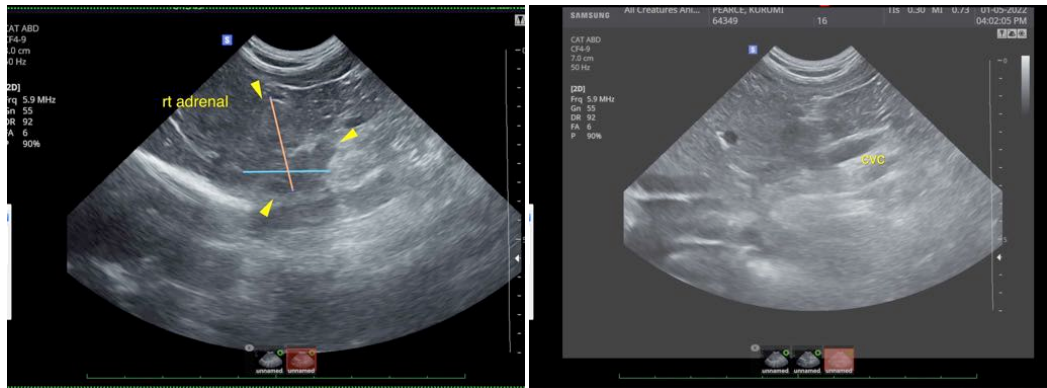
Spayed Female

**AGE**

16 years

**WEIGHT**

12.6 lbs



**INTERPRETED BY**

Eric Lindquist, DMV  
DABVP, Cert. IVUSS

**IMAGING PERFORMED BY**

Dr. Preston

**HOSPITAL NAME**

All Creatures AH of  
South Hill

**REFERRING VET**

Dr. Preston

**INVOICE**

95056

**DATE**

1/5/22

The information and recommendations provided are based on the images presented by the referring veterinarian. No evaluation can be communicated regarding pathology that was not visible in the image/video clips provided.

Thank you for this referral. If the clinical or image interpretation does not parallel your findings or if I can be of any further assistance please contact me.

**Eric Lindquist, DMV, DABVP, Cert. IVUSS, CEO of SonoPath.com**  
info@SonoPath.com