



| | |
|---|--|
| PATIENT | PRESENTING CLINICAL SIGNS |
| Harlan Sherr | Straining to defecate. |
| SPECIES | ULTRASONOGRAPHIC EXAMINATION OF THE ABDOMEN |
| Canine | Urinary System |
| BREED | The urinary bladder , trigone, and pelvic urethra presented normal thicknesses and normal tone. The ureters were not visible which is normal. Small bladder calculi were noted and non-obstructive measuring up to 0.5 cm. No evidence of inflammatory or neoplastic changes was noted. Ureteral papillae were normal. |
| Hound Mix | |
| SEX | The prostate was enlarged, irregular and mineralized measuring 3.74 cm. Regional inflammation was noted around the prostate. Pre-prostatic urethral dilation was noted owing to obstructive pattern by the prostatic pathology. |
| Neutered male | |
| AGE | The kidneys revealed normal size and structure, corticomedullary definition and ratio for this age. The cortices presented largely uniform texture with normal echogenic relationship to liver and spleen. Medullary structure differed distinctly from the cortex and no evidence of pelvic dilation was present. The capsules were acceptably uniform without significant irregularities. The left kidney measured 6.44 cm. |
| 10 years | |
| WEIGHT | Adrenal Glands |
| 81.5 lbs | Both adrenal glands were visualized and recognized as having normal shape, size, position and echogenicity for this breed. The phrenic vasculature, glandular echogenicity and detail were unremarkable. Capsule, cortex, and medullary definition were normal for this age patient. The right adrenal gland measured 2.57 x 0.58 cm at the cranial pole and 0.52 cm at the caudal pole. The left adrenal gland measured 1.91 x 0.49 cm at the cranial pole and 0.6 cm at the caudal pole. |
| INTERPRETED BY | |
| Eric Lindquist, DMV DABVP, Cert. IVUSS | |
| IMAGING PERFORMED BY | Spleen |
| Shari Reffi, CVT | The spleen presented a smooth homogeneous parenchyma hyperechoic to liver and renal cortical parenchyma. The capsule was smooth without noticeable expansion or deviation from within the spleen or adjacent pathology. The splenic vasculature demonstrated normal volume without signs of congestion or thrombosis. No sonographic evidence of acute or chronic inflammatory, neoplastic, or infarctual changes was noted. |
| HOSPITAL NAME | |
| Rockaway AH | |
| REFERRING VET | Liver |
| Dr. Maniar | The liver images submitted revealed subjectively normal liver size, contour, and structure. Parenchymal echogenicity was naturally coarse and hypoechoic to the spleen. Vascular and biliary tracts were of normal volume with no evidence of congestion. The gallbladder presented acceptably thin walls with primarily anechoic content. The cystic and common bile ducts were normal. No pathological hepatic lymphadenopathy was evident. No overt structural evidence of inflammatory, infiltrative or regenerative pathology was evident. |
| INVOICE | |
| 95046 | |
| DATE | |
| 1/6/22 | |



PATIENT

Harlan Sherr

Gastrointestinal

SPECIES

Canine

Examination of the **gastrointestinal tract** revealed a stomach and intestine free of stasis, of normal wall thickness, acceptable curvilinear mural detail, and peristaltic activity. Small and large intestine demonstrated normal luminal chyme and stool consistency respectively. No obstructive or overt infiltrative disease was noted. No associated abnormal lymphatic activity was noted.

BREED

Hound Mix

Pancreas

SEX

Neutered male

The base and limbs of the **pancreas** were observed to be largely isoechoic to surrounding omental fat. Pancreatic duct and capsular contour were acceptably normal and parenchyma respected normal curvilinear patterns. No overt evidence of active inflammatory or neoplastic disease was noted.

AGE

10 years

ULTRASONOGRAPHIC FINDINGS

Mineralized prostatic mass, concurrent bladder calculi. Strongly suggestive for prostatic carcinoma.

WEIGHT

81.5 lbs

INTERPRETATION OF THE FINDINGS & FURTHER RECOMMENDATIONS

Ultrasound-guided FNA or traumatic catheterization is indicated.

INTERPRETED BY

Eric Lindquist, DMV
DABVP, Cert. IVUSS

USG FNA of the prostate could be performed with minor risk of tumor trailing. USG traumatic catheterization is also an option but may be false negative if there is not prominent prostatic urethral involvement. BRAF can be utilized as additional confirmation of suspected carcinoma.

IMAGING PERFORMED BY

Shari Reffi, CVT

HOSPITAL NAME

Rockaway AH

REFERRING VET

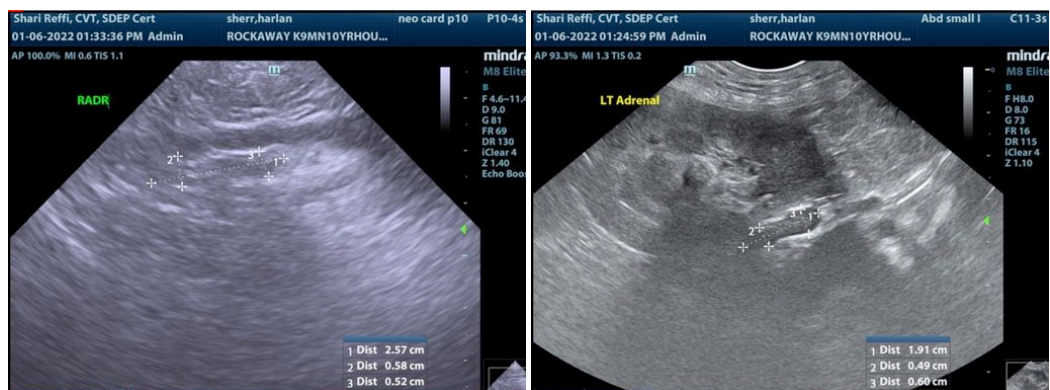
Dr. Maniar

INVOICE

95046

DATE

1/6/22





PATIENT

Harlan Sherr

SPECIES

Canine

BREED

Hound Mix

SEX

Neutered male

AGE

10 years

WEIGHT

81.5 lbs

INTERPRETED BY

Eric Lindquist, DMV
DABVP, Cert. IVUSS

IMAGING PERFORMED BY

Shari Reffi, CVT

HOSPITAL NAME

Rockaway AH

REFERRING VET

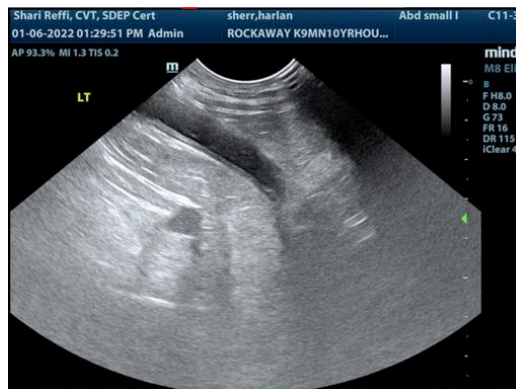
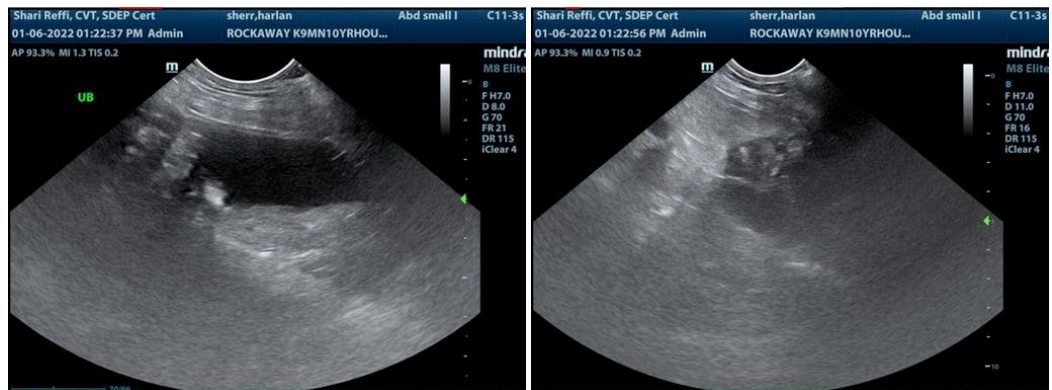
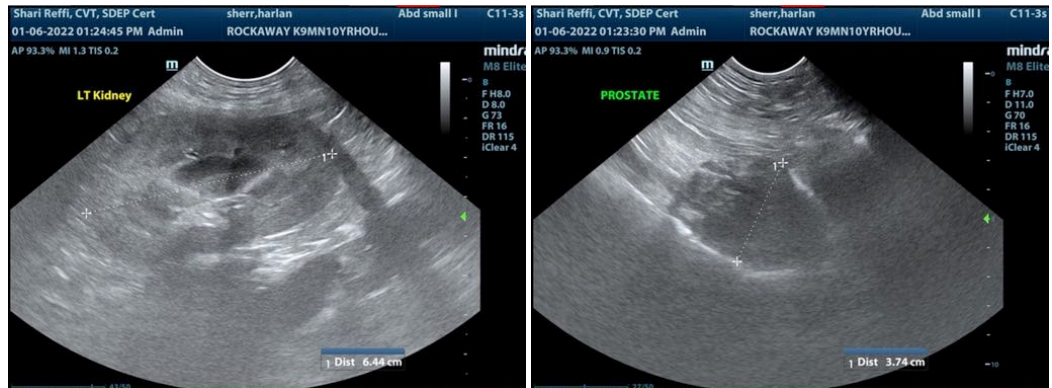
Dr. Maniar

INVOICE

95046

DATE

1/6/22



The information and recommendations provided are based on the images presented by the referring veterinarian. No evaluation can be communicated regarding pathology that was not visible in the image/video clips provided.

Thank you for this referral. If the clinical or image interpretation does not parallel your findings or if I can be of any further assistance please contact me.

Eric Lindquist, DMV, DABVP, Cert. IVUSS, CEO of SonoPath.com
Info@SonoPath.com



PATIENT

Harlan Sherr

SPECIES

Canine

BREED

Hound Mix

SEX

Neutered male

AGE

10 years

WEIGHT

81.5 lbs

INTERPRETED BY

Eric Lindquist, DMV
DABVP, Cert. IVUSS

IMAGING PERFORMED BY

Shari Reffi, CVT

HOSPITAL NAME

Rockaway AH

REFERRING VET


Dr. Maniar

INVOICE

95046

DATE

1/6/22




The following is an applicable excerpt from the *Curbside Guide to Diagnosis & Treatment of Sonographic Disease* offered by [SonoPath.com](http://sonopath.com) Lindquist, Frank, Lobetti, and Modler.

An essential quick guide for every general practitioner and sonographer.

<https://sonopath.com/products/curbside-guide-editing-due-release-12012015>

Canine Prostatic Neoplasia

<http://www.sonopath.com/ProstaticCarcinoma>

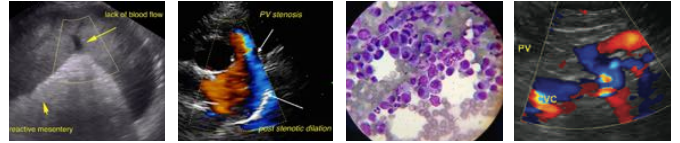


Long axis of the prostate in a neutered male dog with prostatic carcinoma. The prostatic gland (between calipers) is significantly enlarged. Multiple hyperechoic foci consistent with mineralization are seen. Note the low echogenicity of the prostatic parenchyma rendering the urethral pathway relatively hyperechoic. Also note the presence of power Doppler signal in the organ periphery which is not seen in normal prostatic glands and benign prostatic hyperplasia.

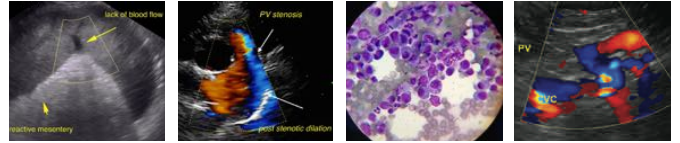
Description: Prostatic neoplasia is frequently seen in dogs and can be diagnosed via ultrasonographic examination. The most commonly diagnosed prostatic neoplasms are adenocarcinoma and undifferentiated carcinoma. Transitional cell carcinoma (TCC) frequently spreads from the urinary bladder and urethra to the prostatic tissue (see the “Transitional Cell Carcinoma” chapter for more details). Metastatic squamous cell carcinoma, lymphoma, hemangiosarcoma, and leiomyosarcoma have been reported, but are less prevalent. Prostatic neoplasia has been documented in cats, but is quite rare.

Clinical Signs: Prostatic neoplasia presents in both neutered and intact males; however, a 2002 study suggested that neutered males were at greater risk for developing prostatic neoplasia than intact males. Typically, prostatic neoplasia is seen in older dogs (mean age of 10 years). Breed predilection includes mixed breed dogs, Shetland Sheepdogs, Dobermans, Scottish Terriers, and Airedale Terriers. Clinical signs and commonly reported signs from owners typically include: stranguria, frequent urinations, hematuria, dyschezia, weight loss, and decreased appetite. Other findings upon physical examination include fever, ataxia, pain upon rectal examination, and pain upon spinal palpation.

Diagnostics: Ultrasonographic examination should be performed if prostatic neoplasia is suspected. Common ultrasonographic findings include an enlarged, irregular prostate that typically has a hypoechoic appearance. Multifocal, poorly coalescing hyperechoic foci are also seen in prostatic malignancies. Hyperechoic foci are due to mineralization of the prostate; they cause far field shadowing. Cystic components can also be observed and are thought to indicate abscessation and/or necrosis. It



| | |
|---|--|
| PATIENT | can be difficult to differentiate chronic bacterial prostatitis from a prostatic neoplasia; however, regional lymphadenopathy is much more common with prostatic neoplasia than it is with chronic bacterial prostatitis. Malignancies of the prostate have often metastasized by the time of diagnosis. Frequent sites of metastases include the sublumbar lymph nodes, the pelvis, lumbar vertebrae, and the lungs. If metastases to the pelvis or lumbar vertebrae have occurred, bony lysis will often be noted radiographically. Metastasis to the liver, brain, kidney and spleen may occur. A definitive diagnosis of a prostatic neoplasm can be achieved through biopsy as well as fine needle aspiration (FNA) or through ultrasound-guided traumatic catheterization. |
| Harlan Sherr | |
| SPECIES | |
| Canine | |
| BREED | |
| Hound Mix | A complete and thorough workup includes a CBC, biochemical profile, urinalysis, as well as three radiographic views of the thorax, an abdominal ultrasound, and an ultrasound-guided prostatic biopsy or FNA, if indicated. Urinalysis may reveal hematuria and pyuria. Prostatic fluid analysis can also be helpful in identifying neoplastic cells. |
| SEX | |
| Neutered male | |
| AGE | Treatment: Unfortunately, once diagnosed, prostatic carcinoma offers a poor prognosis; prostatectomy, chemotherapy, and radiation therapy have proven unsuccessful in improving quality or length of life. Nonsteroidal anti-inflammatory drugs (NSAIDs), such as deracoxib, meloxicam, and piroxicam, have been used for their palliative, anti-neoplastic properties with prostatic carcinomas. Certain tumors, including various carcinomas (e.g. TCC, prostatic carcinoma, mammary carcinoma, squamous cell carcinoma) overexpress COX-2, which converts arachidonic acid to prostaglandin G ₂ (PGG ₂)/prostaglandin H ₂ (PGH ₂), and ultimately to prostaglandin E ₂ (PGE ₂). The metabolite, PGE ₂ , is associated with increased inflammation, tumor invasiveness, angiogenesis, and reduced apoptosis. In vivo and in vitro, NSAIDs inhibit COX-2, resulting in the suppression of PGE ₂ , and thereby inhibiting tumor growth and metastasis. This effect has been achieved with both non-selective COX inhibitors as well as COX-2 inhibitors (the latter will suppress COX-1 at increased doses). |
| 10 years | |
| WEIGHT | |
| 81.5 lbs | |
| INTERPRETED BY | Some cases of prostatic carcinoma are managed palliatively with cyst/abscess ultrasound-guided drainage, antibiotic infusion, systemic antibiotics, and NSAID treatment and/or chemotherapy. Anecdotally, it has been observed that patients that often present clinical signs of hematuria or dysuria owing to cyst or abscess formation may be treated with repeat ultrasound-guided drainage. This appears to work especially well if there is a considerable cystic component to the prostatic tumor. The key is to image the prostate adequately, drain any cysts that are present, sample the abnormal parenchyma (FNA or biopsy), and potentially infuse antibiotics directly into the cystic cavities if a suppurative fluid is retrieved. The patient should be monitored clinically over time and reevaluated to see if cysts recur. Every case responds differently to treatment, and the behavior of parenchymal and cystic growth will vary. |
| Eric Lindquist, DMV DABVP, Cert. IVUSS | |
| IMAGING PERFORMED BY | |
| Shari Reffi, CVT | |
| HOSPITAL NAME | |
| Rockaway AH | |
| REFERRING VET | Currently, investigational studies involving fluoroscopic-guided direct chemotherapeutic embolization through the iliac arteries as well as urethral stent placement are offered by select tertiary veterinary facilities that have an interventional radiology department. Ultrasound-guided endoscopic diode laser ablation through a perineal urethrostomy is also being attempted as a salvage and palliative procedure. |
| Dr. Maniar | |
| INVOICE | |
| 95046 | |
| DATE | Conclusion: Prostatic neoplasia is more commonly detected in neutered male dogs than intact males. Diagnosis is typically obtained using ultrasound, cytology, and histopathology. Unfortunately, traditional therapy typically yields a guarded to poor long-term prognosis, but palliation with NSAIDs |
| 1/6/22 | |



PATIENT

and/or chemotherapy can temporarily improve clinical signs. Investigational techniques may provide additional therapeutic options but are currently experimental.

Harlan Sherr

SPECIES

Canine

BREED

Hound Mix

SEX

Neutered male

AGE

10 years

WEIGHT

81.5 lbs

INTERPRETED BY

Eric Lindquist, DMV
DABVP, Cert. IVUSS

IMAGING PERFORMED BY

Shari Reffi, CVT

HOSPITAL NAME

Rockaway AH

REFERRING VET


Dr. Maniar

INVOICE


95046

DATE

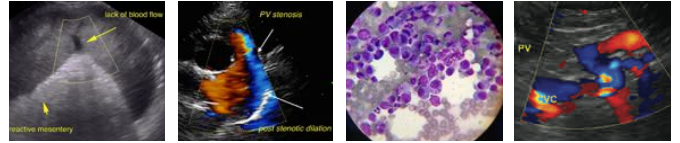
1/6/22



Long axis of the prostate in a dog with prostatic carcinoma with cystourethral junction to the left. Note the typical “starry sky” pattern of prostatic carcinoma with multiple echogenic foci representing mineralizations (arrow) on a relatively hypoechoic background created by the neoplastic infiltrate. Considerable vascularity is present throughout the parenchyma noted on power Doppler.



Long axis of the prostate in a dog with prostatic carcinoma during ultrasound guided sampling. The prostatic mass is largely isoechoic to surrounding fat in this particular example and can easily be missed without correct gain and focal point adjustments. The needle trajectory is seen as a weakly echogenic interface (arrowheads). Note the echo yield is limited technically by the steep insonation angle here. Note the sharp deviation of the descending colon owing to the prostatic mass effect upon it (arrow). This colonic deviation was a key point toward identifying this isoechoic prostatic mass in this case.



PATIENT

Harlan Sherr

SPECIES

Canine

BREED

Hound Mix

SEX

Neutered male

AGE

10 years

WEIGHT

81.5 lbs

INTERPRETED BY

Eric Lindquist, DMV
DABVP, Cert. IVUSS

**IMAGING
PERFORMED BY**

Shari Reffi, CVT

HOSPITAL NAME

Rockaway AH

REFERRING VET


Dr. Maniar

INVOICE


95046

DATE

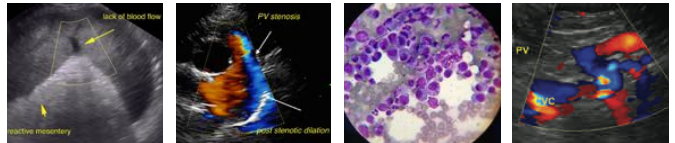
1/6/22



Long axis of the prostate in a dog with prostatic carcinoma during ultrasound guided sampling. The prostatic mass is largely isoechoic to surrounding fat in this particular example and can easily be missed without correct gain and focal point adjustments. The needle trajectory is seen as a weakly echogenic interface (arrowheads). Note the echo yield is limited technically by the steep insonation angle here. Note the sharp deviation of the descending colon owing to the prostatic mass effect upon it (arrow). This colonic deviation was a key point toward identifying this isoechoic prostatic mass in this case.



Long axis of the prostate in a neutered male dog with prostatic carcinoma. Note that prostatic carcinomas are not necessarily large and commonly similar in echogenicity and echotexture as compared to the surrounding peritoneal fat. Proper scanning technique tracing the bladder neck and urethra is essential not to miss the lesion.



PATIENT


Harlan Sherr

SPECIES

Canine

BREED

Hound Mix



Short axis of the prostate in a dog with cystic prostatic carcinoma. Multifocal intraparenchymal cyst-like lesions with anechoic to hypoechoic content are seen. Asymmetric enlargement is noted. The regular bilobed shape and typical dorsal notch are lost. The echotexture in this particular prostatic mass is reminiscent of the occasional prostatic lymphoma that can occur as exemplified in the next image.

SEX

Neutered male

AGE

10 years

WEIGHT

81.5 lbs

INTERPRETED BY

Eric Lindquist, DMV
DABVP, Cert. IVUSS

IMAGING PERFORMED BY

Shari Reffi, CVT

HOSPITAL NAME

Rockaway AH

REFERRING VET


Dr. Maniar

INVOICE

95046

DATE

1/6/22



Cross section of the prostate in a dog with enlarged irregular prostate. The regular parenchymal echoarchitecture is displaced by two well delineated hypoechoic nodules (arrows). Note the generalized swelling of the gland. The sonographic appearance resembles prostatitis and abscessation, yet the diagnosis was significantly different on USG FNA (prostatic lymphoma). Note: abscessation can be differentiated from proliferative nodules with power Doppler as signals are negative with abscessation or necrosis and typically positive with tissue proliferation.

References:

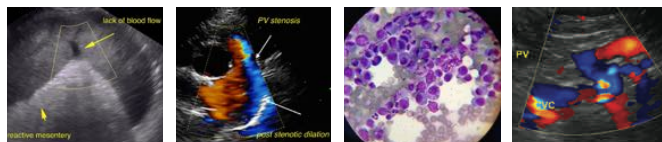
Cerf DJ, Lindquist EC. Palliative ultrasound-guided endoscopic laser ablation of transitional cell carcinomas of the lower urinary tract in dogs. *J Am Vet Med Assoc* 2012;240(1):51-60.

Culp, WTN. Interventional oncology and the management of urinary tract cancer. Proceedings from the American College of Veterinary Internal Medicine, New Orleans, LA, May 30-June 2, 2012.

Francey T. Prostatic Diseases. In: Ettinger SJ, Feldman EC, eds. *Textbook of Veterinary Internal Medicine 7th ed.* Philadelphia, PA: WB Saunders; 2010:2047-58.

Hecht S. Male Reproductive Tract. In: Pennick D, D'Anjou MA, eds. *Atlas of Small Animal Ultrasonography.* Ames, IA: Blackwell Publishing; 2008:417-43.

Milner RJ. Do NSAIDs make a difference in cancer. Proceedings from the American College of Veterinary Internal Medicine, Denver, CO, June 15-18, 2011.



PATIENT

Mohammed SI, Khan KN, Sellers RS, et al. Expression of cyclooxygenase-1 and 2 in naturally-occurring canine cancer. *Prostag Leukotr Ess* 2004;70(5):479-83.

Harlan Sherr

Nyland, TG, Mattoon JS. *Small Animal Diagnostic Ultrasound 2nd ed.* Philadelphia, PA: WB Saunders; 2002:250-66.

SPECIES

Canine

Sorenmo KU, Goldschmidt MH, Shofer FS, et al. Evaluation of cyclooxygenase-1 and cyclooxygenase-2 expression and the effect of cyclooxygenase inhibitors in canine prostatic carcinoma. *Vet Comp Oncol* 2004;2(1):13-23.

BREED

Hound Mix

SEX

Neutered male

AGE

10 years

WEIGHT

81.5 lbs

INTERPRETED BY

Eric Lindquist, DMV
DABVP, Cert. IVUSS

**IMAGING
PERFORMED BY**

Shari Reffi, CVT

HOSPITAL NAME

Rockaway AH

REFERRING VET

Dr. Maniar

INVOICE

95046

DATE

1/6/22