



## PATIENT

Jayden Bancalari

## SPECIES

Feline

## BREED

Sphynx

## SEX

Neutered Male

## AGE

18 Years

## WEIGHT

102.2 Pounds

## INTERPRETED BY

Eric Lindquist, DMV,  
DABVP (Canine &  
Feline), Cert. IVUSS

## IMAGING PERFORMED BY

Dr. Jeremiah Gabriel

## HOSPITAL NAME

Central Jersey AH

## REFERRING VET

Dr. Jeremiah Gabriel

## INVOICE

35256

## DATE

1/5/26

## PRESENTING CLINICAL SIGNS

History: Urinating outside litter box acting different eating and drinking well no c/d/v/s history of CHF taking Vetmedin, lasix and enalapril owner is concerned since last radiology showed enlarged liver

## ULTRASONOGRAPHIC EXAMINATION OF THE ABDOMEN

### *Urinary System*

The **urinary bladder**, trigone, and pelvic urethra presented normal thicknesses and normal tone. The ureters were not visible which is normal. No uroliths or sediment were visualized and anechoic urine was present. No evidence of inflammatory or neoplastic changes were noted. Ureteral papillae were normal.

The **kidneys** revealed largely normal size and structure, corticomedullary definition and ratio (cortex 1/3 of medulla) were essentially maintained with some moderate age-related loss of curvilinear patterns regarding the capsule and C/M junction. The cortices presented largely uniform texture with some increased echogenicity expected for this age patient. Medullary structure differed distinctly from that of the cortex and no evidence of pelvic dilation was present. The kidneys measured 4.0 cm each.

### *Adrenal Glands*

The regions of the **adrenal glands** revealed no evident pathology.

### *Spleen*

The **spleen** revealed irregular contour, measuring up to 1.0 cm, and hypoechoic granular appearance.

### *Liver*

The **liver** was severely enlarged, hypoechoic, and irregular. Multifocal hyper- and hypoechoic isoechoic nodular changes were noted throughout the liver. The gallbladder and common bile duct were unremarkable.

### *Gastrointestinal*

The **stomach** itself was unremarkable. Variable intestinal thickening was noted. The colon was unremarkable.

### *Pancreas*

The **pancreas** was hypoechoic and irregular with undulating contour, obscured by the enhanced mesentery.

### *Free Abdomen*

A moderate amount of **free fluid** was noted in the abdomen. Enhanced mesentery was noted throughout the mid abdomen. Pleural effusion and ascites were noted.

## ULTRASONOGRAPHIC FINDINGS

- Lymphomatosis/mastocytosis type presentation
- Irregular splenic contour with hypoechoic granular appearance
- Nodular hepatic changes
- Variable intestinal thickening



## PATIENT

Jayden Bancalari

- Hypoechoic irregular pancreas
- Secondary ascites and pleural effusion are likely owing to lymphatic obstruction
- Age-related renal changes

## SPECIES

Feline

## INTERPRETATION OF THE FINDINGS & FURTHER RECOMMENDATIONS

Coagulation panel and 25-gauge FNA of the spleen and liver is indicated.

## BREED

Sphynx

## SEX

Neutered Male

## AGE

18 Years

## WEIGHT

102.2 Pounds

## INTERPRETED BY

Eric Lindquist, DMV,  
DABVP (Canine & Feline), Cert. IVUSS

## IMAGING PERFORMED BY

Dr. Jeremiah Gabriel

## HOSPITAL NAME

Central Jersey AH

## REFERRING VET

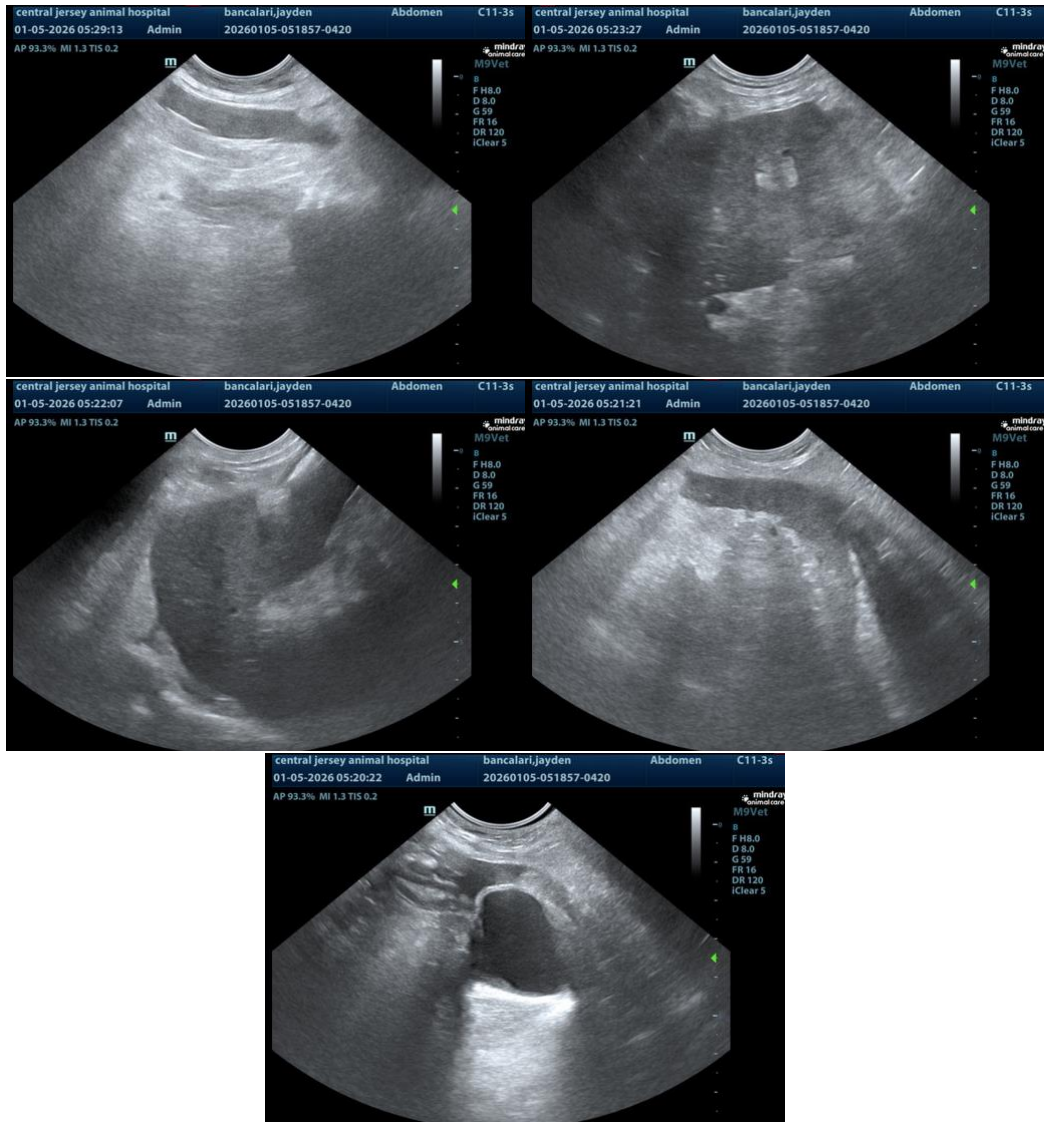
Dr. Jeremiah Gabriel

## INVOICE

35256

## DATE

1/5/26



The information and recommendations provided are based on the images presented by the referring veterinarian/sonographer. No evaluation can be communicated regarding pathology that was not visible in the image/video clips provided.

Thank you for this referral. If the clinical or image interpretation does not parallel your findings or if I can be of any further assistance please contact me.



## PATIENT

Jayden Bancalari

Eric Lindquist, DMV, DABVP(CFM), Cert. IVUSS,  
CEO, Owner, Founder -- SonoPath.com

[info@SonoPath.com](mailto:info@SonoPath.com)

## SPECIES

Feline

## BREED

Sphynx

## SEX

Neutered Male

## AGE

18 Years

## WEIGHT

102.2 Pounds

## INTERPRETED BY

Eric Lindquist, DMV,  
DABVP (Canine &  
Feline), Cert. IVUSS

## IMAGING PERFORMED BY

Dr. Jeremiah Gabriel

## HOSPITAL NAME

Central Jersey AH

## REFERRING VET

Dr. Jeremiah Gabriel

## INVOICE

35256

## DATE

1/5/26