



## PATIENT

Benny Riccio

## SPECIES

Canine

## BREED

Golden Retriever

## SEX

Neutered male

## AGE

8 years

## WEIGHT

100.8 lbs

## INTERPRETED BY

Eric Lindquist, DMV  
DABVP, Cert. IVUSS

## IMAGING PERFORMED BY

Elaina Petrone

## HOSPITAL NAME

Long Branch AH

## REFERRING VET

Dr. Petrone

## INVOICE

69783

## DATE

1/5/26

## PRESENTING CLINICAL SIGNS

History: 8 yo MN Golden with an approximate 7 day history of decreased appetite, weight loss (5-7 pounds since September), occasional diarrhea, and nausea. PU/PD-mild to moderate. CBC/chem/accuplex/fecal/T4-NSF, missing urine sample. Resting cortisol pending. PE overall unremarkable. History of reactive cutaneous histiocytosis.

## ULTRASONOGRAPHIC EXAMINATION OF THE ABDOMEN

### Urinary System

The **urinary bladder**, trigone, and pelvic urethra presented normal thicknesses and normal tone. The pelvic urethra was imaged 3.0 cm beyond the cystourethral junction and appeared normal. The ureters were not visible which is normal. No uroliths or sediment were visualized and anechoic urine was present. No evidence of inflammatory or neoplastic changes was noted. Ureteral papillae were normal.

The **kidneys** revealed normal size and structure, corticomedullary definition and ratio for this age. The cortices presented largely uniform texture with normal echogenic relationship to liver and spleen. Medullary structure differed distinctly from the cortex and no evidence of pelvic dilation was present. The capsules were acceptably uniform without significant irregularities. The right kidney measured 7.66 cm. The left kidney measured 7.6 cm.

### Adrenal Glands

Both **adrenal glands** were visualized and recognized as having normal shape, size, position and echogenicity for this breed. The phrenic vasculature, glandular echogenicity and detail were unremarkable. Capsule, cortex, and medullary definition were normal for this age patient. The left adrenal gland measured 0.5 cm. The right adrenal gland measured 0.78 cm at the cranial pole and 0.5 cm at the caudal pole.

### Spleen

The **spleen** presented a smooth homogeneous parenchyma hyperechoic to liver and renal cortical parenchyma. The capsule was smooth without noticeable expansion or deviation from within the spleen or adjacent pathology. The splenic vasculature demonstrated normal volume without signs of congestion or thrombosis. No sonographic evidence of acute or chronic inflammatory, neoplastic, or infarctual changes was noted.

### Liver

The **liver** images submitted revealed subjectively normal liver size, contour, and structure. Parenchymal echogenicity was naturally coarse and hypoechoic to the spleen. Vascular and biliary tracts were of normal volume with no evidence of congestion. The gallbladder presented acceptably thin walls with primarily anechoic content. The cystic and common bile ducts were normal. No pathological hepatic



## PATIENT

Benny Riccio

lymphadenopathy was evident. No overt structural evidence of inflammatory, infiltrative or regenerative pathology was evident.

## SPECIES

Canine

### *Gastrointestinal*

## BREED

Golden Retriever

The **gastrointestinal** presentation revealed mild uniform prominence of the gastric mucosa as well as areas of "ropey" small intestinal wall with slight disruption of the normal 1:3 muscularis/mucosal ratio. The intestinal submucosa was slightly irregular, thickened and hyperechoic suggestive of low grade, chronic disease. No concerning lymphadenopathy was visible. No evidence of obstruction was present. Chronic inflammatory bowel disease is likely with a low possibility of an early neoplastic event such as lymphoma. Full thickness tissue biopsies via open laparotomy, ideally guided by intraoperative ultrasound in order to obtain the most representative mural sample, would be necessary to rule out this possibility.

## SEX

Neutered male

## AGE

8 years

### *Pancreas*

## WEIGHT

100.8 lbs

The base and limbs of the **pancreas** were observed to be largely isoechoic to surrounding omental fat. Pancreatic duct and capsular contour were acceptably normal and parenchyma respected normal curvilinear patterns. No overt evidence of active inflammatory or neoplastic disease was noted.

## INTERPRETED BY

Eric Lindquist, DMV  
DABVP, Cert. IVUSS

## ULTRASONOGRAPHIC FINDINGS

Mild intestinal thickening.

Otherwise, unremarkable abdomen.

## IMAGING PERFORMED BY

Elaina Petrone

## INTERPRETATION OF THE FINDINGS & FURTHER RECOMMENDATIONS

## HOSPITAL NAME

Long Branch AH

No neoplastic criteria was met throughout the abdomen. If GI signs are present then surgical biopsies would be necessary for further definition, yet no other pathology was noted.

## REFERRING VET

Dr. Petrone

Maldigestion panel, three view chest radiographs and full CNS examination is recommended to examine for occult disease that could be responsible for the weight loss. Evaluation for competitive eating environments should also be considered.

## INVOICE

69783

## DATE

1/5/26



**PATIENT**

Benny Riccio

**SPECIES**

Canine

**BREED**

Golden Retriever

**SEX**

Neutered male

**AGE**

8 years

**WEIGHT**

100.8 lbs

**INTERPRETED BY**

Eric Lindquist, DMV  
DABVP, Cert. IVUSS

**IMAGING  
PERFORMED BY**

Elaina Petrone

**HOSPITAL NAME**

Long Branch AH

**REFERRING VET**

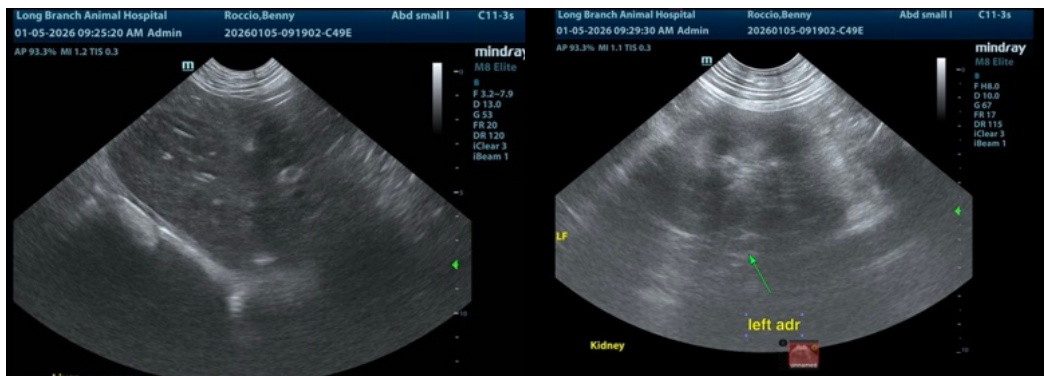
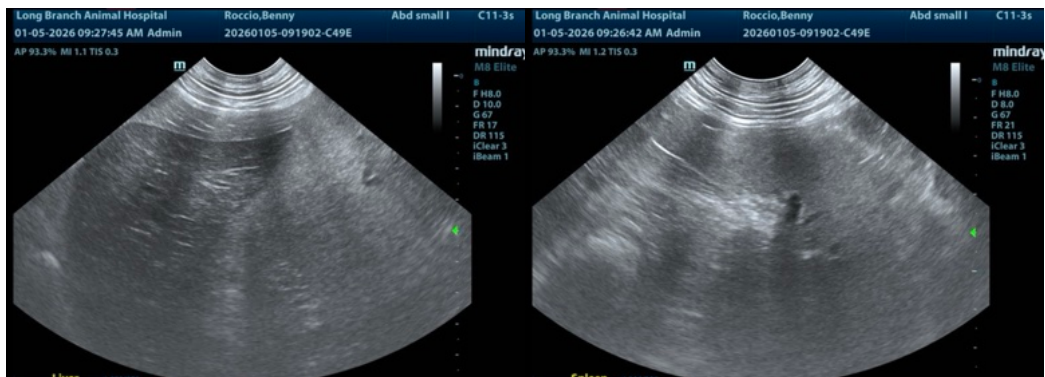
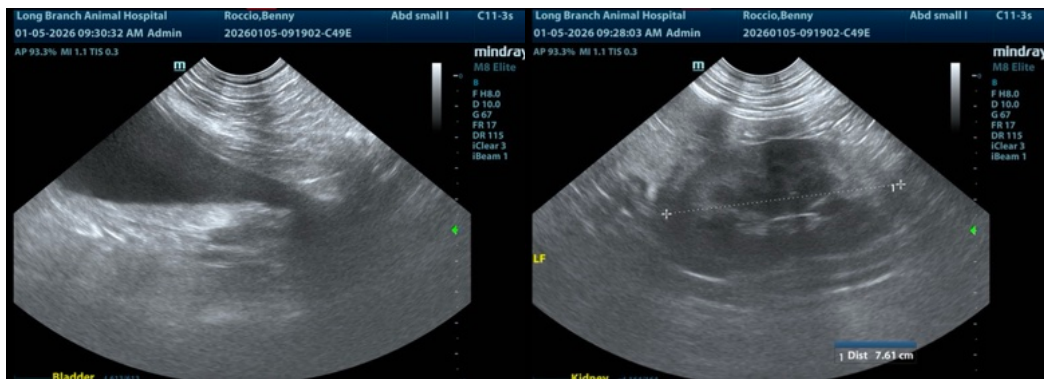
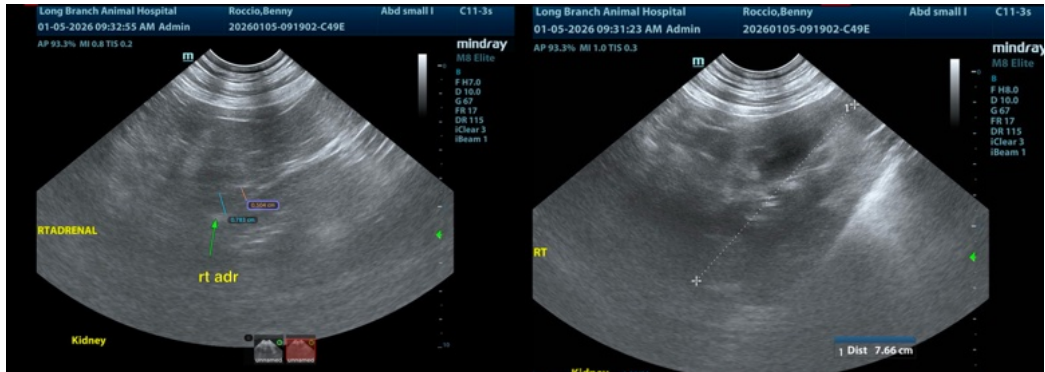
Dr. Petrone

**INVOICE**

69783

**DATE**

1/5/26





## PATIENT

Benny Riccio

## SPECIES

Canine

## BREED

Golden Retriever

## SEX

Neutered male

## AGE

8 years

## WEIGHT

100.8 lbs

## INTERPRETED BY

Eric Lindquist, DMV  
DABVP, Cert. IVUSS

## IMAGING PERFORMED BY

Elaina Petrone

## HOSPITAL NAME

Long Branch AH

## REFERRING VET

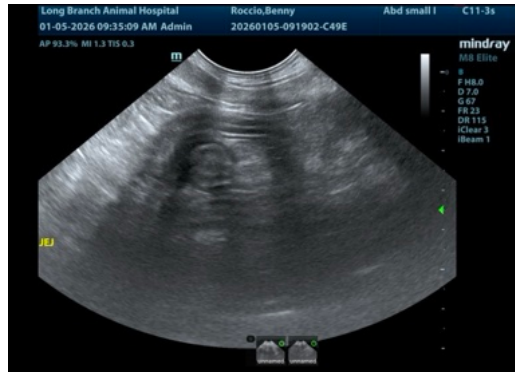Dr. Petrone

## INVOICE

69783

## DATE

1/5/26



The information and recommendations provided are based on the images presented by the referring veterinarian/sonographer. No evaluation can be communicated regarding pathology that was not visible in the image/video clips provided.

Thank you for this referral. If the clinical or image interpretation does not parallel your findings or if I can be of any further assistance please contact me.

Eric Lindquist, DMV, DABVP (CFM), Cert. IVUSS, CEO of SonoPath.com

[info@SonoPath.com](mailto:info@SonoPath.com)