



PATIENT

Axl Rose Lombardi

SPECIES

Canine

BREED

Maltese

SEX

Neutered male

AGE

10 years

WEIGHT

9.7 lbs

INTERPRETED BY

Eric Lindquist, DMV
DABVP, Cert. IVUSS

IMAGING PERFORMED BY

Dr. Ohad Barnea

HOSPITAL NAME

Tenafly VC

REFERRING VET

Dr. Barnea

INVOICE

69815

DATE

1/5/26

PRESENTING CLINICAL SIGNS

History: on urso this is a follow up doing well

ULTRASONOGRAPHIC EXAMINATION

The **liver** images from right and left intercostal as well as subcostal views revealed subjectively normal liver size, contour, and structure. Some age-related parenchymal remodeling was noted but likely not clinically significant at this time. Vascular and biliary tracts were of normal volume and no evidence of congestion was noted. The gallbladder revealed a minor amount of striating bile was noted as well as coalesced congealed bile at 2.2 cm. There was no significant over distension noted.

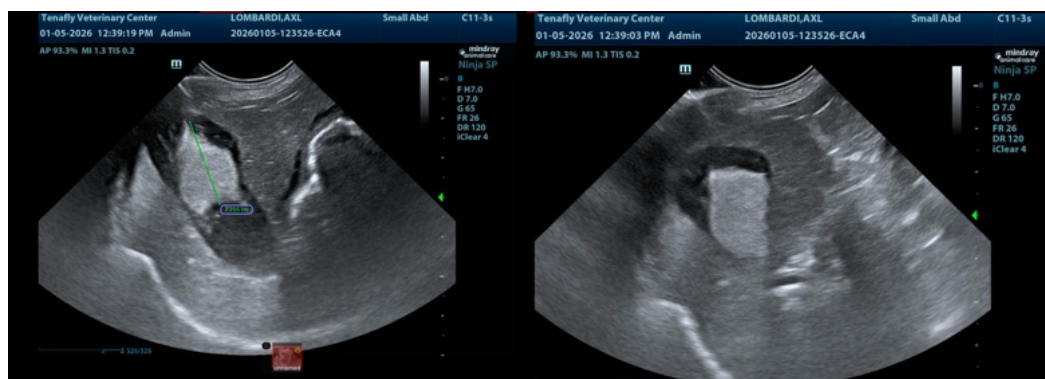
ULTRASONOGRAPHIC FINDINGS

Minor, residual excessive gallbladder congealed bile and striation.

Unremarkable age related hepatic changes.

INTERPRETATION OF THE FINDINGS & FURTHER RECOMMENDATIONS

Ursodiol therapy is recommended as a continual medical management.





PATIENT

Axl Rose Lombardi

SPECIES

Canine

BREED

Maltese

SEX

Neutered male

AGE

10 years

WEIGHT

9.7 lbs

INTERPRETED BY

Eric Lindquist, DMV
DABVP, Cert. IVUSS

IMAGING PERFORMED BY

Dr. Ohad Barnea

HOSPITAL NAME

Tenafly VC

REFERRING VET

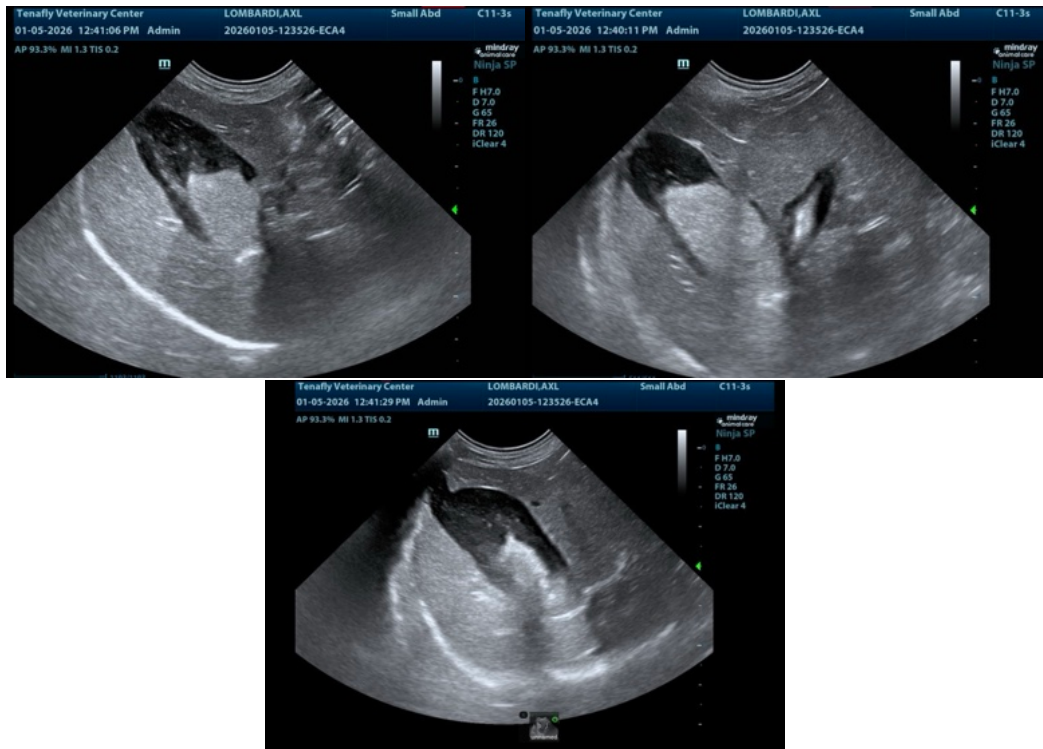
Dr. Barnea

INVOICE

69815

DATE

1/5/26



The information and recommendations provided are based on the images presented by the referring veterinarian/sonographer. No evaluation can be communicated regarding pathology that was not visible in the image/video clips provided.

Thank you for this referral. If the clinical or image interpretation does not parallel your findings or if I can be of any further assistance please contact me.

Eric Lindquist, DMV, DABVP (CFM), Cert. IVUSS, CEO of SonoPath.com

info@SonoPath.com