



PATIENT

Pea Carafelli

PRESENTING CLINICAL SIGNS

Presented today for acute vomiting and anorexia. Vocal, unkempt, weight loss, very painful on abdominal palpation, T= 98.9.

SPECIES

Feline

Abnormal PE/Chem/CBC/UA Results: BUN 51, ALT 141, Glu 170, Creat 1.6, USG 1.016

ULTRASONOGRAPHIC EXAMINATION OF THE ABDOMEN

BREED

DLH

Urinary System

The **urinary bladder**, trigone, and pelvic urethra presented normal thicknesses and normal tone. The ureters were not visible which is normal. No uroliths or sediment were visualized and anechoic urine was present. No evidence of inflammatory or neoplastic changes were noted. Ureteral papillae were normal.

SEX

Spayed Female

The **left kidney** revealed loss of corticomedullary definition and measured 2.9 cm in length. Minor pyelectasia and irregular contour noted.

AGE

17

The **right kidney** presented similar changes as the left, with cortical infarcts, cortical collapse, and pyelectasia. The right kidney measured 3.1 cm.

Adrenal Glands

WEIGHT

6

The regions of the **adrenal glands** were unremarkable.

Spleen

The **spleen** was folded upon itself caudally with slight irregular contour. Focal 5.0 mm expansion noted at the mid cranial body.

INTERPRETED BY

Eric Lindquist, DMV

Liver

The **liver** images submitted revealed subjectively normal liver size, contour, and structure. Parenchymal echogenicity was naturally coarse and hypoechoic to the spleen. Vascular and biliary tracts were of normal volume with no evidence of congestion. The gallbladder presented acceptably thin walls with primarily anechoic content. The cystic and common bile ducts were normal. No pathological hepatic lymphadenopathy was evident. No overt structural evidence of inflammatory, infiltrative or regenerative pathology was evident.

DABVP, Cert. IVUSS

IMAGING PERFORMED BY

Dr. Melissa Pascucci

HOSPITAL NAME

American AH

Gastrointestinal

The **stomach** revealed overdistention. Variable intestinal thickening noted with reactive mesentery. Some areas of loss of mural detail noted. Large amount of GI gas present.

REFERRING VET

Dr. Melissa Pascucci

Pancreas

The **pancreas** was hypoechoic and irregular with dilated duct. Both limbs appeared pathological with enhanced surrounding mesentery.

INVOICE

43952

ULTRASONOGRAPHIC FINDINGS

- Gastroenteritis/pancreatitis
- Concurrent nephritis likely
- Folded, slightly irregular spleen

DATE

1/5/23



PATIENT

Pea Carafelli

SPECIES

Feline

BREED

DLH

SEX

Spayed Female

AGE

17

WEIGHT

6

INTERPRETED BY

Eric Lindquist, DMV

DABVP, Cert. IVUSS

IMAGING PERFORMED BY

Dr. Melissa Pascucci

HOSPITAL NAME

American AH

REFERRING VET

Dr. Melissa Pascucci

INVOICE

43952

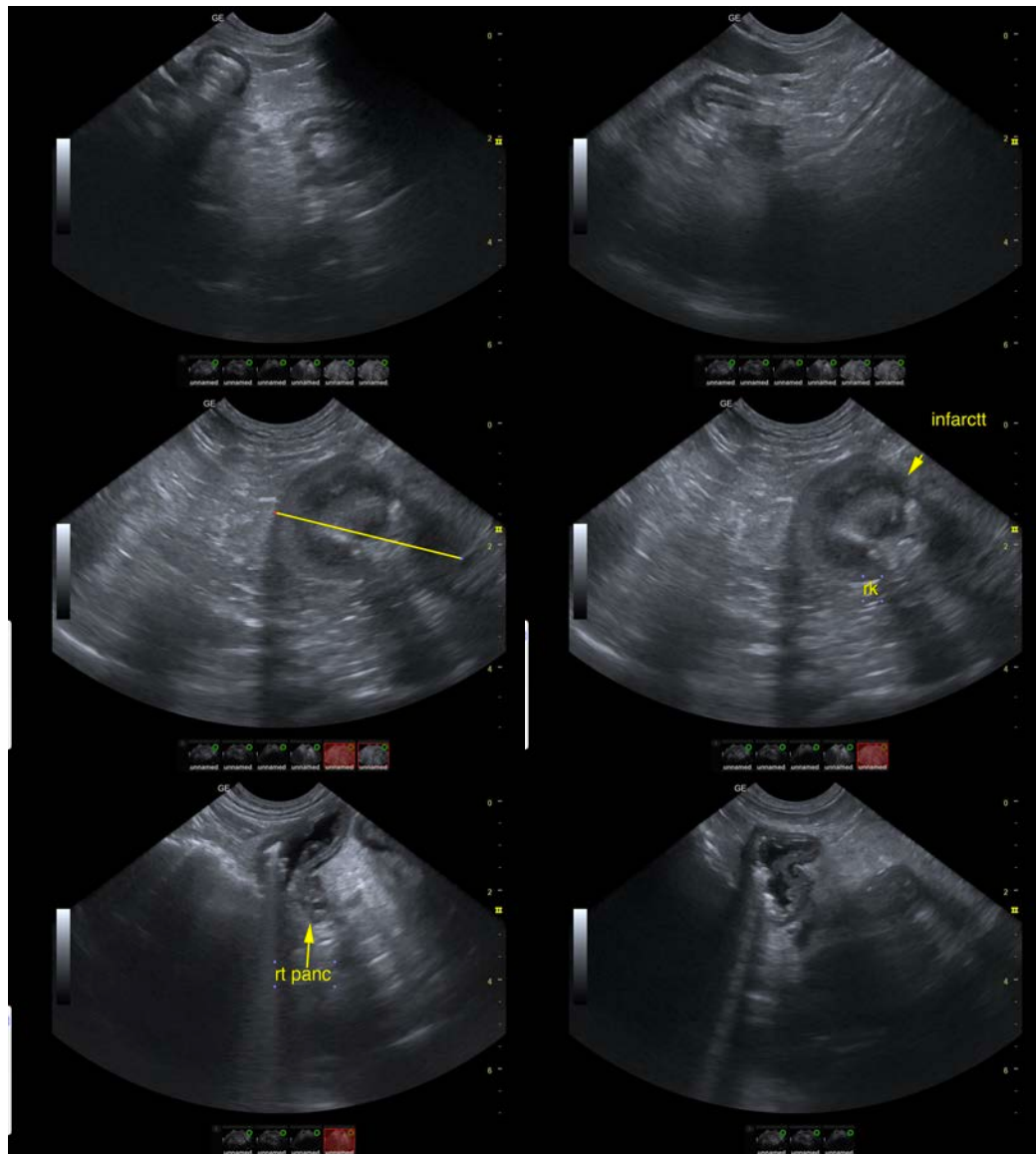
DATE

1/5/23

INTERPRETATION OF THE FINDINGS & FURTHER RECOMMENDATIONS

on chronic inflammatory bowel and pancreatitis with possible malassimilation of nutrients is a strong potential in this patient. However, emerging round cell neoplasia cannot be completely ruled out. The pathology of the GI tract is fairly extensive.

Recommend IV fluid support, broad-spectrum antibiotics, pain management, recheck sonogram in 48 hours. Full urinary workup warranted as well. Maldigestion panel, three view chest radiographs and full CNS examination is recommended to examine for occult disease that could be responsible for the weight loss. Evaluation for competitive eating environments should also be considered.





PATIENT

Pea Carafelli

SPECIES

Feline

BREED

DLH

SEX

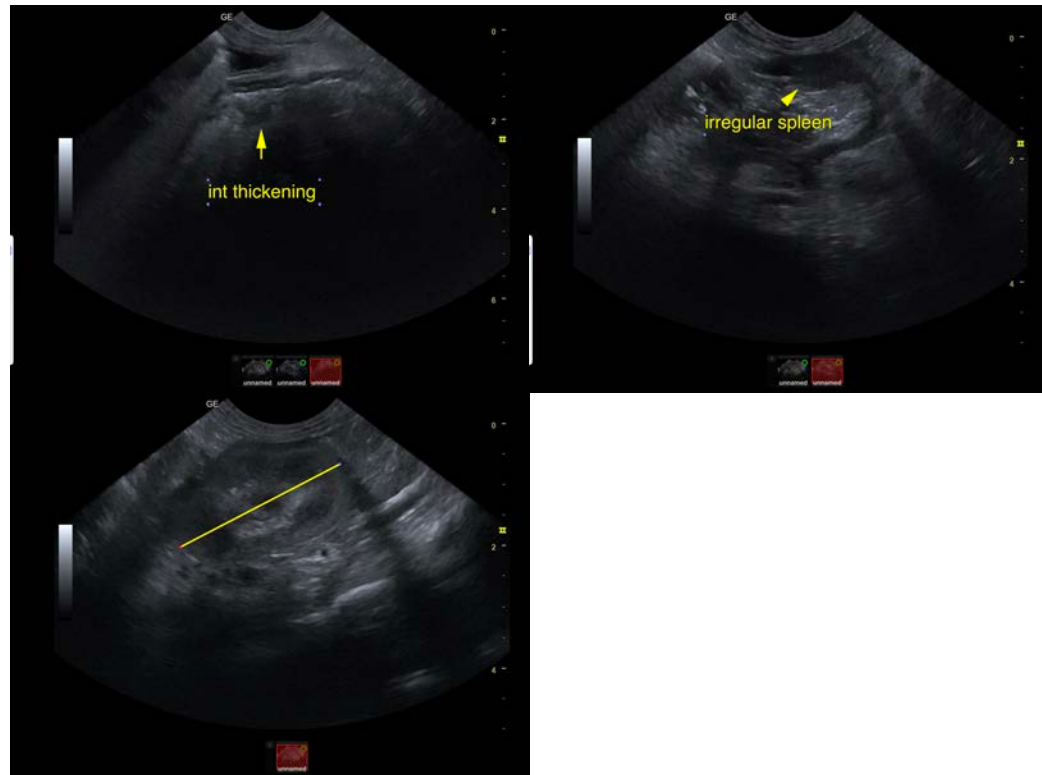Spayed Female

AGE

17

WEIGHT

6



INTERPRETED BY

Eric Lindquist, DMV
DABVP, Cert. IVUSS

IMAGING PERFORMED BY

Dr. Melissa Pascucci

HOSPITAL NAME

American AH

REFERRING VET

Dr. Melissa Pascucci

INVOICE

43952

DATE

1/5/23

The information and recommendations provided are based on the images presented by the referring veterinarian/sonographer. No evaluation can be communicated regarding pathology that was not visible in the image/video clips provided.

Thank you for this referral. If the clinical or image interpretation does not parallel your findings or if I can be of any further assistance please contact me.

Eric Lindquist, DMV, DABVP, Cert. IVUSS, CEO of SonoPath.com

info@SonoPath.com