



PATIENT

Louie Pursley

SPECIES

Canine

BREED

Poodle

SEX

Male

AGE

1 Year

WEIGHT

5.2

INTERPRETED BY

Eric Lindquist, DMV
DABVP, Cert. IVUSS

IMAGING PERFORMED BY

Mayra Sanchez

HOSPITAL NAME

Sunset AH

REFERRING VET

Mayra Sanchez

INVOICE

20405

DATE

1/5/23

PRESENTING CLINICAL SIGNS

Pre-op lab work for neuter showed elevated ALT -ALT returned to normal with Denamarin x 1 month - Now ALT elevated again -Chronic low BCS

Abnormal PE/Chem/CBC/UA Results: PE: BCS 3/9 Chem: ALT 229 on 8/18/22, 86 on 10/16/22, 129 on 12/20/22 SBA: Pre 19.2 (<13), Post 22.7 (<25)

ULTRASONOGRAPHIC EXAMINATION OF THE ABDOMEN

Urinary System

The **urinary bladder**, trigone, and pelvic urethra presented normal thicknesses and normal tone. The ureters were not visible which is normal. No uroliths or sediment were visualized, and anechoic urine was present. No evidence of inflammatory or neoplastic changes were noted. Ureteral papillae were normal.

The **kidneys** revealed normal size and structure, corticomedullary definition and ratio for this age. The cortices presented largely uniform texture with normal echogenic relationship to liver and spleen. Medullary structure differed distinctly from the cortex and no evidence of pelvic dilation was present. The capsules were acceptably uniform without significant irregularities. The kidneys measured 3.0 cm each.

Adrenal Glands

Both **adrenal glands** were visualized and recognized as having normal shape, size, position and echogenicity for this breed. The phrenic vasculature, glandular echogenicity and detail were unremarkable. Capsule, cortex, and medullary definition were normal for this age patient. The left adrenal gland measured 0.4 cm. The right adrenal gland measured 0.4 cm at the cranial pole and 0.3 cm at the caudal pole.

Spleen

The **spleen** presented a smooth homogeneous parenchyma hyperechoic to liver and renal cortical parenchyma. The capsule was smooth without noticeable expansion or deviation from within the spleen or adjacent pathology. The splenic vasculature demonstrated normal volume without signs of congestion or thrombosis. No sonographic evidence of acute or chronic inflammatory, neoplastic, or infarctual changes were noted.

Liver

The **liver** was slightly subnormal in size. The gallbladder and common bile duct were unremarkable.

Gastrointestinal

Examination of the **gastrointestinal tract** revealed a stomach and intestine free of stasis, of normal wall thickness, acceptable curvilinear mural detail, and peristaltic activity. Small and large intestine demonstrated normal luminal chyme and stool consistency respectively. No obstructive or overt infiltrative disease was noted. No associated abnormal lymphatic activity was noted.

Pancreas



PATIENT

Louie Pursley

The base and limbs of the **pancreas** were observed to be largely isoechoic to surrounding omental fat. Pancreatic duct and capsular contour were acceptably normal and parenchyma respected normal curvilinear patterns. No overt evidence of active inflammatory or neoplastic disease was noted.

SPECIES

Canine

ULTRASONOGRAPHIC FINDINGS

- Structurally unremarkable abdomen
- Nonspecific inflammatory hepatopathy, given the elevated liver values yet structurally the liver appears normal. This is likely reactive hepatopathy.

BREED

Poodle

INTERPRETATION OF THE FINDINGS & FURTHER RECOMMENDATIONS

No contraindications to anesthetic procedure. FNA of the liver could be considered at the time of sedation, if necessary. No evidence of intrahepatic or extrahepatic shunting.

SEX

Male

AGE

1 Year

WEIGHT

5.2

INTERPRETED BY

Eric Lindquist, DMV
DABVP, Cert. IVUSS

IMAGING PERFORMED BY

Mayra Sanchez

HOSPITAL NAME

Sunset AH

REFERRING VET

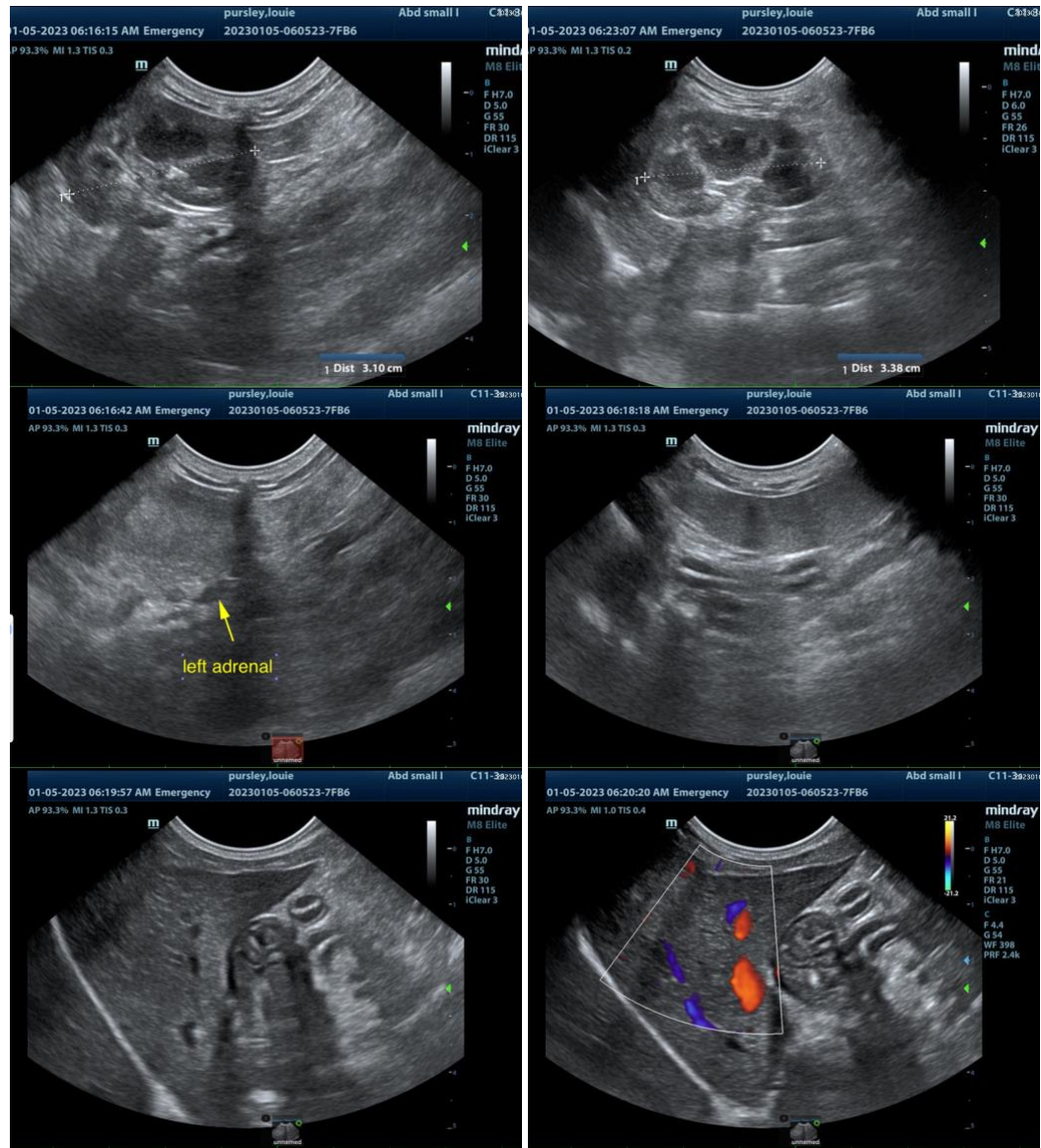
Mayra Sanchez

INVOICE

20405

DATE

1/5/23





PATIENT

Louie Pursley

SPECIES

Canine

BREED

Poodle

SEX

Male

AGE

1 Year

WEIGHT

5.2

INTERPRETED BY

Eric Lindquist, DMV
DABVP, Cert. IVUSS

IMAGING PERFORMED BY

Mayra Sanchez

HOSPITAL NAME

Sunset AH

REFERRING VET

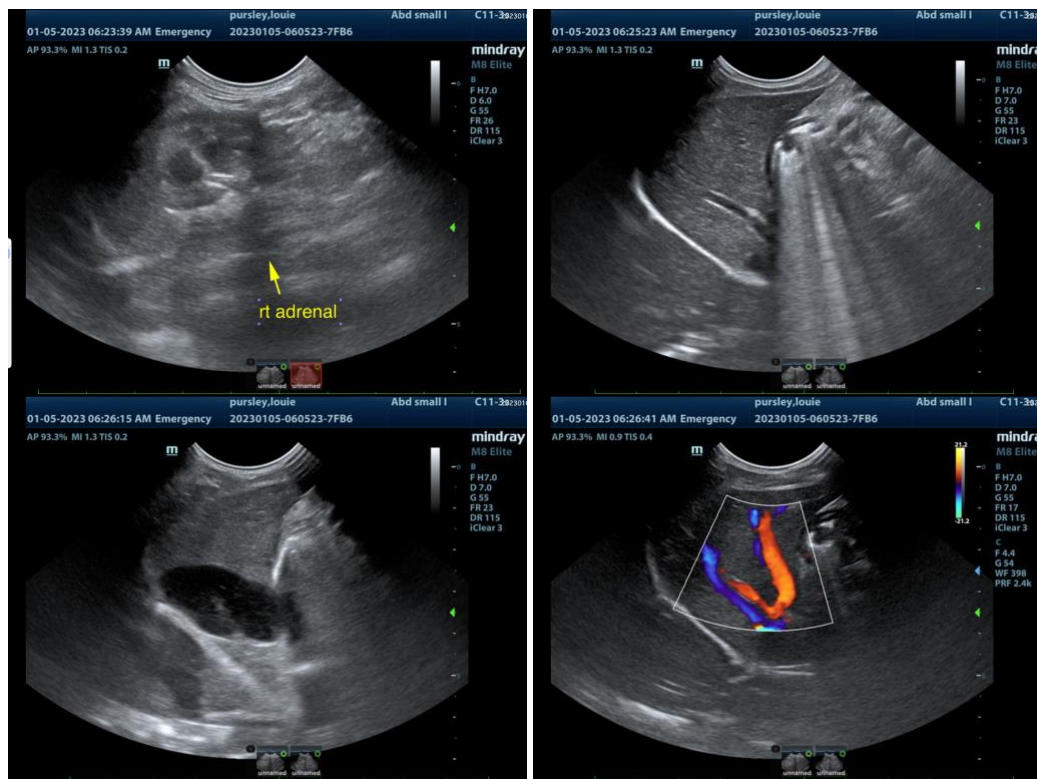
Mayra Sanchez

INVOICE

20405

DATE

1/5/23



The information and recommendations provided are based on the images presented by the referring veterinarian. No evaluation can be communicated regarding pathology that was not visible in the image/video clips provided.

Thank you for this referral. If the clinical or image interpretation does not parallel your findings or if I can be of any further assistance please contact me.

Eric Lindquist, DMV, DABVP, Cert. IVUSS, CEO of SonoPath.com
info@SonoPath.com