



PATIENT

Lola Hoffman

PRESENTING CLINICAL SIGNS

History: delayed gastric emptying and constipation R/O FB vs IBD vs other

SPECIES

Feline

ULTRASONOGRAPHIC EXAMINATION OF THE ABDOMEN

Urinary System

The **urinary bladder**, trigone, and pelvic urethra presented normal thicknesses and normal tone. The ureters were not visible which is normal. No uroliths or sediment were visualized, and anechoic urine was present. No evidence of inflammatory or neoplastic changes were noted. Ureteral papillae were normal. The pelvic urethra was imaged 2.0 cm beyond the cystourethral junction.

BREED

DSH

SEX

Spayed Female

The **kidneys** revealed normal size and structure, corticomedullary definition and ratio for this age. The cortices presented largely uniform texture with normal echogenic relationship to liver and spleen. Medullary structure differed distinctly from the cortex and no evidence of pelvic dilation was present. The capsules were acceptably uniform without significant irregularities. The right kidney measured 3.28 cm. The left kidney measured 3.6 cm.

AGE

7

Adrenal Glands

The regions of the **adrenal glands** revealed no evidence of pathology.

WEIGHT

7.3

Spleen

The **spleen** presented a smooth homogeneous parenchyma hyperechoic to liver and renal cortical parenchyma. The capsule was smooth without noticeable expansion or deviation from within the spleen or adjacent pathology. The splenic vasculature demonstrated normal volume without signs of congestion or thrombosis. No sonographic evidence of acute or chronic inflammatory, neoplastic, or infarctual changes were noted.

INTERPRETED BY

Eric Lindquist, DMV
DABVP, Cert. IVUSS

Liver

The **liver** images from right and left intercostal as well as subcostal views revealed subjectively normal liver size, contour, and structure. Some minor age-related parenchymal remodeling was noted but likely not clinically significant at this time. Vascular and biliary tracts were of normal volume and no evidence of congestion was noted. The gallbladder presented some dependent debris with essentially normal contour. The cystic and common bile ducts were normal. No overt evidence of active inflammatory, infiltrative or regenerative pathology was noted but should be paired with current or past LE elevations regarding any clinical significance to this presentation. The hepatic lymph nodes were unremarkable.

IMAGING PERFORMED BY

Jenn

HOSPITAL NAME

Rockaway AH

Gastrointestinal

The **gastrointestinal tract** presented considerable gastric artifact due to the presence of ingesta. This did not permit thorough evaluation of portions of the gastric and upper intestinal structure. No overt abnormality was seen in the visualized tissue, however. This is consistent with a post-prandial presentation within a few hours of mealtime. If the prandial temporal interval does not fit the case history, and the patient presents a history of post-prandial vomiting, this could indicate a delayed upper gastrointestinal outflow due to primary or secondary pyloric hypertrophy, upper GI infiltrative disease, motor deficits, or a non-visualized foreign body. A prudent approach would be to rescan this

REFERRING VET

Dr. Ascot

INVOICE

20381

DATE

1/5/23



PATIENT

Lola Hoffman

patient at 24-hour NPO status to further review the non-visible regions if stomach primarily as well as assess any delayed outflow issue.

Pancreas

SPECIES

Feline

The base and limbs of the **pancreas** were observed to be largely isoechoic to surrounding omental fat. Pancreatic duct and capsular contour were acceptably normal and parenchyma respected normal curvilinear patterns. No overt evidence of active inflammatory or neoplastic disease was noted.

BREED

DSH

ULTRASONOGRAPHIC FINDINGS

- Unremarkable abdomen
- Postprandial presentation

SEX

Spayed Female

INTERPRETATION OF THE FINDINGS & FURTHER RECOMMENDATIONS

No evidence of pathology. Supportive care should prove effective.

AGE

7

WEIGHT

7.3

INTERPRETED BY

Eric Lindquist, DMV
DABVP, Cert. IVUS

IMAGING PERFORMED BY

Jenn

HOSPITAL NAME

Rockaway AH

REFERRING VET

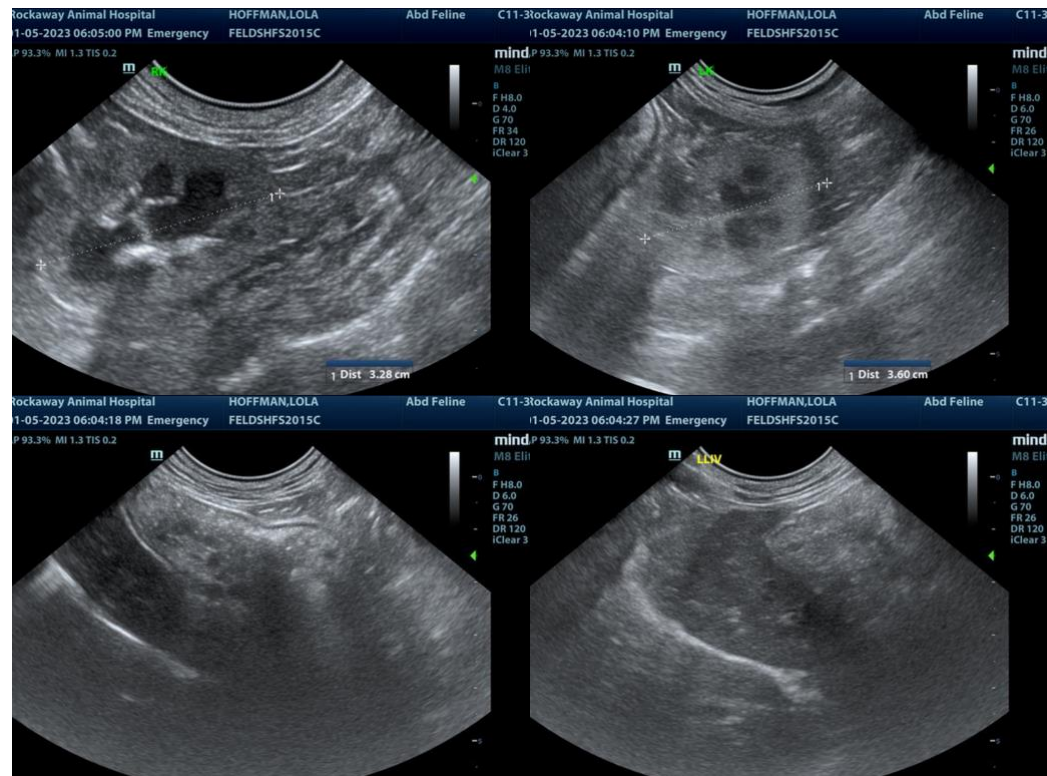
Dr. Ascot

INVOICE

20381

DATE

1/5/23





PATIENT

Lola Hoffman

SPECIES

Feline

BREED

DSH

SEX

Spayed Female

AGE

7

WEIGHT

7.3

INTERPRETED BY

Eric Lindquist, DMV
DABVP, Cert. IVUSS

IMAGING PERFORMED BY

Jenn

HOSPITAL NAME

Rockaway AH

REFERRING VET

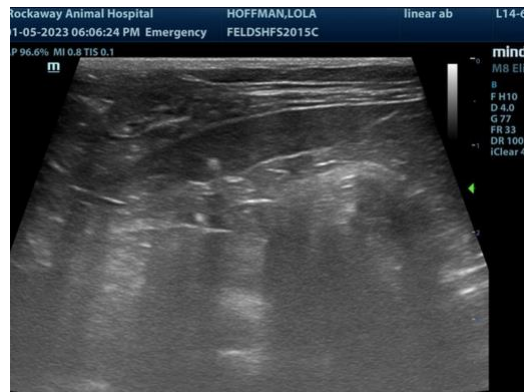Dr. Ascot

INVOICE

20381

DATE

1/5/23



The information and recommendations provided are based on the images presented by the referring veterinarian. No evaluation can be communicated regarding pathology that was not visible in the image/video clips provided.

Thank you for this referral. If the clinical or image interpretation does not parallel your findings or if I can be of any further assistance please contact me.

Eric Lindquist, DMV, DABVP, Cert. IVUSS, CEO of SonoPath.com
info@SonoPath.com