



**PATIENT**

Chloe Elstein

**SPECIES**

Canine

**BREED**

Mini Australian Shepherd

**SEX**

Spayed Female

**AGE**

9 Years

**WEIGHT**

33.8 Pounds

**INTERPRETED BY**

Eric Lindquist, DMV

DABVP, Cert. IVUSS

**IMAGING PERFORMED BY**

Dr. Kyoung Han

**HOSPITAL NAME**

Tenafly Vet Center

**REFERRING VET**

Dr. Kyoung Han

**INVOICE**

44005

**DATE**

1/5/23

**PRESENTING CLINICAL SIGNS**

Recurrent UTI without clinical symptoms ( urine culture and sensitivity test result shows : ecoli ) . normal blood work result. last urinalysis result shows 2+epicellial cell. want to rule out pyelonephritis, bladder tumor and urolith. normal location of ureter opening?

**ULTRASONOGRAPHIC EXAMINATION OF THE ABDOMEN**

**Urinary System**

The **urinary bladder**, trigone, and pelvic urethra presented normal thicknesses and normal tone. The ureters were not visible which is normal. No uroliths or sediment were visualized and anechoic urine was present. No evidence of inflammatory or neoplastic changes were noted. Ureteral papillae were normal. The pelvic urethra was imaged 2.0 cm beyond the cystourethral junction.

The **kidneys** revealed largely normal size and structure, corticomedullary definition and ratio (cortex 1/3 of medulla) were essentially maintained with some age-related loss of curvilinear patterns regarding the capsule and C/M junction. The cortices presented largely uniform texture with some increased echogenicity expected for his age patient. Medullary structure differed distinctly from that of the cortex and no evidence of pelvic dilation was present. The kidneys measured 4.0 cm each.

**Adrenal Glands**

The regions of the **adrenal glands** were unremarkable.

**Spleen**

The **spleen** presented a smooth homogeneous parenchyma hyperechoic to liver and renal cortical parenchyma. The spleen was folded upon itself caudally. The capsule was smooth without noticeable expansion or deviation from within the spleen or adjacent pathology. The splenic vasculature demonstrated normal volume without signs of congestion or thrombosis. No sonographic evidence of acute or chronic inflammatory, neoplastic, or infarctual changes were noted.

**Liver**

The **liver** images from right and left intercostal as well as subcostal views revealed subjectively normal liver size, contour, and structure. Some age-related parenchymal remodeling was noted but likely not clinically significant at this time. Vascular and biliary tracts were of normal volume and no evidence of congestion was noted. The gallbladder presented some dependent debris with essentially normal contour. The cystic and common bile ducts were normal. No overt evidence of active inflammatory, infiltrative or regenerative pathology was noted but should be paired with current or past LE elevations regarding any clinical significance to this presentation. The hepatic lymph nodes were unremarkable.

**Gastrointestinal**

Examination of the **gastrointestinal tract** revealed a stomach and intestine free of stasis, of normal wall thickness, acceptable curvilinear mural detail, and peristaltic activity. Small and large intestine demonstrated normal luminal chyme and stool consistency respectively. No obstructive or overt infiltrative disease was noted. No associated abnormal lymphatic activity was noted.

**Pancreas**

The base and limbs of the **pancreas** were observed to be largely isoechoic to surrounding omental fat. Pancreatic duct and capsular contour were acceptably normal and parenchyma respected normal curvilinear patterns. No overt evidence of active inflammatory or neoplastic disease was noted.



**PATIENT**

Chloe Elstein

**ULTRASONOGRAPHIC FINDINGS**

- Structurally unremarkable abdomen with age related changes

**SPECIES**

Canine

**INTERPRETATION OF THE FINDINGS & FURTHER RECOMMENDATIONS**

Predisposing issues such as recessed vulva or urine pooling should be considered in this patient.

**BREED**

Mini Australian Shepherd

**Chronic UTI Protocol**

I recommend **Enrofloxacin** (5-10 mg/kg SID PO) (In patients > 1 year of age) in late pm after urination to maximize urinary concentrations overnight. This assumes that culture supports this use. Repeat **culture** at 3-4 weeks and continue treatment at least 7-10 days post negative urinary sediment and negative culture. *Note: Negative culture does not necessarily mean lack of UTI.* Other favorite antibiotics for chronic UTI include third generation Cefa (Ceftiafur or similar s.i.d. injectable) or Clavamox. If suspicion of occult urinary incontinence is present then **phenylpropanolamine (PPA)** (1-2 mg/kg BID) can be employed long term to enhance urethral tone.

**AGE**

9 Years

**WEIGHT**

33.8 Pounds

**INTERPRETED BY**

Eric Lindquist, DMV  
DABVP, Cert. IVUSS

**IMAGING PERFORMED BY**

Dr. Kyoung Han

**HOSPITAL NAME**

Tenafly Vet Center

**REFERRING VET**

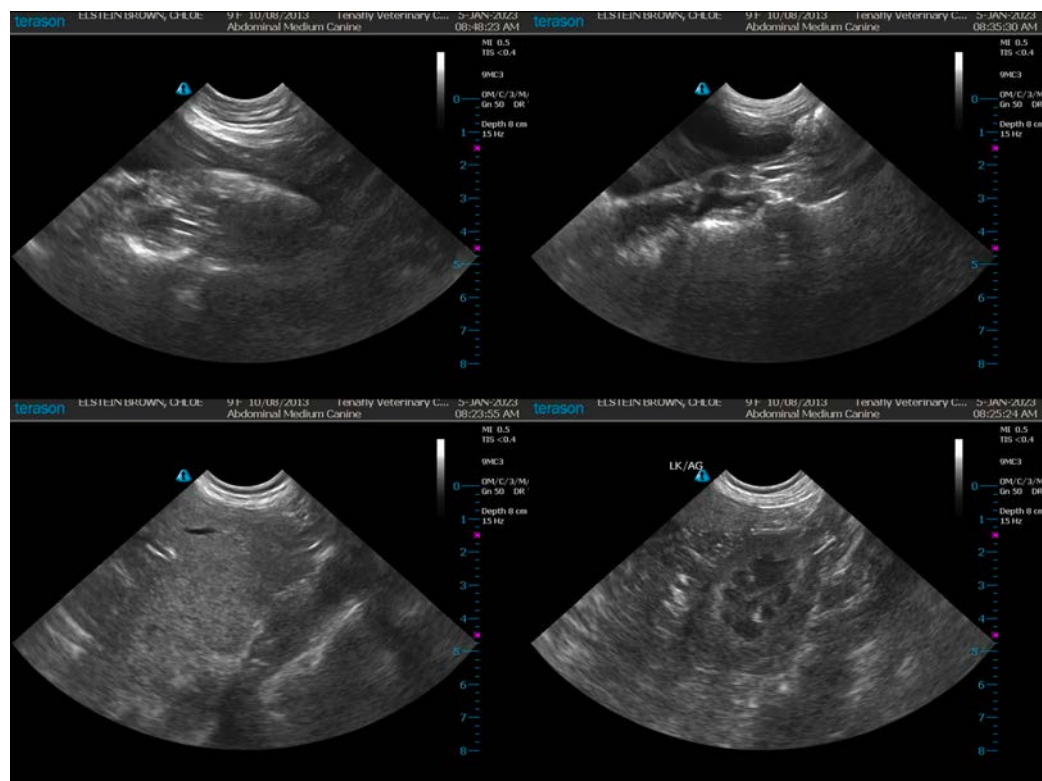
Dr. Kyoung Han

**INVOICE**

44005

**DATE**

1/5/23





**PATIENT**

Chloe Elstein

**SPECIES**

Canine

**BREED**

Mini Australian Shepherd

**SEX**

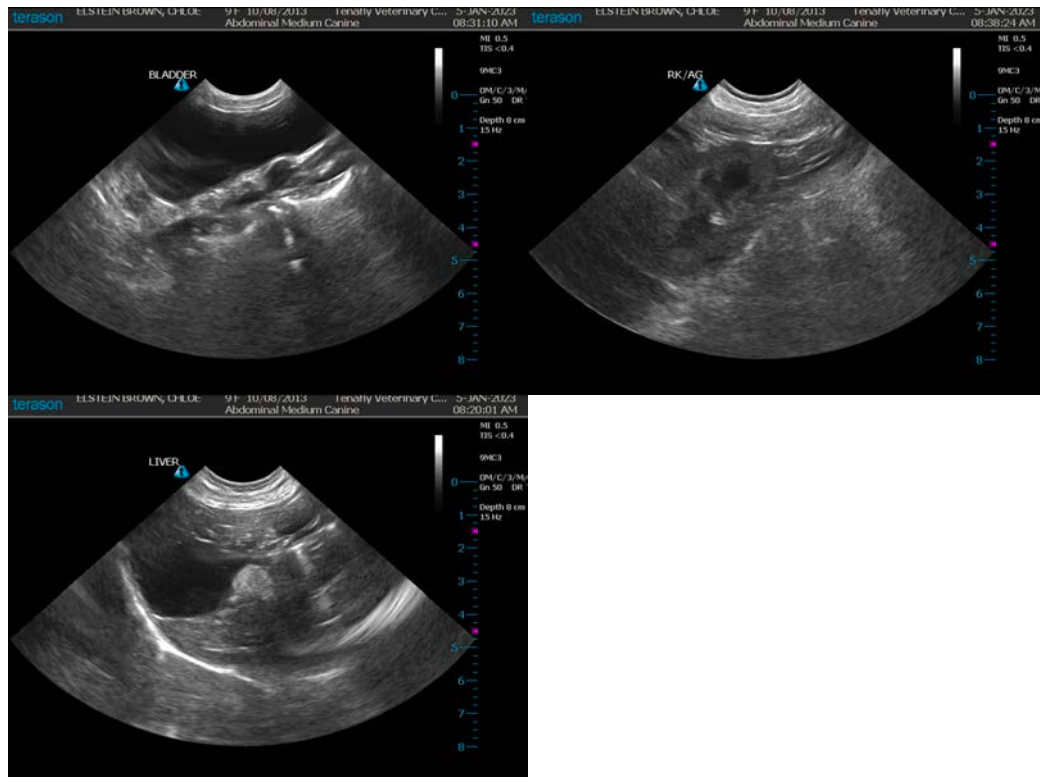Spayed Female

**AGE**

9 Years

**WEIGHT**

33.8 Pounds



**INTERPRETED BY**

Eric Lindquist, DMV  
DABVP, Cert. IVUSS

**IMAGING PERFORMED BY**

Dr. Kyoung Han

**HOSPITAL NAME**

Tenafly Vet Center

**REFERRING VET**

Dr. Kyoung Han

**INVOICE**

44005

**DATE**

1/5/23

The information and recommendations provided are based on the images presented by the referring veterinarian/sonographer. No evaluation can be communicated regarding pathology that was not visible in the image/video clips provided.

Thank you for this referral. If the clinical or image interpretation does not parallel your findings or if I can be of any further assistance please contact me.

Eric Lindquist, DMV, DABVP, Cert. IVUSS, CEO of SonoPath.com

[info@SonoPath.com](mailto:info@SonoPath.com)