



## PATIENT PRESENTING CLINICAL SIGNS

Thor Nolasco heart murmur underweight

## SPECIES ULTRASONOGRAPHIC EXAMINATION OF THE HEART

Canine

BREED

Mastiff X

SEX

Intact Male

AGE

9 Months

WEIGHT

Unknown

CANINE CARDIAC PARAMETERS	MR VMAX (m/s)	TR VMAX (m/s)	LA/AO (Boon method)	LA/AO (Heart Base; Swe)	FS (%)	EF (%)	EPSS (cm)
NORMAL PARAMETER	4.5-5.5	<2.7	1.3	<1.6	28-40	40-100	<0.6
PATIENT	6.3	2.8	1.3		31	61	0.25
CANINE CARDIAC PARAMETERS	HR (BPM)	AV VMAX (m/s)	PV MAX (m/s)	BODY WEIGHT (kg)	LA 2D short axis Base view (cm)	LVIDd Avg; 2D and m-mode short axis (cm)	LVIDs Avg; 2D and m-mode short axis (cm)
NORMAL PARAMETER	50-100	0.7-1.7	0.7-1.6				
PATIENT	82	6.0	1.3		3.8	3.35	

### Cardiac Presentation

The echocardiogram in this patient demonstrated normal **left atrial** size based on 3 separate methods of LA evaluation. Mitral insufficiency noted at 6.3 m/sec. Concentric left ventricular hypertrophy noted in this patient with hypercontractility. The **myocardium** presented normal echogenicity without subjective evidence of significant fibrotic or ischemic disease. Aortic velocity was excessive at 6.0 m/sec with secondary aortic insufficiency at 5.0 m/sec. The **right atrium** and auricle revealed normal size, structure and content. No evidence of masses was noted. **Tricuspid** insufficiency noted at 2.8 m/sec. The **right ventricle** was of normal size (1/3 diameter of LV), chordae structure, myocardial echogenicity and thickness. **Pulmonary outflow** tract assessment revealed normal valve structure, laminar flow, and diameter (approx. 1:1 pa/ao ratio). No visible **pericardial** or free pleura fluid was noted. The cranial **mediastinum** and **pericardial** and **extra-cardiac** regions were free of masses in the visible window. Periodic arrhythmia noted.

### ULTRASONOGRAPHIC FINDINGS

- Subaortic stenosis with concurrent mitral and tricuspid insufficiency
- Secondary left ventricular hypertrophy
- Periodic arrhythmia

DATE

1/5/22

INVOICE

33979

### INTERPRETATION OF THE FINDINGS & FURTHER RECOMMENDATIONS

Atenolol therapy should be considered in this patient depending upon EKG results. Guarded to poor long-term prognosis. Blood pressure measurements indicated if not already performed.

### INTERPRETED BY

Eric Lindquist, DMV,  
DABVP, Cert. IVUS

### IMAGING PERFORMED BY

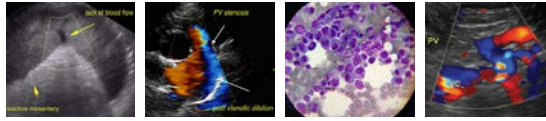
Jenna Walsh, CVT

### HOSPITAL NAME

The Pet Clinic

### REFERRING VET

Dr. Genova



**PATIENT**

Thor Nolasco

**SPECIES**

Canine

**BREED**

Mastiff X

**SEX**

Intact Male

**AGE**

9 Months

**WEIGHT**

Unknown

**INTERPRETED BY**

Eric Lindquist, DMV,  
DABVP, Cert. IVUSS

**IMAGING PERFORMED BY**

Jenna Walsh, CVT

**HOSPITAL NAME**

The Pet Clinic

**REFERRING VET**

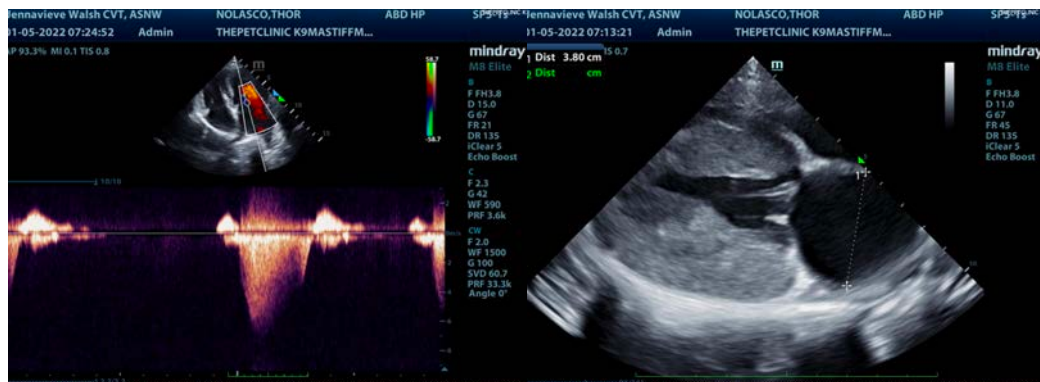
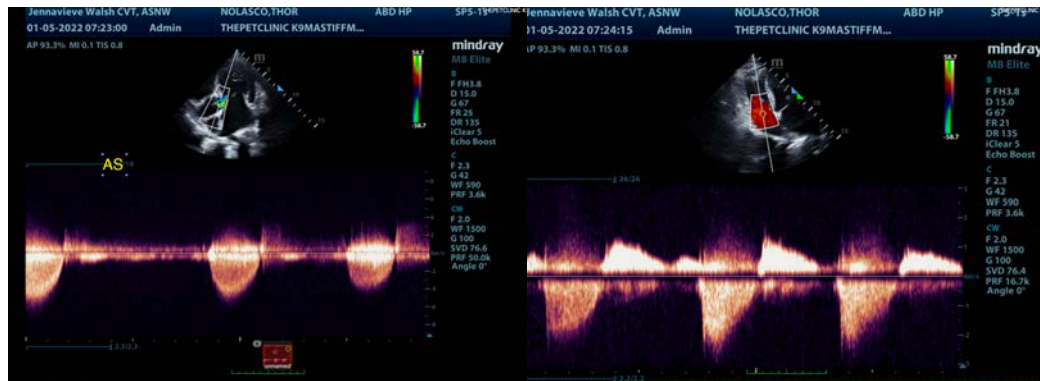
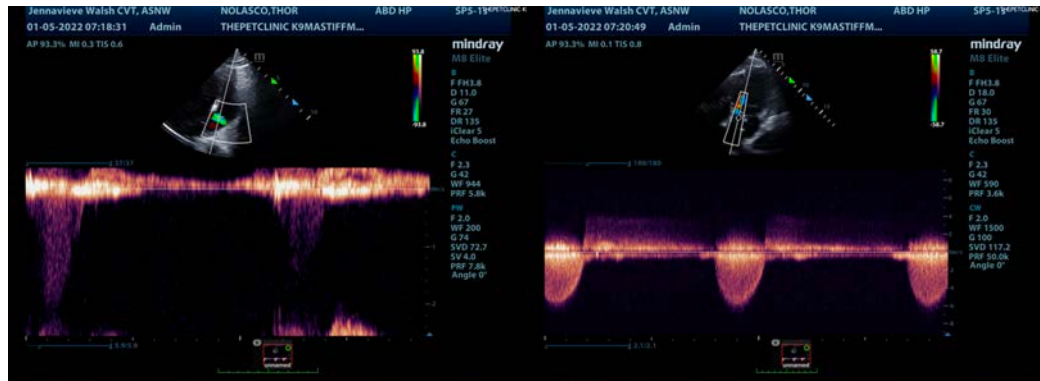
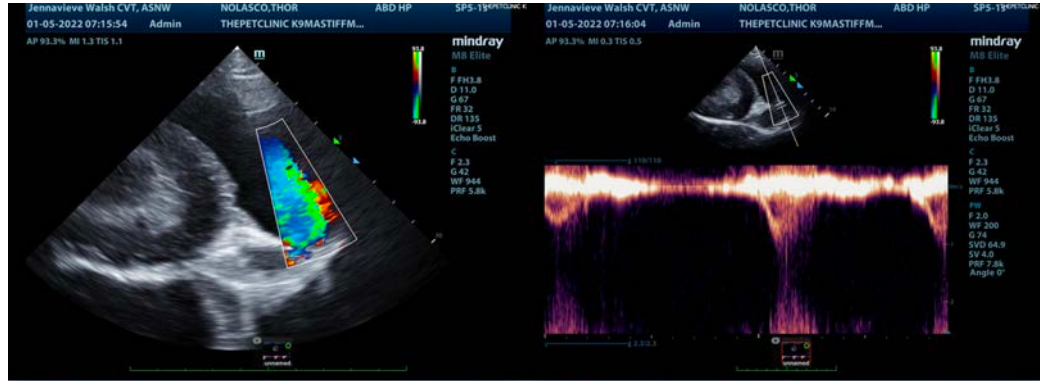
Dr. Genova

**DATE**

1/5/22

**INVOICE**

33979





**PATIENT**

Thor Nolasco

**SPECIES**

Canine

**BREED**

Mastiff X

**SEX**

Intact Male

**AGE**

9 Months

**WEIGHT**

Unknown

**INTERPRETED BY**

Eric Lindquist, DMV,  
DABVP, Cert. IVUSS

**IMAGING  
PERFORMED BY**

Jenna Walsh, CVT

**HOSPITAL NAME**

The Pet Clinic

**REFERRING VET**

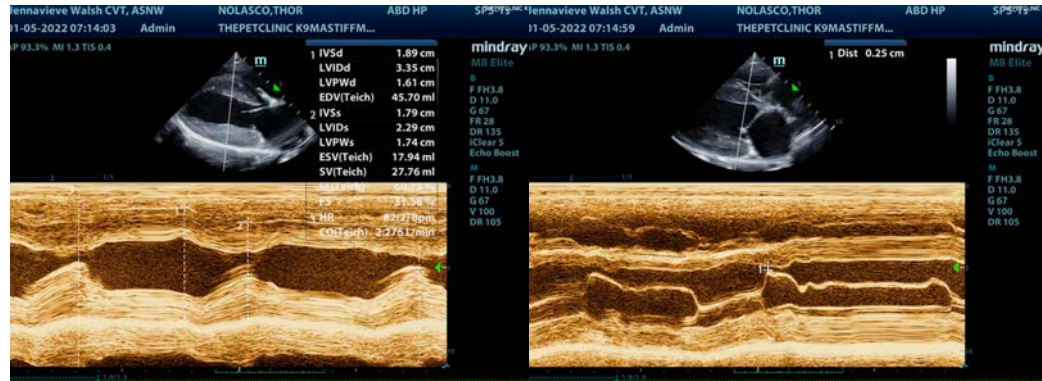
Dr. Genova

**DATE**

1/5/22

**INVOICE**

33979



The information and recommendations provided are based on the images presented by the referring veterinarian. No evaluation can be communicated regarding pathology that was not visible in the image/video clips provided.

Thank you for this referral. If the clinical or image interpretation does not parallel your findings or if I can be of any further assistance please contact me.

**Eric Lindquist, DMV, DABVP, Cert. IVUSS**  
 CEO of Sonopath.com  
 Eric.Lindquist@SonoPath.com