



**PATIENT PRESENTING CLINICAL SIGNS**

Sasha Nannis Grade II/VI left sided systolic murmur ausculted on routine examination on 12/23/21. Pro BNP=946 (0-100). Mild cardiomegaly visible on thoracic radiographs. Screening for hypertrophic cardiomyopathy. Average systolic blood pressure is 152mmHg.

**SPECIES**

Feline

**BREED ULTRASONOGRAPHIC EXAMINATION OF THE HEART**

Domestic Shorthair

**SEX**

Spayed Female

**AGE**

6 years

**WEIGHT**

11.92 lbs

The echocardiogram in this patient demonstrated normal **left atrial** size and structure with no evidence of “smoke” or thrombi. The cranial and caudal **mitral valve** leaflets appeared mildly thickened with some insufficiency noted on Doppler. The **left ventricle** presented excessive free wall and septal thicknesses with hypertrophic thicknesses compared to normal for this species. The **myocardium** presented essentially normal echogenicity without immediate signs of fibrotic or ischemic disease. **Contractility** of the ventricular walls was considered excessive for this patient evidenced by the elevated fractional shortening measurement. The **left ventricular outflow** tract demonstrated turbulent laminar flow. Subjective assessment of the **right atrium** and auricle revealed normal size, structure and content. No evidence of masses was noted. **Tricuspid** valvular assessment demonstrated linear morphology. The **right ventricle** was of normal size with normal chordae structure, myocardial echogenicity and thickness. **Pulmonic** tract assessment revealed normal valve structure, laminar flow, and diameter. No visible **pericardial** or free pleura fluid was noted. No echographically detectable evidence of infiltrative disease was visible. The **mediastinum** was free of masses in the visible window.

**INTERPRETED BY**

Eric Lindquist, DMV  
DABVP, Cert. IVUSS

**IMAGING PERFORMED BY**

Dr. Tenorio

**HOSPITAL NAME**

Wauwautosa VC

**REFERRING VET**

Dr. Haynes

**INVOICE**

95027

**DATE**

1/5/22

FELINE CARDIAC PARAMETERS	BODY WEIGHT (kg)	HR (BPM)	IVSd (cm)	LVIDd (cm)	LVWd (cm)	FS (%)	EF (%)
NORMAL PARAMETER	-----	150-240	0.3-0.6	1.0-2.1	0.25-0.6	35-67	80-100
PATIENT		NM	0.8	1.1	0.8	50	85
FELINE CARDIAC PARAMETERS	LA/AO (Boon)	LA/AO HEART BASE (Sisson)	LA 2D 4-chamber long axis AS to FW (Sisson) (cm)	LVOT VEL. (m/s)	RVOT VEL. (m/s)	IVRT (m/)	
NORMAL PARAMETER	<1.5	0.88-1.79	0.7-1.7	<1.6	<1.3	40-60	
PATIENT		1.3	1.2	-	1.06	NM	
Adapted from June Boon, Veterinary Echocardiography, 1998 Sisson D et al. JVIM 1991; 5: 232, Jacobs et al. Am J Vet Res 1985; 46:1705							

**ULTRASONOGRAPHIC FINDINGS**

Compensated hypertrophic cardiomyopathy.  
Mild mitral insufficiency.



**PATIENT**

Sasha Nannis

**SPECIES**

Feline

**BREED**

Domestic Shorthair

**SEX**

Spayed Female

**AGE**

6 years

**WEIGHT**

11.92 lbs

**INTERPRETED BY**

Eric Lindquist, DMV  
DABVP, Cert. IVUS

**IMAGING PERFORMED BY**

Dr. Tenorio

**HOSPITAL NAME**

Wauwautosa VC

**REFERRING VET**

Dr. Haynes

**INVOICE**

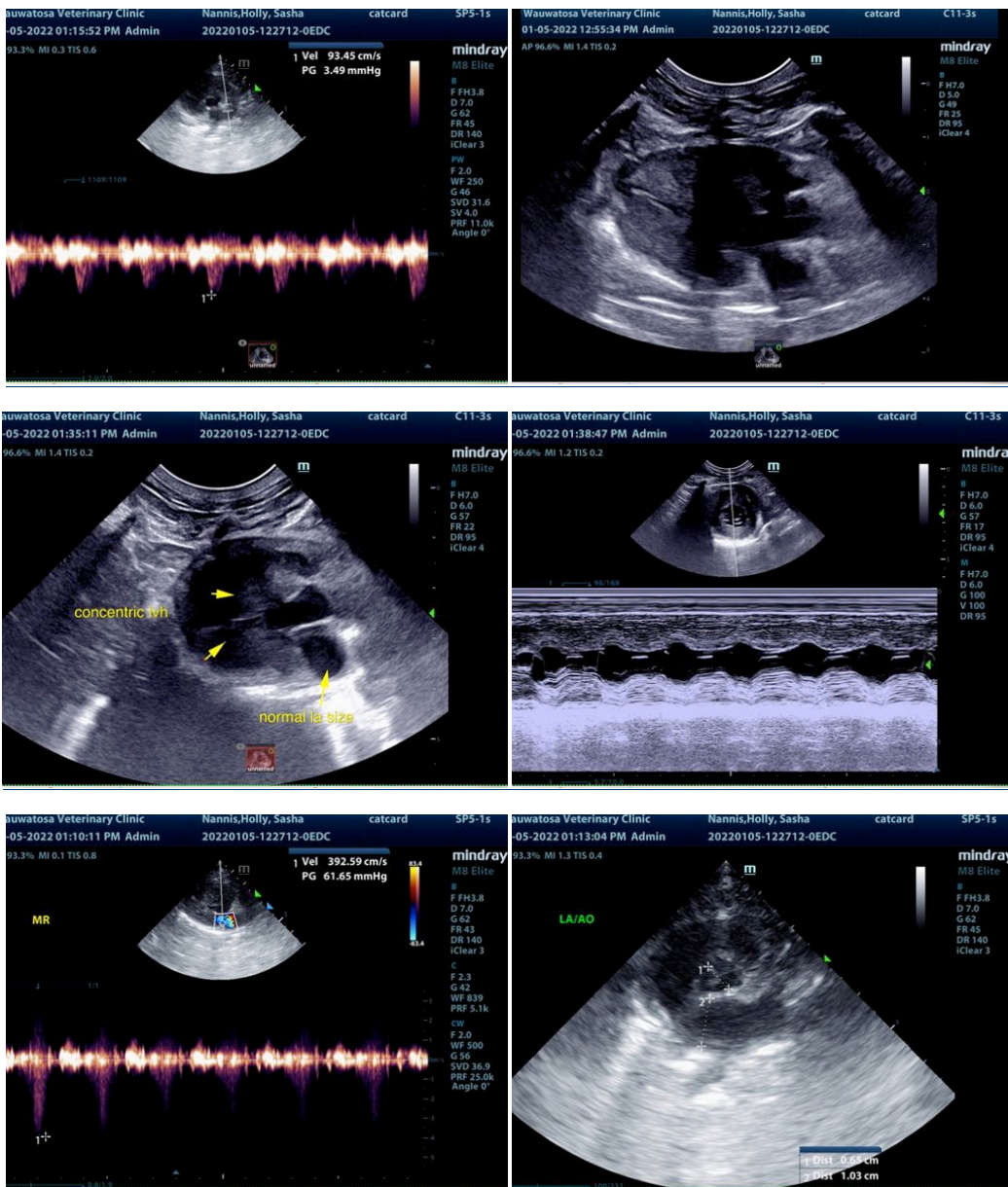
95027

**DATE**

1/5/22

**INTERPRETATION OF THE FINDINGS & FURTHER RECOMMENDATIONS**

A recheck echocardiogram is recommended in 6 months or earlier if murmur grade increases or clinical signs initiate. The changes were fairly mild. There was no evidence of volume overload.





**PATIENT**

Sasha Nannis

**SPECIES**

Feline

**BREED**

Domestic Shorthair

**SEX**

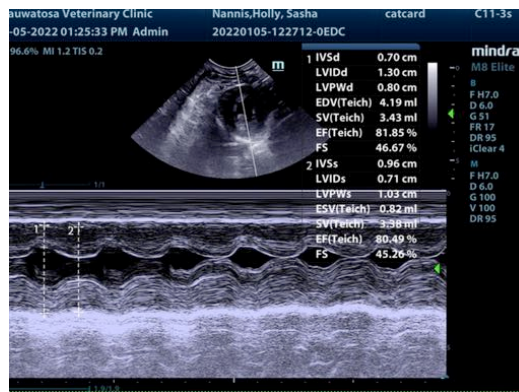
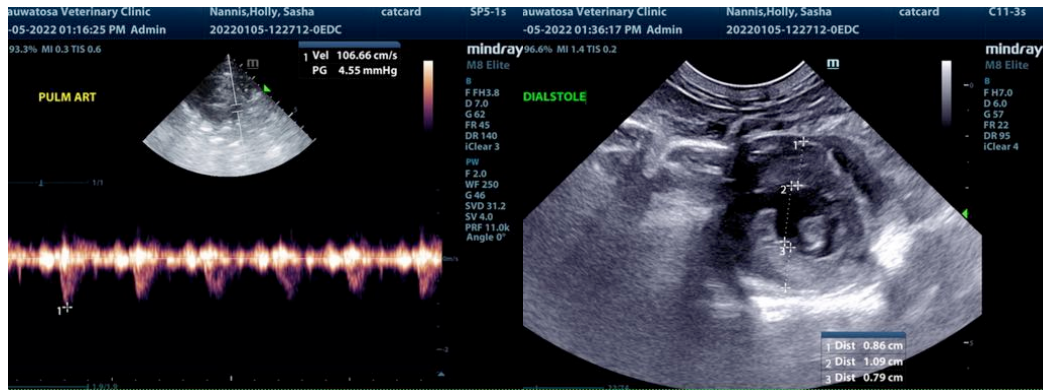
Spayed Female

**AGE**

6 years

**WEIGHT**

11.92 lbs



**INTERPRETED BY**

Eric Lindquist, DMV  
DABVP, Cert. IVUSS

The information and recommendations provided are based on the images presented by the referring veterinarian. No evaluation can be communicated regarding pathology that was not visible in the image/video clips provided.

**IMAGING PERFORMED BY**

Dr. Tenorio

Thank you for this referral. If the clinical or image interpretation does not parallel your findings or if I can be of any further assistance please contact me.

**HOSPITAL NAME**

Wauwautosa VC

Eric Lindquist, DMV, DABVP, Cert. IVUSS, CEO of SonoPath.com  
info@SonoPath.com

**REFERRING VET**

Dr. Haynes

**INVOICE**

95027

**DATE**

1/5/22