

## PATIENT PRESENTING CLINICAL SIGNS

Daisy McNamara Presented at another (rural) clinic for dyspnea, cough, (losing clumps of hair) Is the fluid and cardiac murmur related to cardiac disease, neoplasia, or infection such as feline corona virus?

## SPECIES ULTRASONOGRAPHIC EXAMINATION OF THE HEART

Feline

BREED

DSH

SEX

Spayed Female

AGE

6 Years

WEIGHT

8 Pounds

FELINE CARDIAC PARAMETERS	BODY WEIGHT (kg)	HR (BPM)	IVSd (cm)	LVIDd (cm)	LVWd (cm)	FS (%)	EF (%)
NORMAL PARAMETER	-----	150-240	0.3-0.6	1.0-2.1	0.25-0.6	35-67	80-100
PATIENT		199	0.65	0.78	0.59	47	83
FELINE CARDIAC PARAMETERS	LA/AO (Boon)	LA/AO HEART BASE (Sisson)	LA 2D 4-chamber long axis AS to FW (Sisson) (cm)		LVOT VEL. (m/s)	RVOT VEL. (m/s)	IVRT (m/)
NORMAL PARAMETER	<1.5	0.88-1.79	0.7-1.7		<1.6	<1.3	40-60
PATIENT	1.4	1.5	1.2		1.0	0.9	NM

Adapted from June Boon, Veterinary Echocardiography, 1998  
Sisson D et al. JVIM 1991; 5: 232, Jacobs et al. Am J Vet Res 1985; 46:1705

### Cardiac Presentation

The echocardiogram in this patient demonstrated normal **left atrial** size based on 3 separate LA measurements. Mitral insufficiency noted on color flow and spectral doppler. The **left ventricular** internal volume was subnormal. Minor hypertrophy or pseudohypertrophy of the left ventricle present. The **myocardium** presented normal echogenicity without subjective evidence of significant fibrotic or ischemic disease. **Contractility** of the ventricular walls was adequate and in normal range for this patient evidenced by the fractional shortening measurement and subjective evaluation of the different regions and angles of the myocardium. The **left ventricular outflow** tract demonstrated normal laminar flow and subjective structural integrity. The **right atrium** and auricle revealed normal size, structure and content. No evidence of masses was noted or chamber overload. **Tricuspid** valvular assessment demonstrated adequate linear morphology and kinetics. The **right ventricle** was of normal size (1/3 diameter of LV), chordae structure, myocardial echogenicity and thickness. **Pulmonic** tract assessment revealed normal valve structure, laminar flow, and diameter (approx. 1:1 pa/ao ratio). Non-cardiogenic pleural effusion noted with comet tail or B-lines throughout the lung fields. Trace pericardial effusion noted. Variable areas of lung consolidation noted.

### ULTRASONOGRAPHIC FINDINGS

- Left ventricular hypertrophy, compensated, possible pseudohypertrophy
- Non-cardiogenic pleural effusion – Causes include thoracic neoplasia, possibly metastatic from the abdomen, FIP, lung lobe torsion or other primary lung pathology.

### INTERPRETED BY

Eric Lindquist, DMV,  
DABVP, Cert. IVUSS

### IMAGING PERFORMED BY

Jenna Walsh, CVT

### HOSPITAL NAME

South Willamette VC

### REFERRING VET

Dr. Willaman

### DATE

1/5/22

### INVOICE

33977



**PATIENT**

Daisy McNamara

**SPECIES**

Feline

**BREED**

DSH

**SEX**

Spayed Female

**AGE**

6 Years

**WEIGHT**

8 Pounds

**INTERPRETED BY**

Eric Lindquist, DMV,  
DABVP, Cert. IVUSS

**IMAGING PERFORMED BY**

Jenna Walsh, CVT

**HOSPITAL NAME**

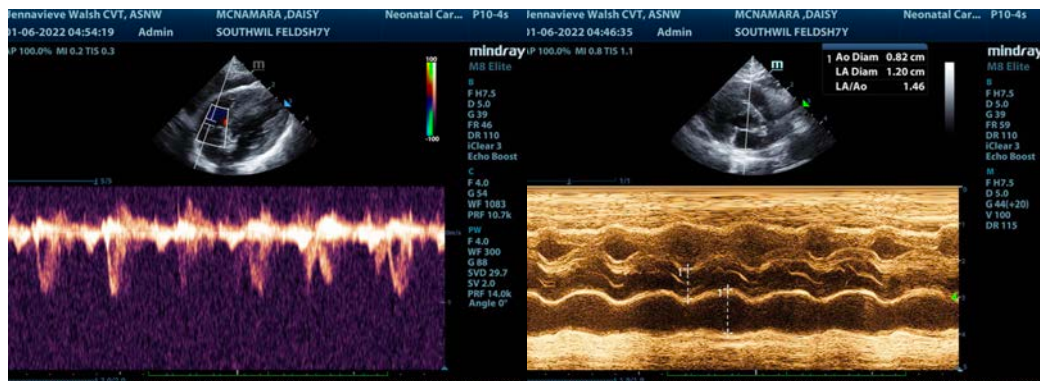
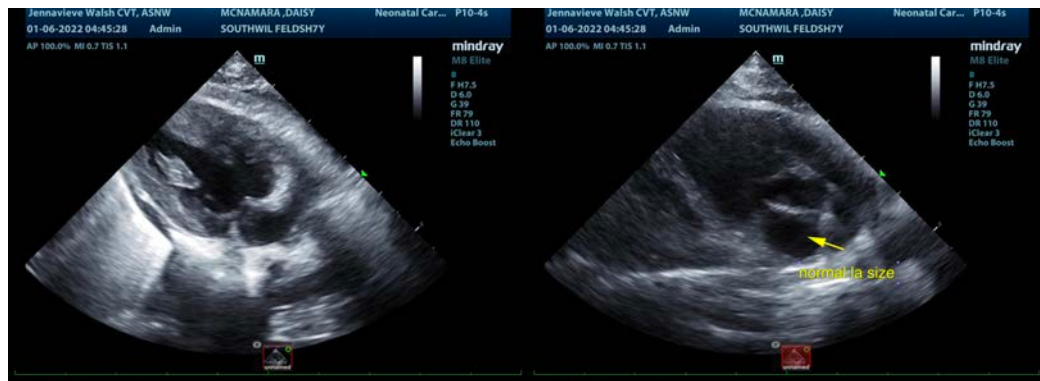
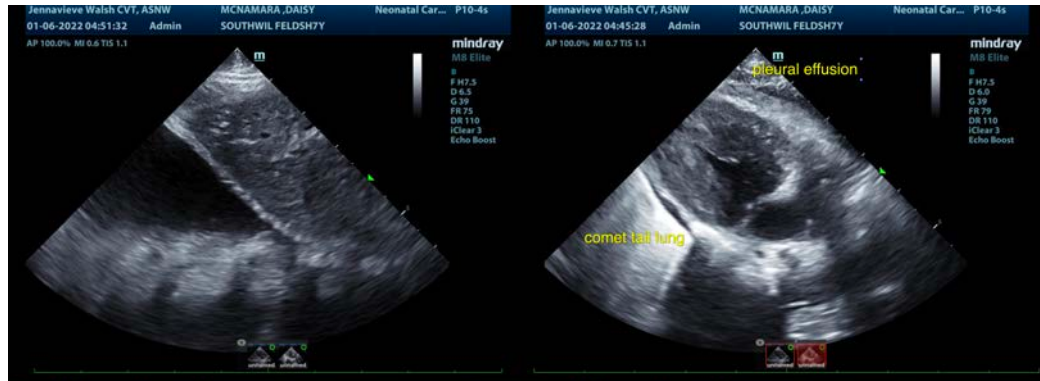
South Willamette VC

**REFERRING VET**

Dr. Willaman

**INTERPRETATION OF THE FINDINGS & FURTHER RECOMMENDATIONS**

Recommend pleurocentesis and cytospin of the free fluid as well as abdominal sonogram to assess for primary disease. The heart is not the clinical issue in this patient, even though mitral insufficiency was present. The left atrial size is normal, and therefore the pleural effusion is not cardiogenic in nature.



**DATE**

1/5/22

**INVOICE**

33977



**PATIENT**

Daisy McNamara

**SPECIES**

Feline

**BREED**

DSH

**SEX**

Spayed Female

**AGE**

6 Years

**WEIGHT**

8 Pounds

**INTERPRETED BY**

Eric Lindquist, DMV,  
DABVP, Cert. IVUSS

**IMAGING PERFORMED BY**

Jenna Walsh, CVT

**HOSPITAL NAME**

South Willamette VC

**REFERRING VET**

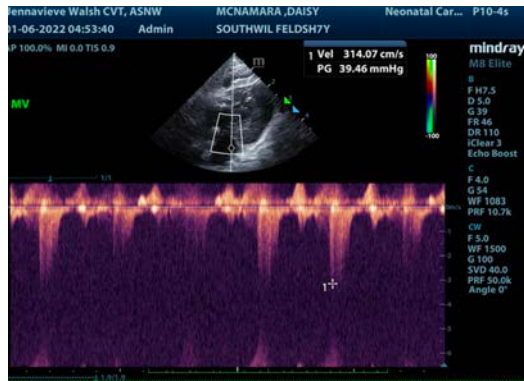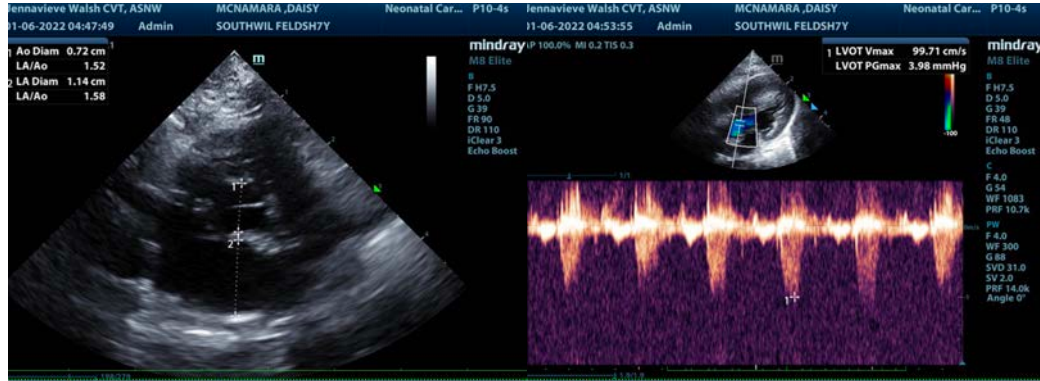
Dr. Willaman

**DATE**

1/5/22

**INVOICE**

33977



The information and recommendations provided are based on the images presented by the referring veterinarian. No evaluation can be communicated regarding pathology that was not visible in the image/video clips provided.

Thank you for this referral. If the clinical or image interpretation does not parallel your findings or if I can be of any further assistance please contact me.

Eric Lindquist, DMV, DABVP, Cert. IVUSS

CEO of Sonopath.com

Eric.Lindquist@SonoPath.com